



GENITOURINARY SYSTEM

SUBJECT : Anatomy

LEC NO. : 5

DONE BY : Batool Alzubaidi & Hashem Ata

وَقُلْ رَبِّ زِدْنِي عِلْمًا



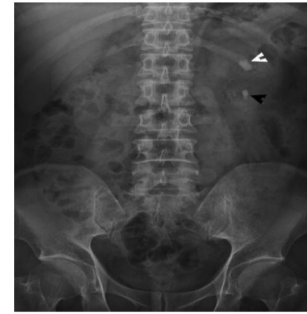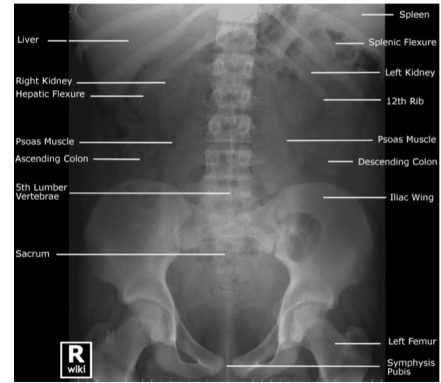
GENITOURINARY SYSTEM

✿ اول اشى حابين نحكي لكم شغلة بناءً على اسئلة كثير
اجتتا هل التفريغ شامل الوجاهي او الاون التفريغ
شامل التتين كل واحد فينا بشيك من جهة ف التفريغ
شاملة كل اشى ان شاء الله ✿

Radiographic Appearances of the Urinary Tract

Kidneys:

- The kidneys are visible on a standard anteroposterior radiograph of the abdomen (Plain X-Ray) because the perirenal fat surrounding the kidneys produces a transradiant line. Density of kidney is lesser than density of perineal fat that's what makes fat appear as lining of kidney
- Gives us quick diagnosis of renal colic (used in emergency department).
- Good evaluation of radio-opaque stones.



هاي السلايدة الاولى من محاضرة ٤ عدلوا بس انه ال density of the kidney is more than density of perineal fat

وَقُلْ رَبِّ زِدْنِي عِلْمًا

GUS..



Lecture (5)

Anatomy of Perineum

Dr. Amany Allam

Assistant professor of Anatomy & Embryology

ILOs

- 1. Understand the gross anatomy of perineum.**
- 2. Describe the urogenital and anal triangle.**
- 3. Understand the urogenital diaphragm, superficial & deep perineal pouches and their contents in both sexes.**

Perineum

- It is the diamond-shaped lower end of the trunk.
- It lies below the pelvic diaphragm, between the upper parts of the thighs.

Below levator ani

- **Boundaries:** As boundaries of the pelvic outlet.

مرفقين على الصورة

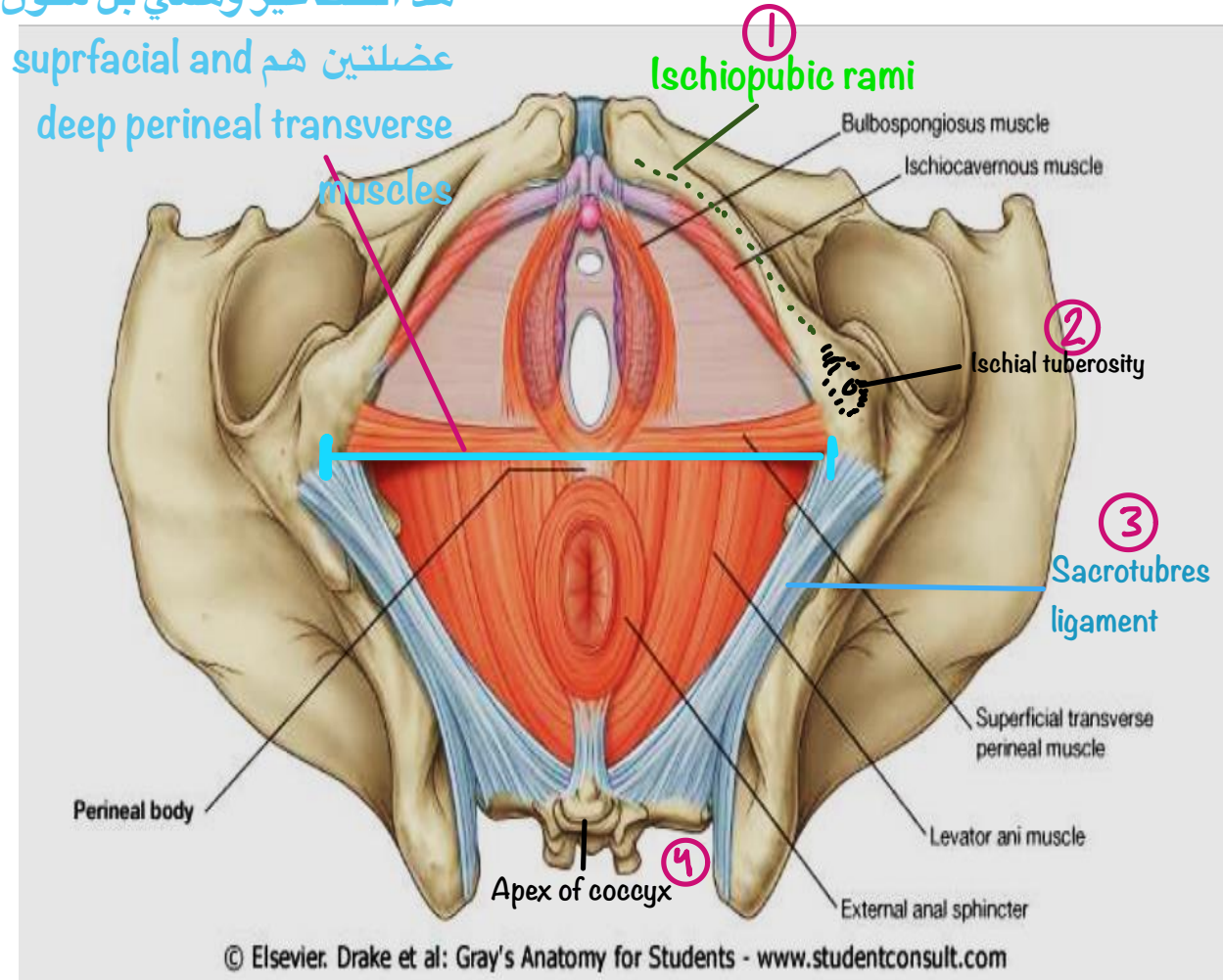
- **Division of perineum:**

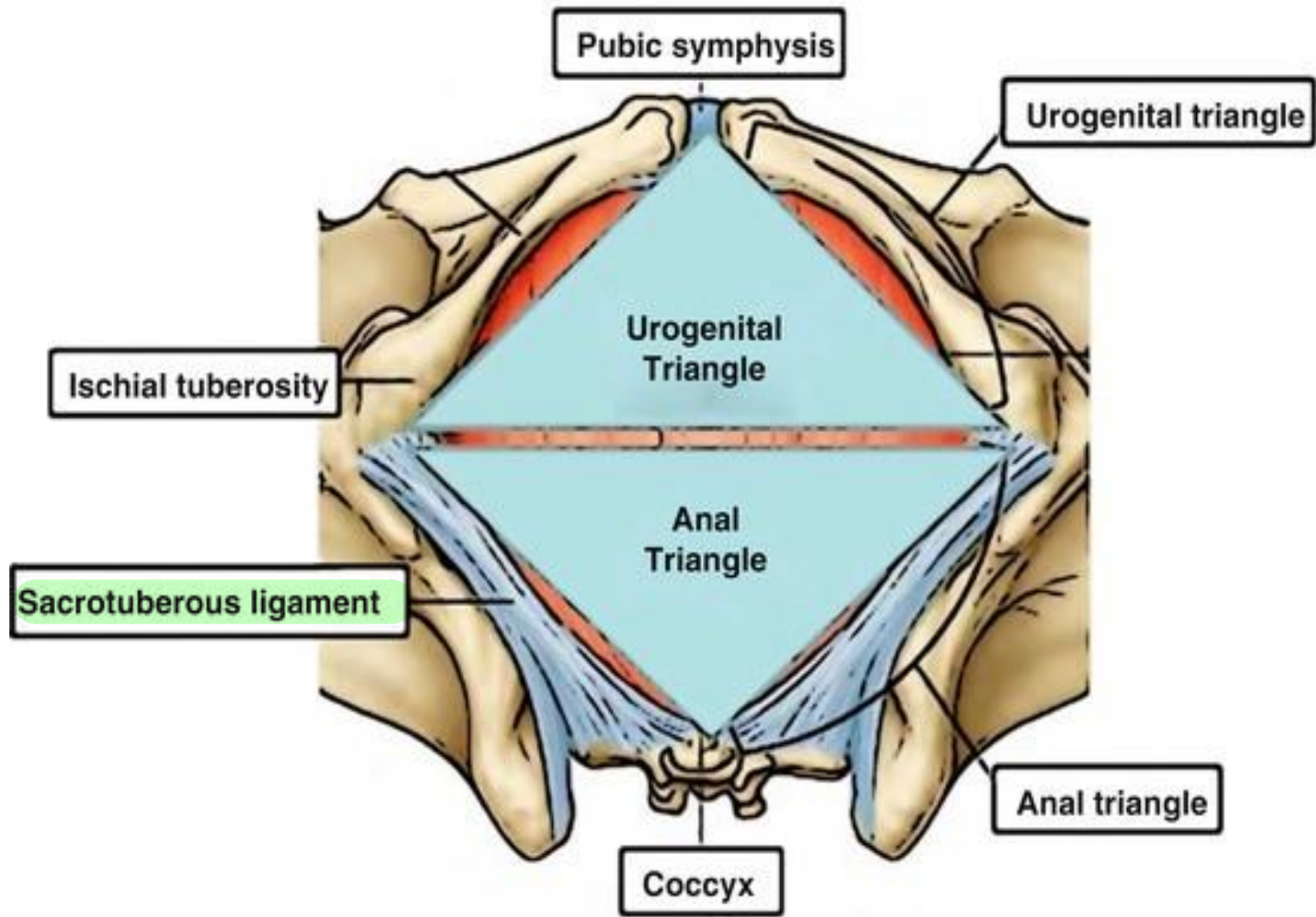
Interischial line

By a line joining the ischial tuberosities, the perineum is divided into two triangles:

- Anteriorly: **Urogenital triangle.**
- Posteriorly: **Anal triangle.**

هذا الخط غير وهمي بل مكون من عضلتين هم عضلتان عميقة





Anal Triangle

The anal triangle contains:

- The **anal canal** and its **sphincters**.

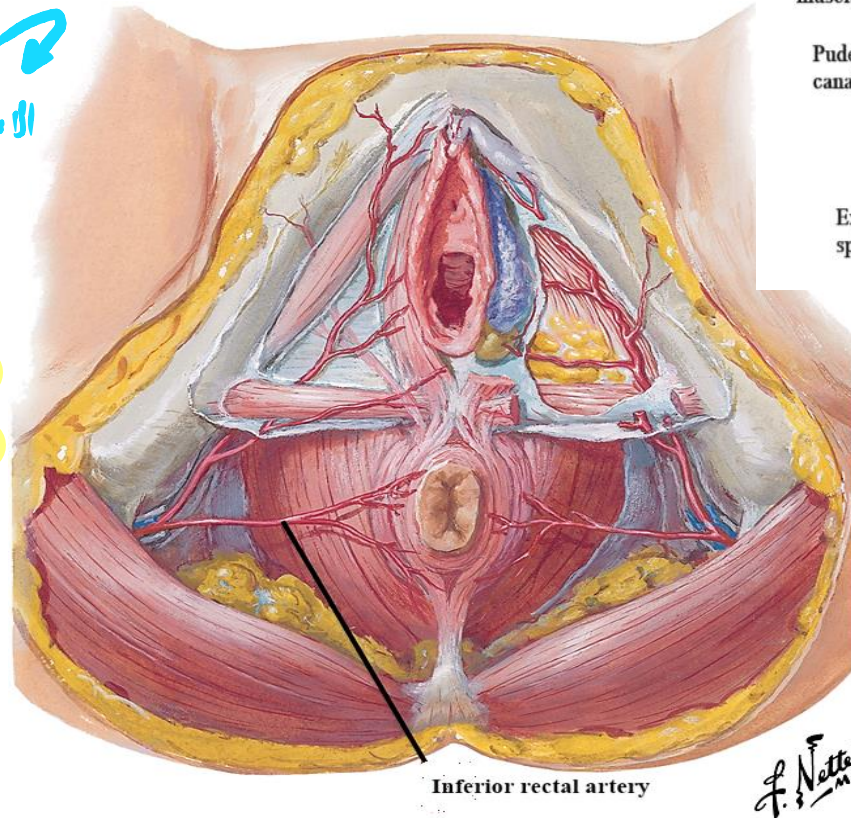
↗ Right and left

- The **two ischio-anal (ischio-rectal) fossae**.

الاسم الصحيح ↗

الاسم المثلث ↗

- The **structure of the anal triangle is similar** in males and females.



Land mark ↗

Levator ani muscle

Obturator internus muscle

Pudendal canal

Ischiorectal fossa

Anal canal

Ischiorectal fossa

External iliac sphincter

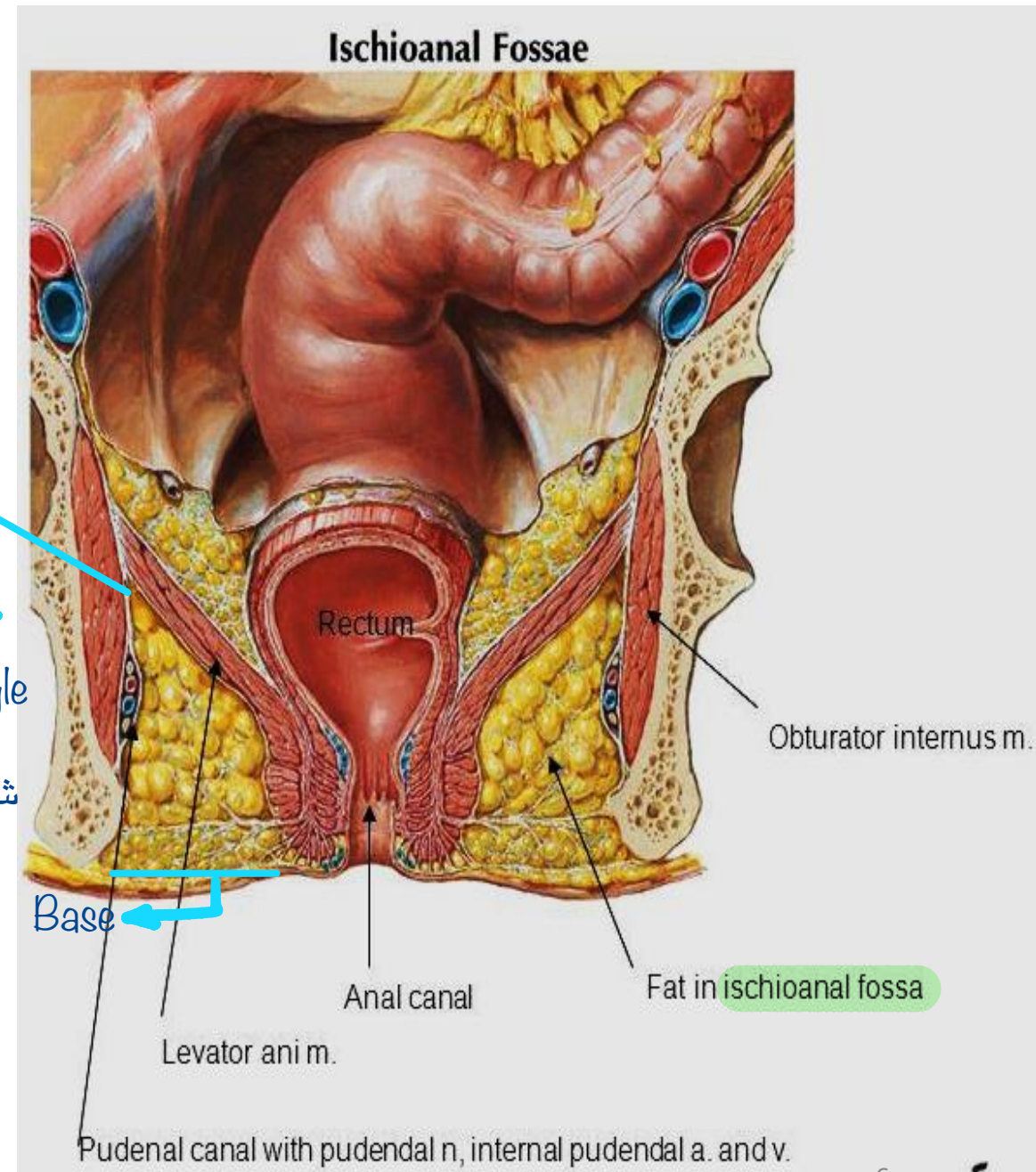
* Coronal section in the posterior triangle of perineum : —

Ischioanal fossa:

It is wedge shaped space on either side of the anal canal. ↳ Pyramidal

Its boundaries are formed by as follow:

- ↳ Line not a point
- **Apex:** Origin of levator ani from tendinous arch. ↳ Directed downward
- **Base:** Skin on either side of the anal orifice.
- **Anteriorly:** Posterior borders of the superficial and deep transverse perineal muscles. ↳ Muscles in urogenital triangle
- **Posteriorly:** Sacrotuberous ligament. ↳ شوفوا الرسمة بسلايد ٤
- **Lateral wall:** Obturator internus muscle & fascia and pudendal canal.
- **Superomedial wall:** Levator ani muscle & external anal sphincter.



Contents of Ischio-anal fossa:

1. Ischioanal fat (allows distention of the anal canal during defecation)

2. Pudendal canal on its lateral wall that transmits the **pudendal nerve and internal pudendal vessels.**

3. Inferior rectal nerve & vessels.

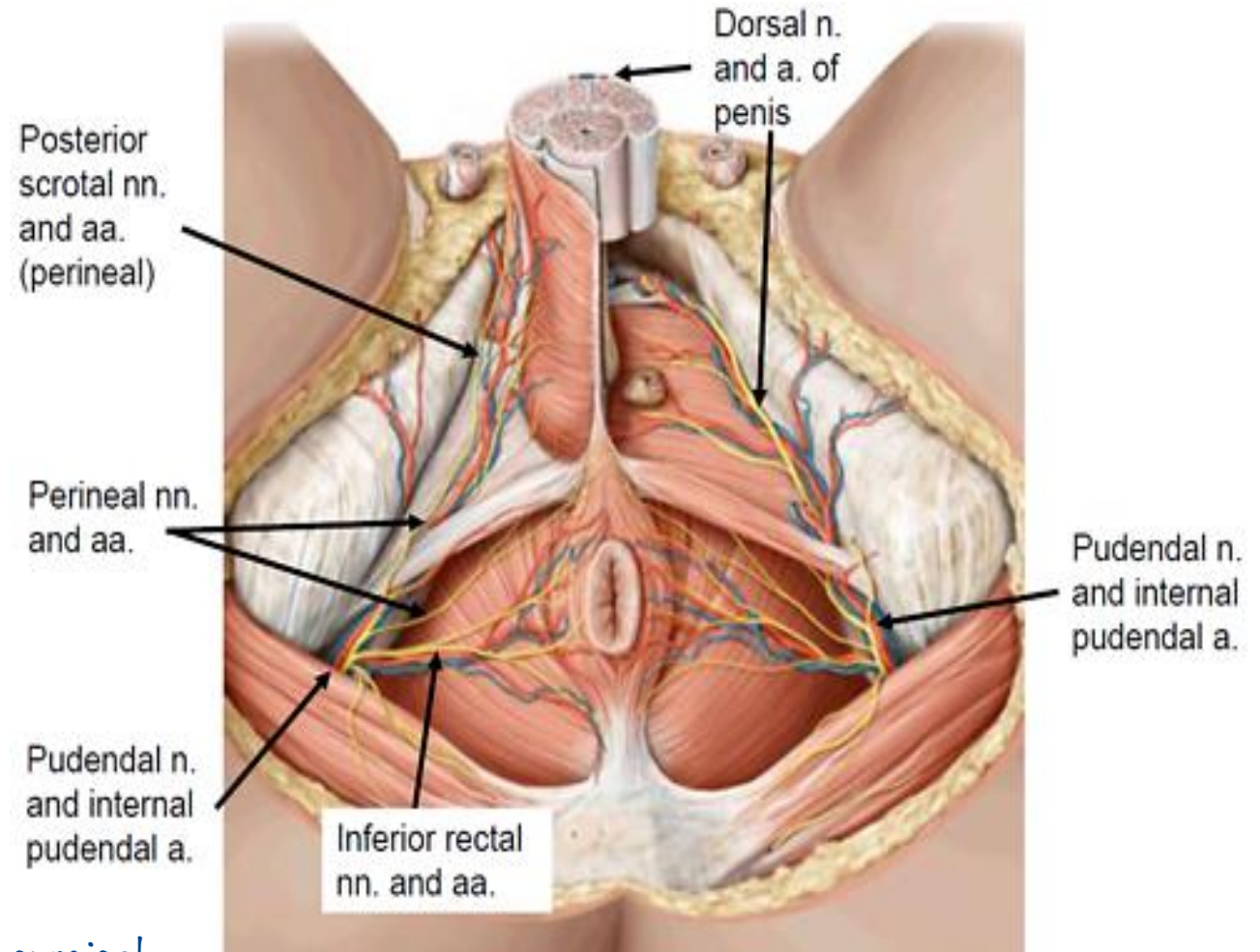
↳ Supply anal canal and its sphincter

Applied Anatomy:

Infections in the ischioanal fat is common and lead to abscess formation.

The abscess may rupture medially into the anal canal or downwards into the skin at the fossa.

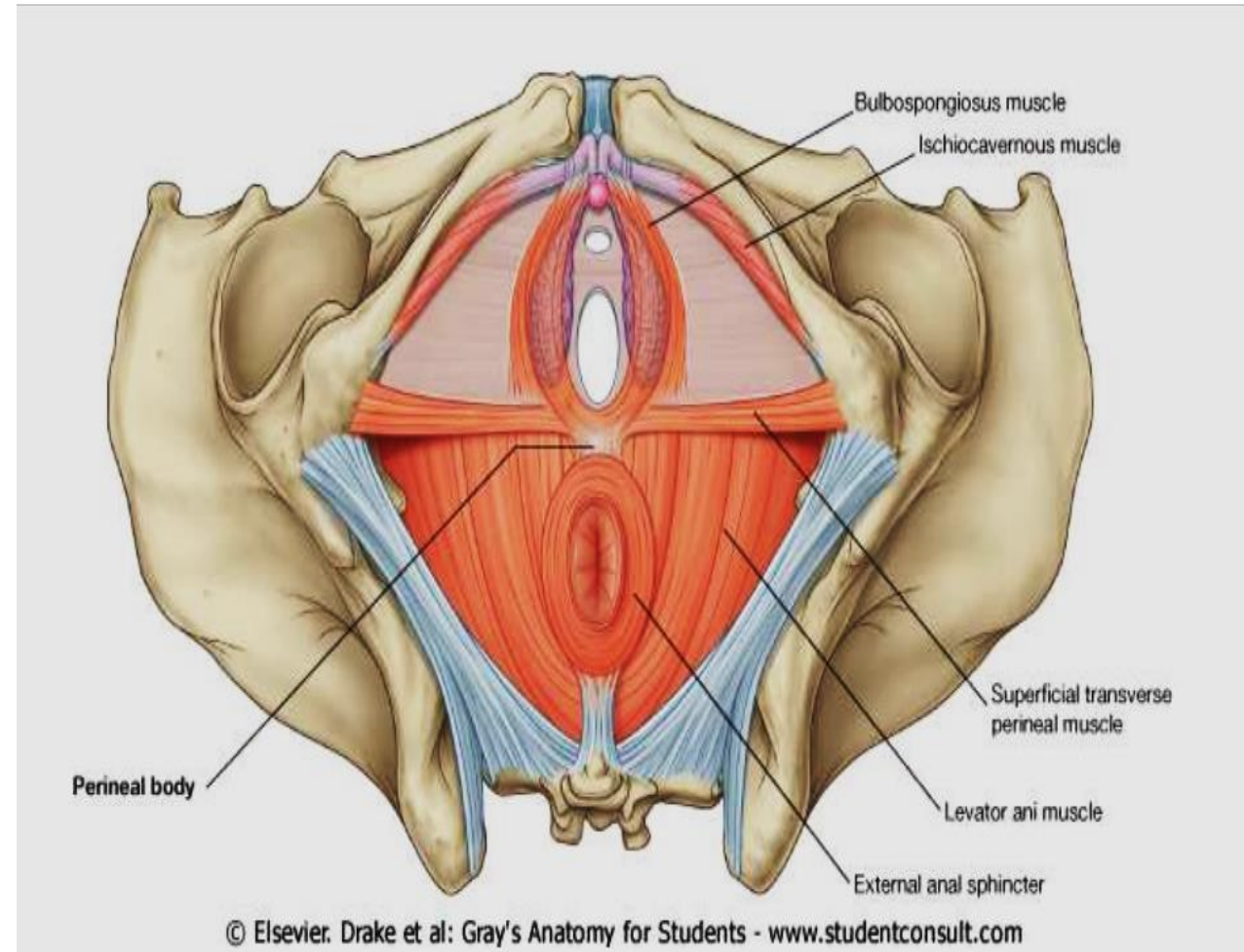
↳ Leads into formation of anal fistula, treatment is surgical



Urogenital Triangle

Boundaries:

- **Posteriorly:** Inter-ischial line.
- **Anteriorly and laterally:** Symphysis pubis and ischiopubic rami.



Anatomical division

The urogenital triangle is divided into two

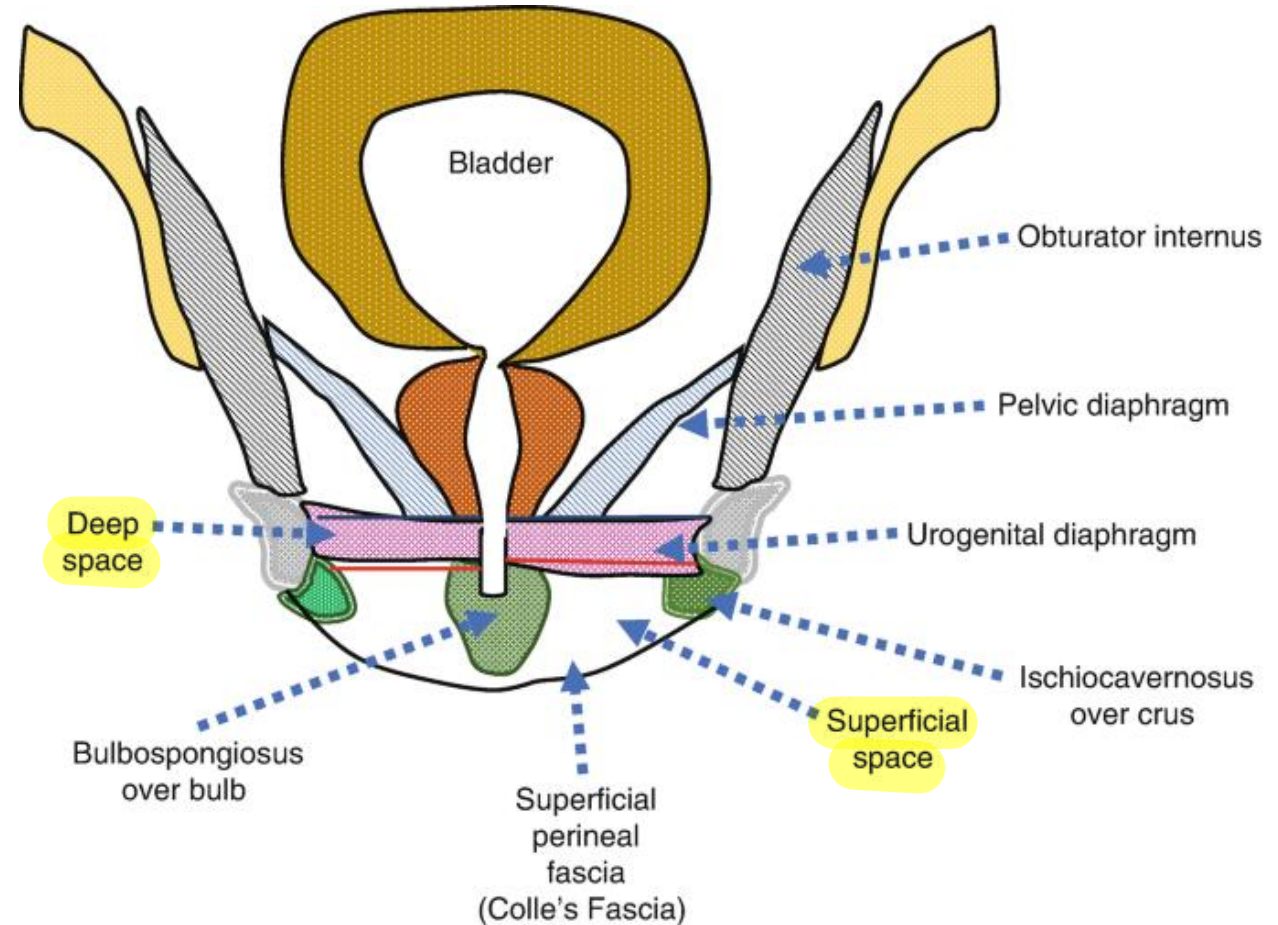
spaces by a strong perineal membrane:

1- Deep perineal space (pouch): lies above the perineal membrane.

2- Superficial perineal space (pouch): lies below the perineal membrane.

Superficial » closer to skin

Coronal section anteriorly



Pudendal Nerve

It arises from the sacral plexus.

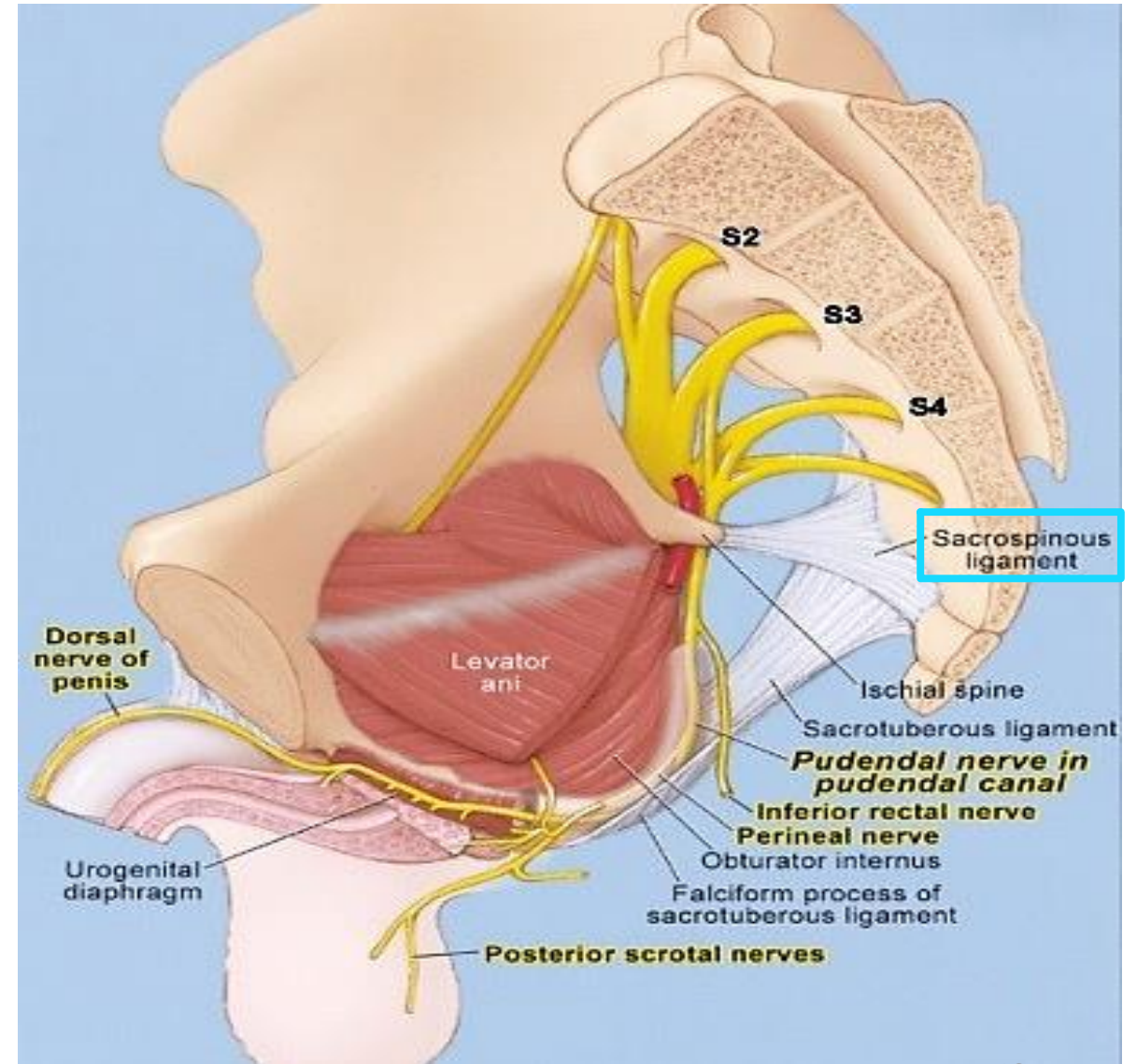
Course and Relations:

It leaves the pelvis through the greater sciatic foramen.

Then it crosses the sacrospinous ligament.

It passes through the lesser sciatic foramen to enter the pudendal canal.

بيدخل فيها و ينتهي فيها يعني ال
terminal branches تاعته فيها



Branches of pudendal nerve:

- **Inferior rectal nerve.** → In ischioanal fossa
↳ .Not related to either pouches of urogenital triangle

- **Terminal branches;**

راح يعمل traverse لل perineal

membrane و يعمل supply لل

superficial و حتى هو بال deep

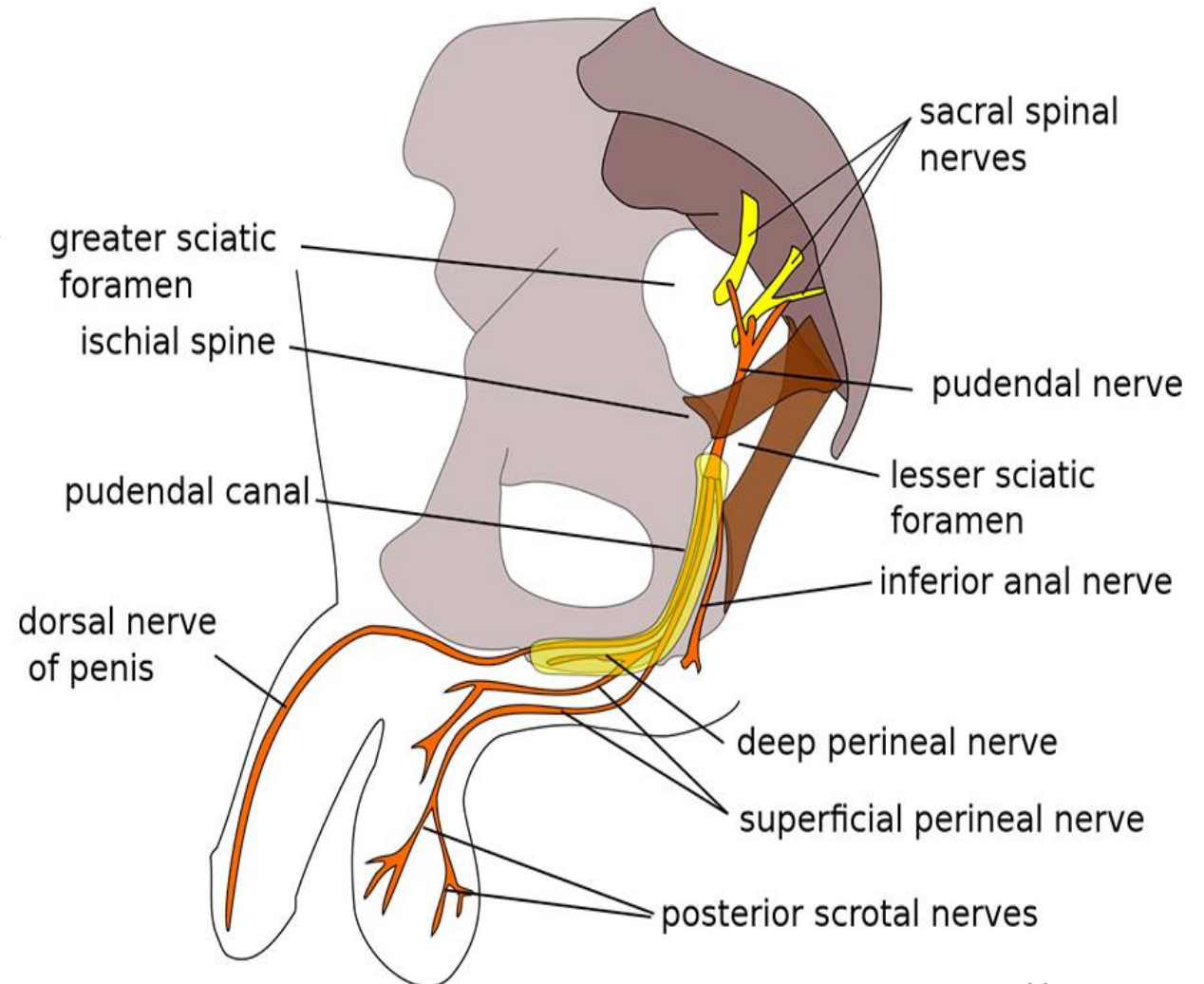
طلع منه و هو بال canal

- **a) Perineal nerve.**

- **Motor:** To **muscles of the superficial and deep perineal pouches.**

- **Sensory:** Posterior scrotal (labial) nerves.

- **b) Dorsal nerve of penis (or clitoris).**

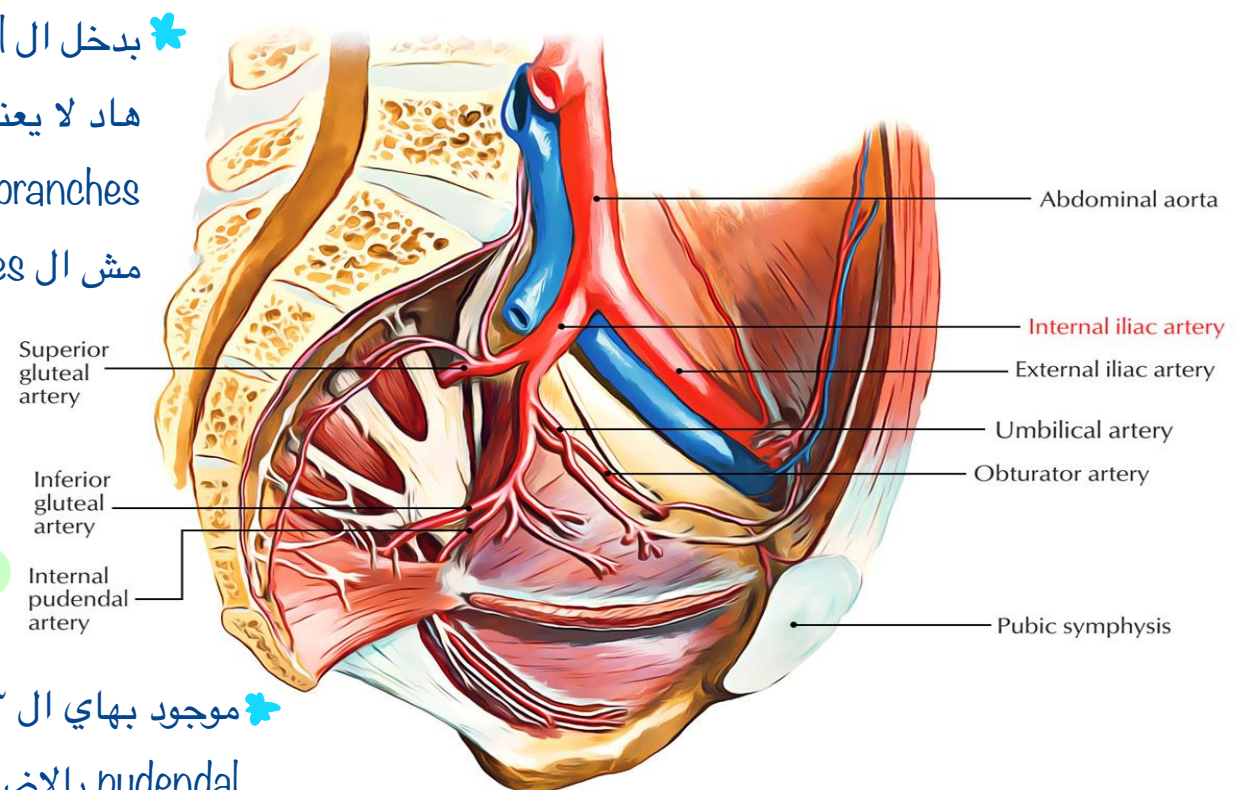


Internal Pudendal Artery

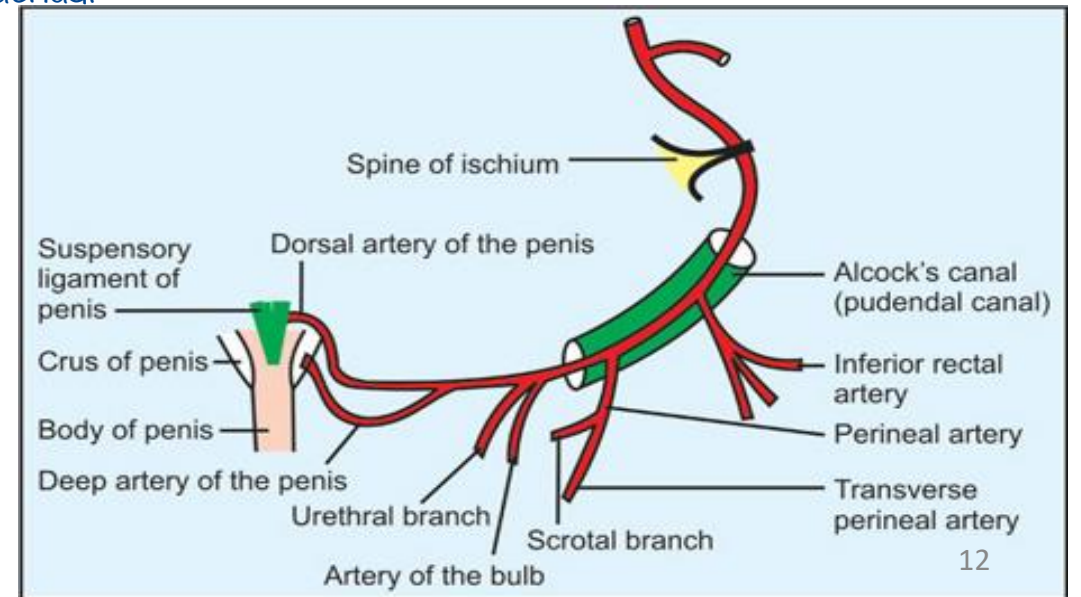
✳ بدخل ال canal و بطلع منها بس
هاد لا يعني انه ما اعطى
branches جوة ال canal بس
مش ال terminal branches

Course and Relations:

- It leaves the pelvis through the greater sciatic foramen.
- Then it crosses ischial spine and passes through the lesser sciatic foramen to pass through the pudendal canal.
- Then it enters the deep perineal pouch then pierces the perineal membrane & enters superficial perineal pouch.
- It ends by dividing into dorsal and deep arteries of the penis.



✳ موجود بهاي ال ٣ مناطق على شكل internal
pudendal بالاضافة لل branches الي يعطيها.



Branches of Internal Pudendal Artery:

In Pudendal canal:

- 1- Inferior rectal artery. Anal triangle
- 2- Perineal artery: it gives
 - Two scrotal (or labial) arteries.
 - ~~Two scrotal (or labial) arteries.~~

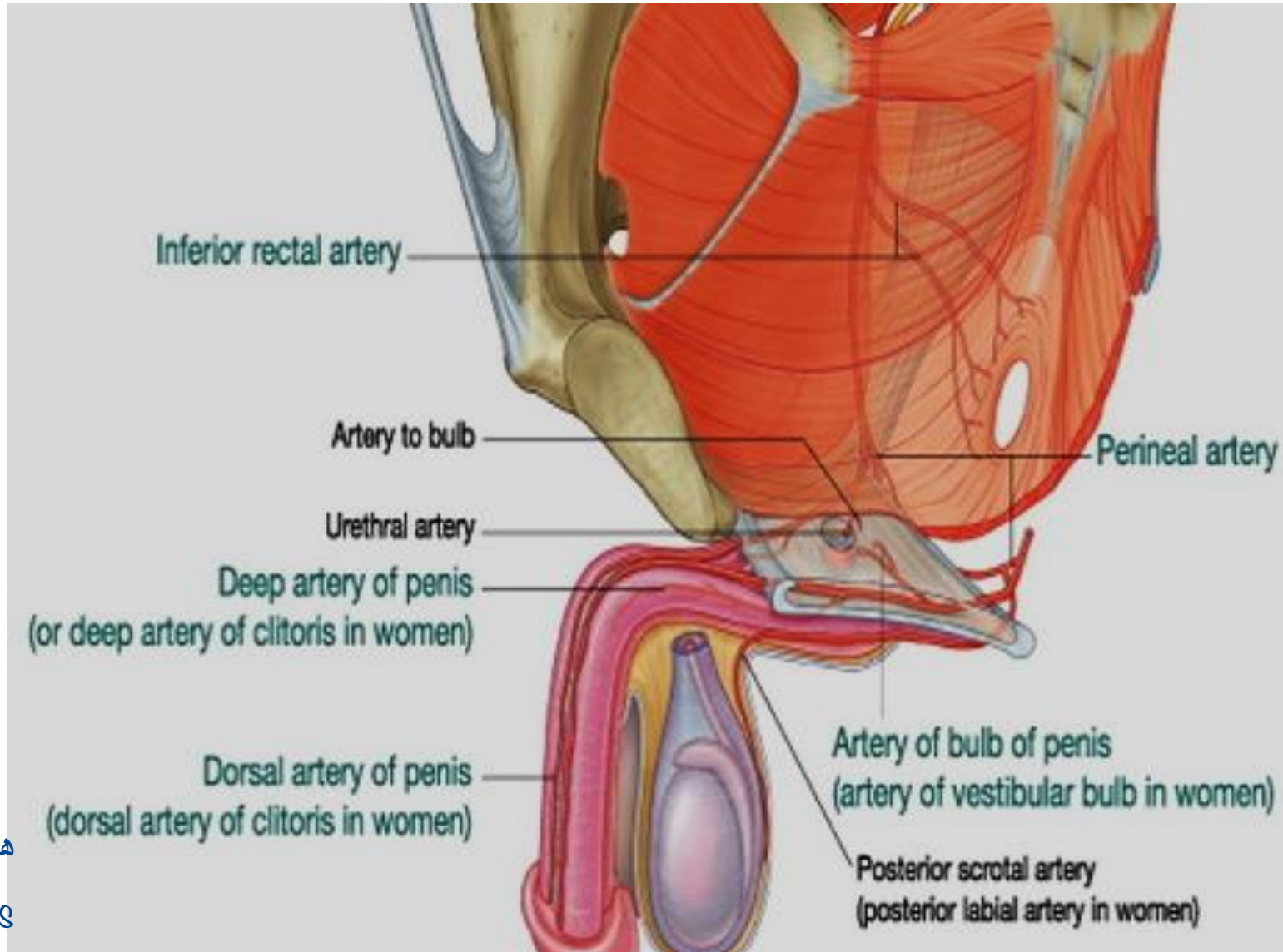
In Deep perineal pouch:

- 3- Artery of bulb.
- 4- Urethral artery.

In Superficial perineal pouch:

- 5- Dorsal A. of penis. هون بيعطي ال terminal
- 6- Deep A. of penis. branches و بينتهي

↪ اذا كانت female حطوا clitoris بدل penis



Deep Perineal Space-Urogenital Diaphragm

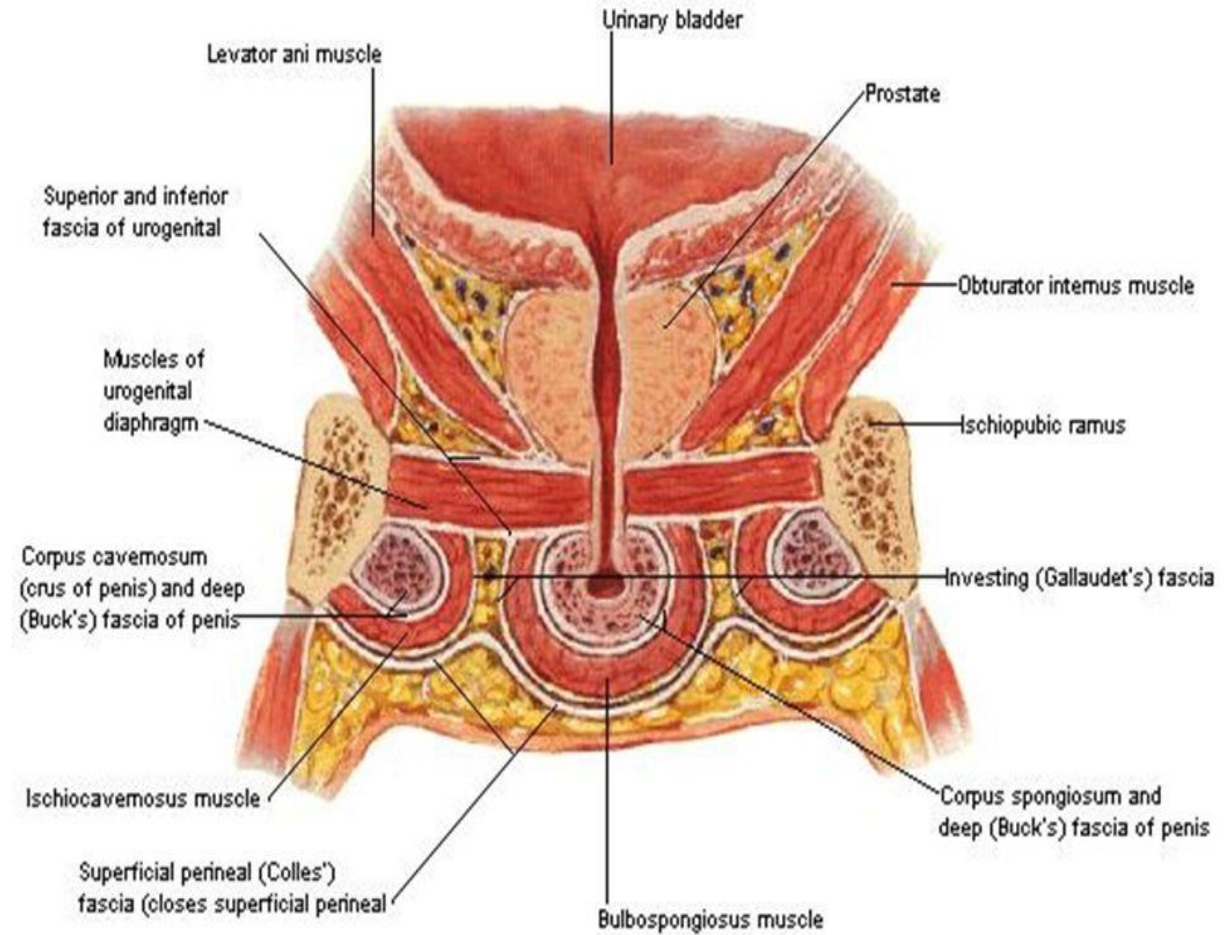
Lies between;

المكون الاساسي عضلتين بتغطيتهم fascia وحدة superior و وحدة inferior و ال inferior هي ال perineal membrane

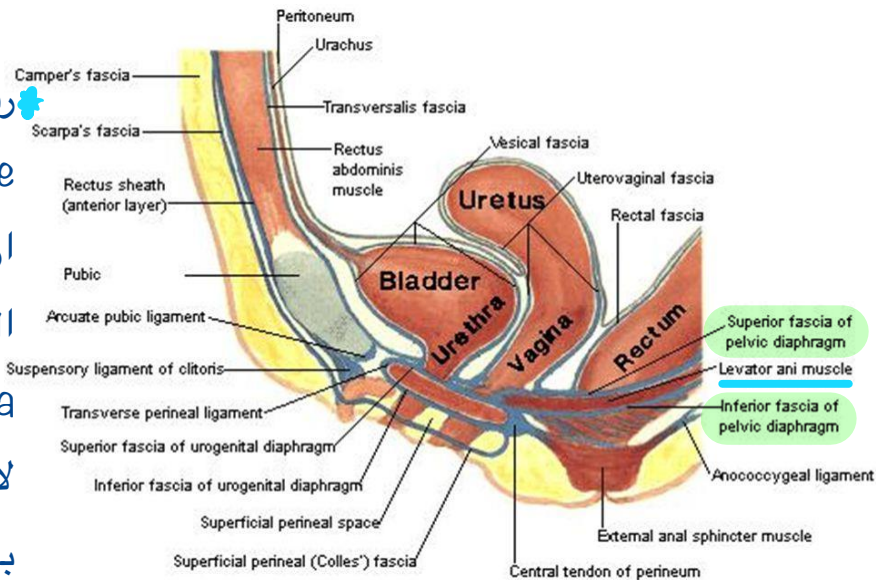
Roof: Superior fascia of the urogenital diaphragm.

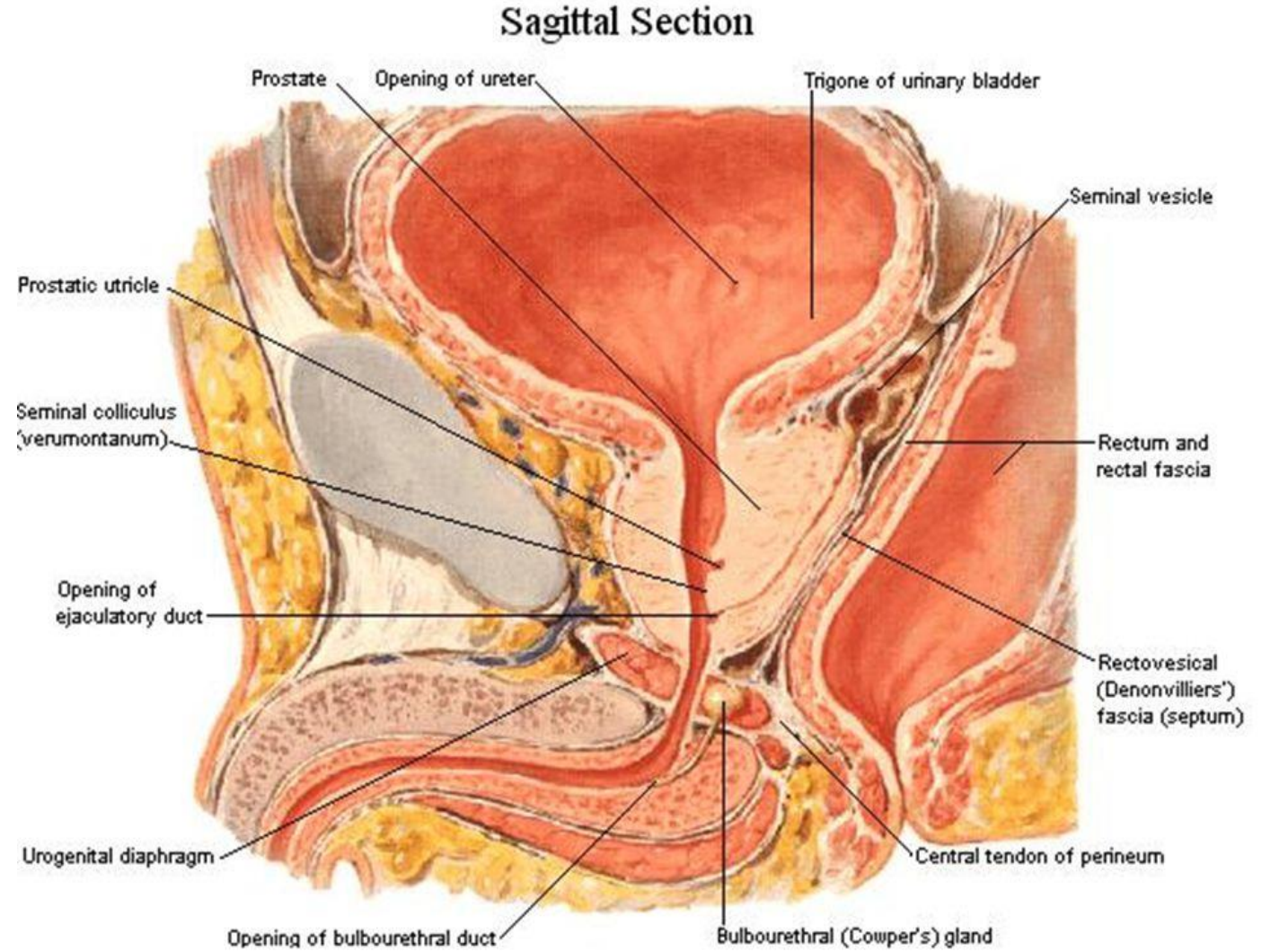
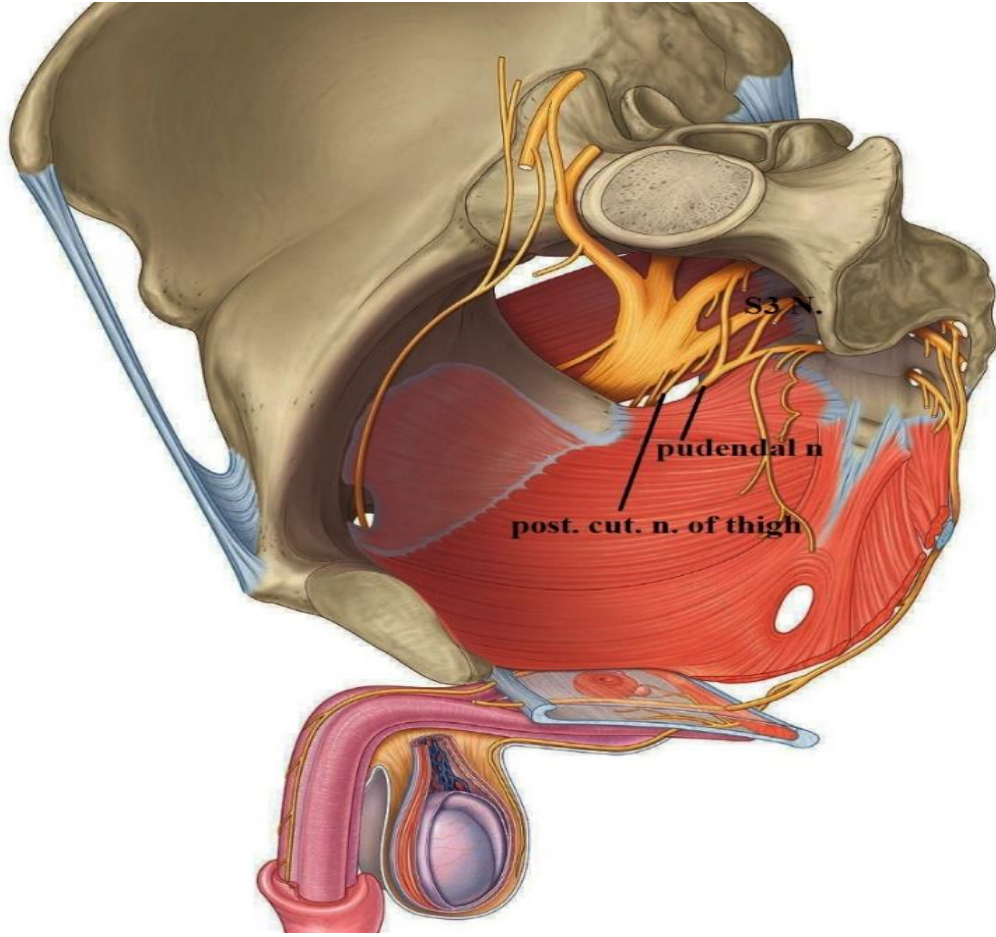
Floor: Inferior fascia of the urogenital diaphragm
(Perineal membrane)

Anteriorly & Posteriorly: it is closed by union of roof and floor.



رسمه sagittal ل female, بنشوف خط ازرق من فوق و تحت الهم superior and inferior fascia و لاحظوا كيف بالآخر بعملوا union





Contents of Deep Perineal Pouch:

- 1- Muscles.
- 2- Urogenital Structures according to sex.
- 3- Branches of the internal pudendal vessels and pudendal nerve.

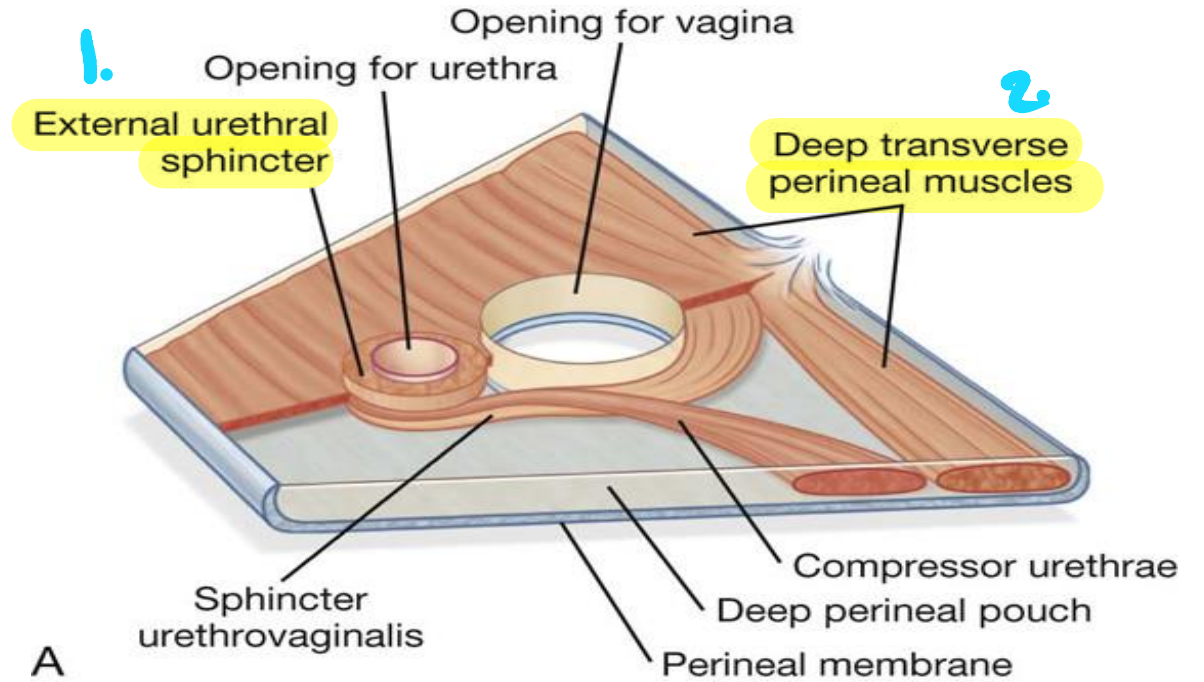
→ Same in males in female

Muscles of the deep perineal pouch:

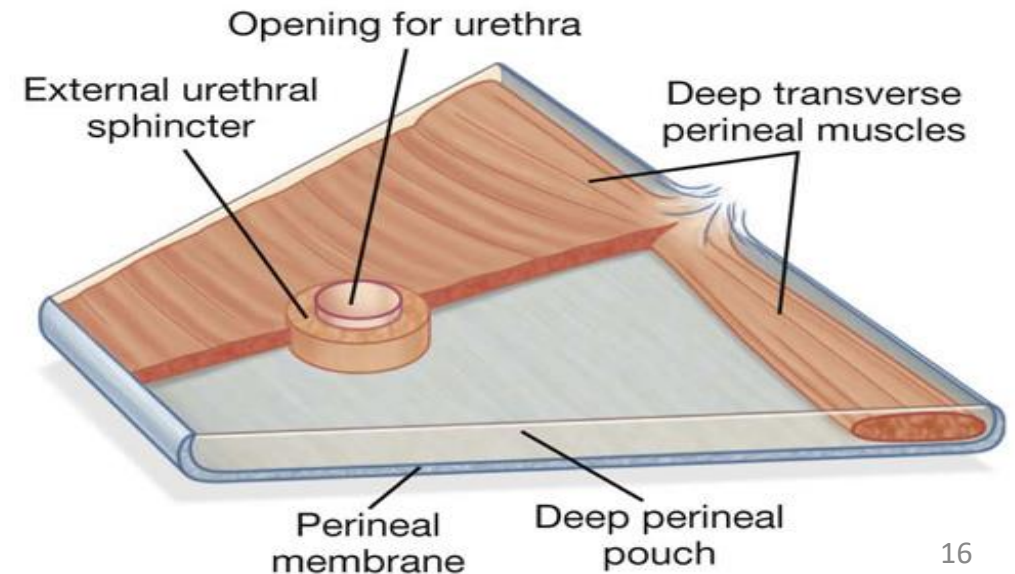
- 1- **Sphincter urethrae.** → External urethral sphincter
- 2- **Deep transverse perineal muscles** (Inserts into perineal body)

- These muscles form the urogenital diaphragm
- They are innervated by the perineal branches of the pudendal nerve.

↙ Motor fibers of pudendal nerve



A

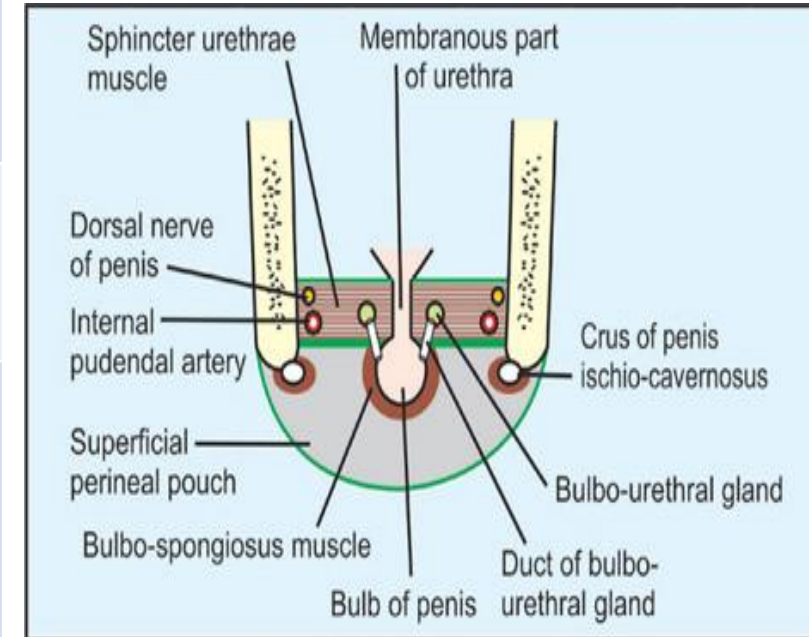


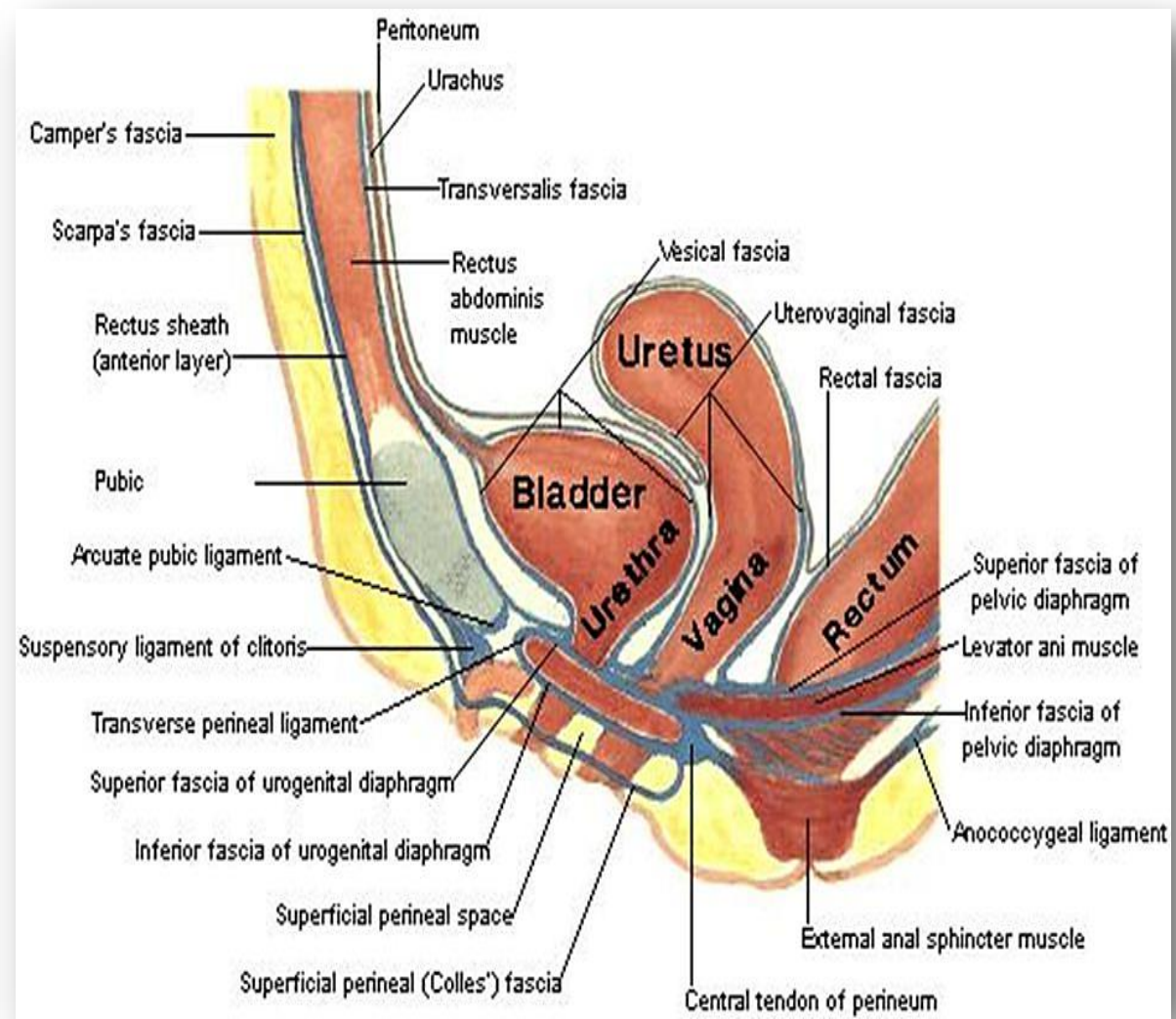
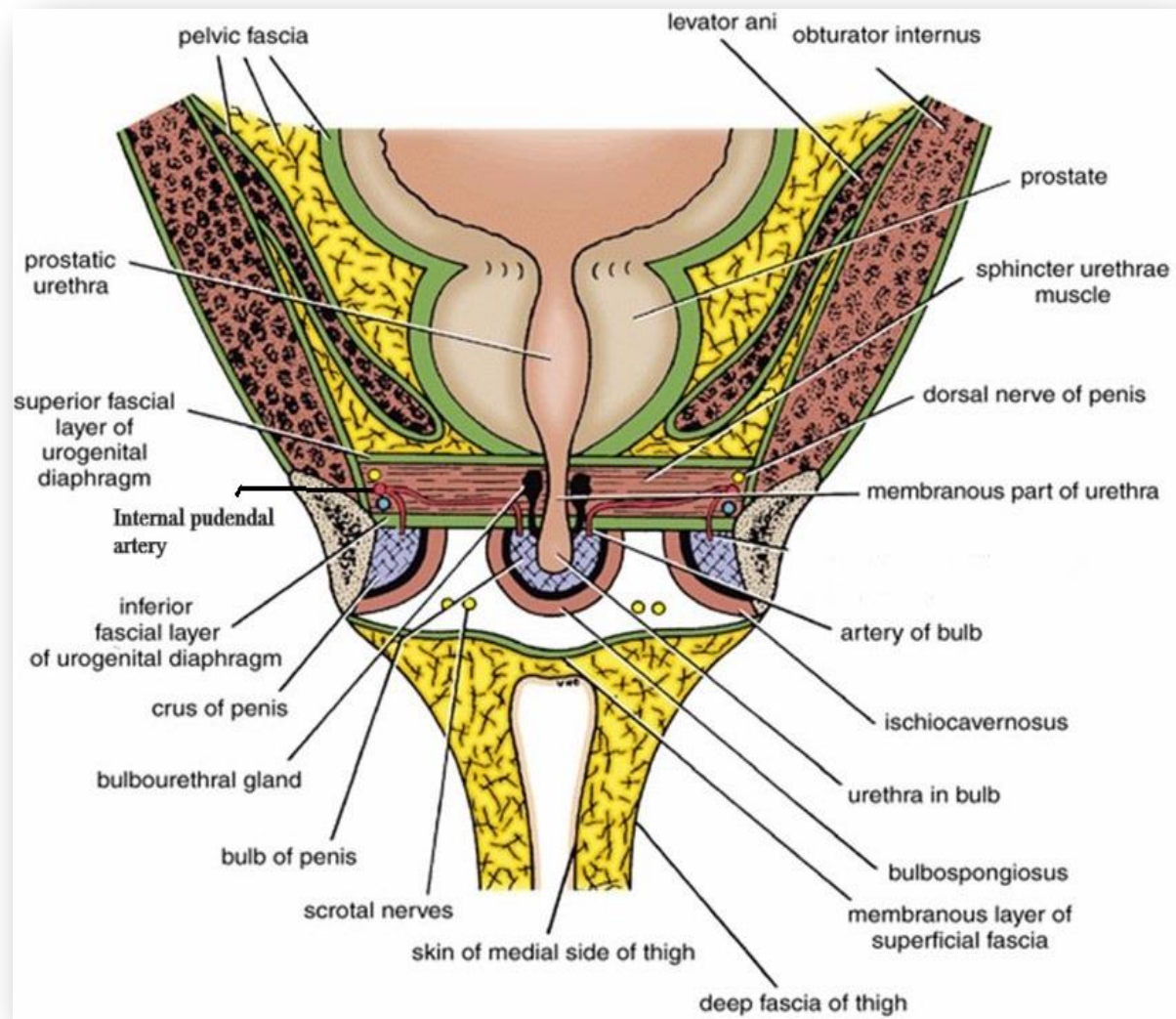
B

Contents of Deep Perineal Pouch

	In Male	In Female
Urogenital Structures	<ul style="list-style-type: none"> Membranous urethra. Bulbourethral (Cowper's) glands <p>At each side of membranous urethra</p>	<ul style="list-style-type: none"> Part of the urethra. Part of vagina
Muscles	<ul style="list-style-type: none"> Sphincter urethrae Deep transverse perineal muscles 	
Vessels	<ul style="list-style-type: none"> Internal pudendal A. Artery of bulb. Of penis Urethral A. Perineal A. 	<ul style="list-style-type: none"> Internal pudendal A. Artery of bulb of vestibule. Perineal A
Nerves	<ul style="list-style-type: none"> Dorsal N. of penis. Perineal N. 	<ul style="list-style-type: none"> Dorsal N. of clitoris. Perineal N.

★رسمه simple يعني مش كل التفاصيل دقيقة؛





Superficial Perineal Pouch

من مميرات ال superficial fascia بشكل عام انها

It lies between; مكونة من طبقتين fat and membrane بهاد المكان

بكونوا مفصولين عن بعضكل وحدة layer

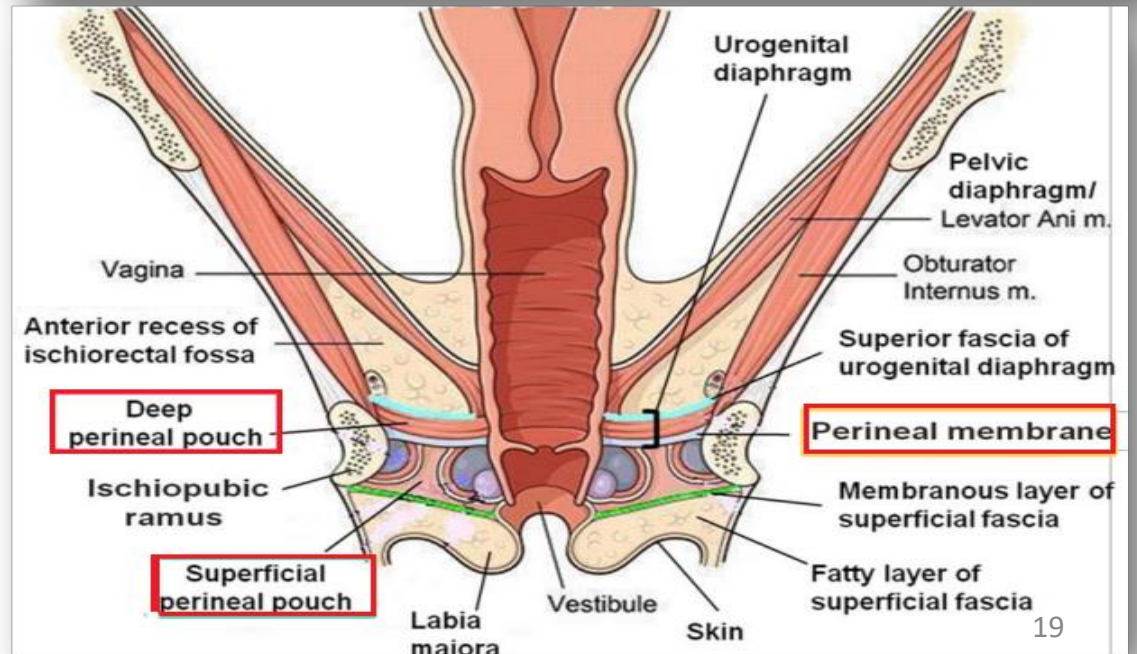
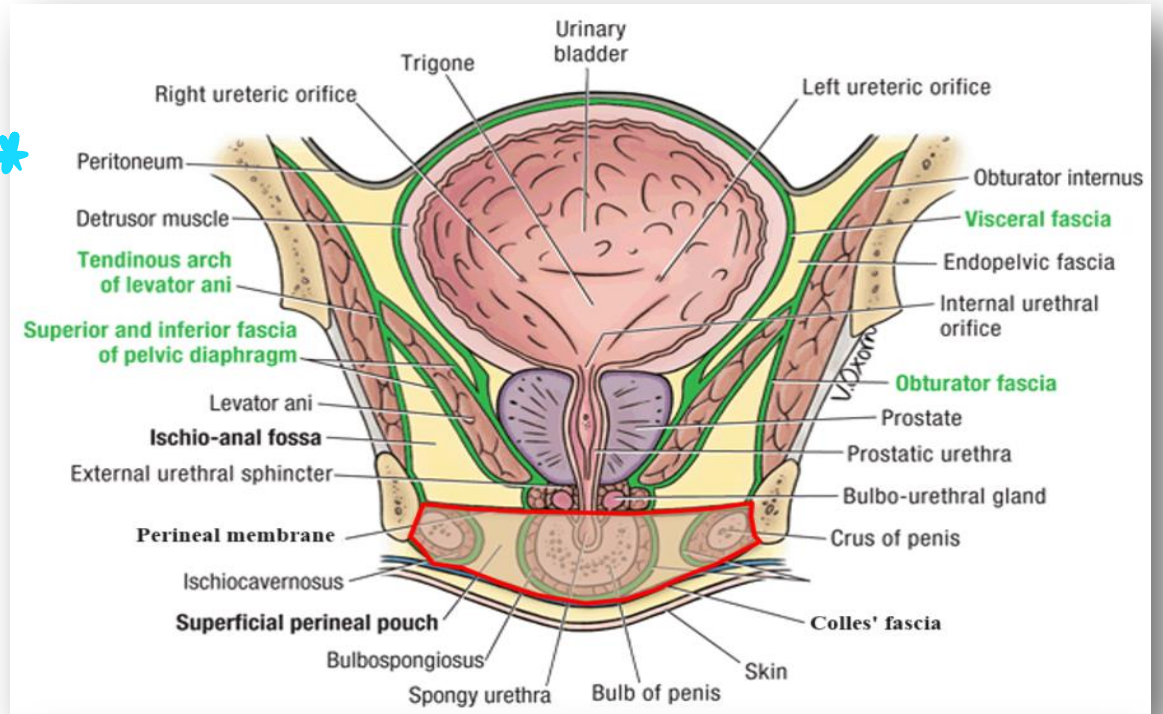
▪ **Roof:** Perineal membrane.

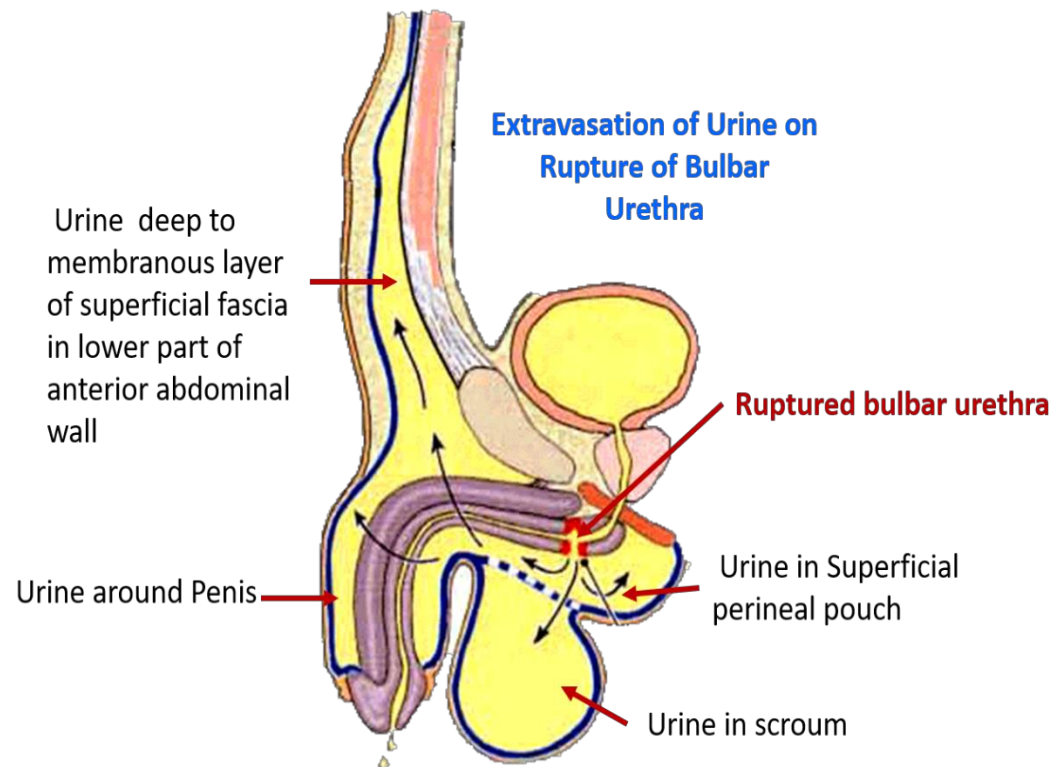
→ Layer of fibers

▪ **Floor:** Membranous layer of the superficial perineal fascia (Colles' fascia).

▪ **Posteriorly:** It is closed by union of the roof and floor.

▪ **Anteriorly:** It is communicates freely with the interval between the membranous layer of superficial fascia of anterior abdominal wall and external oblique aponeurosis.







Rupture of Spongy Urethra:

- The urine extravasates into the superficial perineal pouch and then passes forward into loose connective tissue of the scrotum, around the penis and beneath the membranous layer of the superficial fascia of lower part of anterior abdominal wall.
- Cannot pass posteriorly to anal triangle.

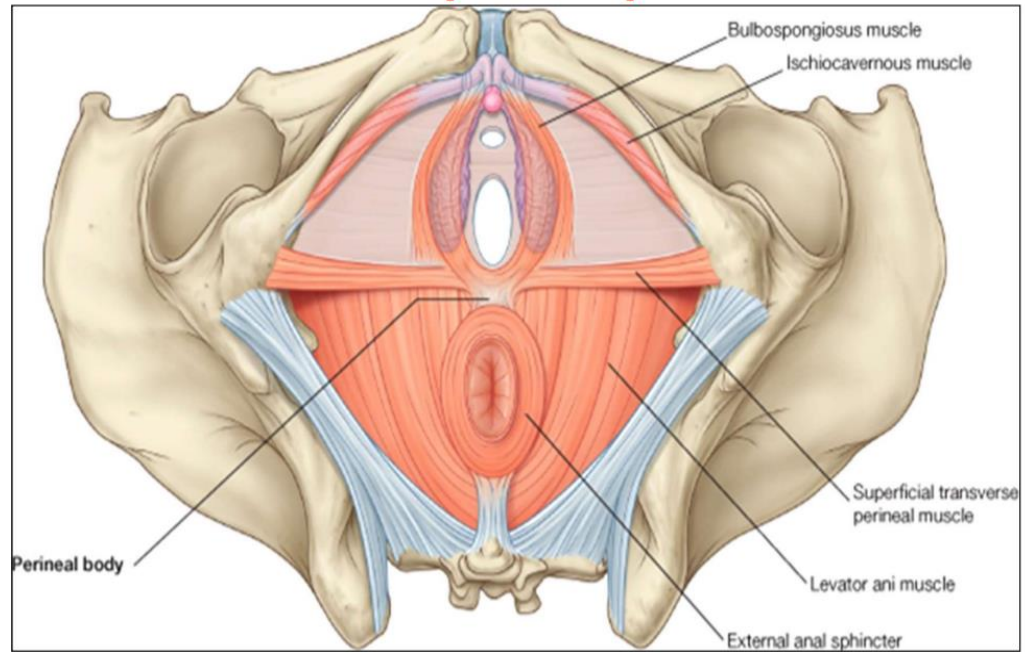
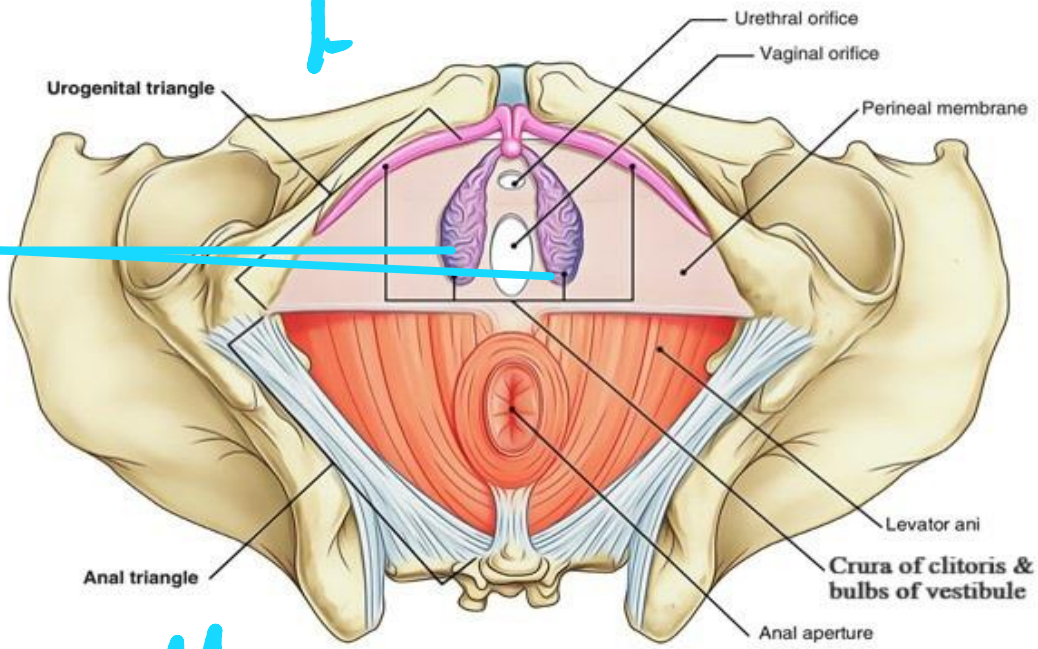
Contents of Superficial Perineal Pouch

Midline structure

	In Male  Erectile tissue	In Female
Urogenital Structures	<ul style="list-style-type: none"> • Root of penis (2 crura + Bulb) • Penile urethra in bulb of penis. 	<ul style="list-style-type: none"> • Root of clitoris (2 crura). <small>ال area التي بفتح فيها</small> • Two bulbs of vestibule. <small>ال vagina and urethra</small> • Greater vestibular glands. 
Muscles	<ul style="list-style-type: none"> • Ischiocavernosus muscles cover the 2 crura. • Bulbospongiosus muscle cover bulb of penis. • Superficial transverse perineal muscles. 	<ul style="list-style-type: none"> • Ischiocavernosus muscles cover the 2 crura. • Bulbospongiosu muscle covers bulb of vestibule. • Superficial transverse perineal muscles.
Vessels	<ul style="list-style-type: none"> • Internal pudendal A. • Dorsal A. of penis. • Deep A. of penis. • Posterior scrotal arteries. 	<ul style="list-style-type: none"> • Internal pudendal A. • Dorsal A. of clitoris. • Deep A. of clitoris. • Posterior labial arteries.
Nerves	<ul style="list-style-type: none"> • Dorsal N. of penis. • Posterior scrotal nerves. 	<ul style="list-style-type: none"> • Dorsal N. of clitoris. • Posterior labial nerves.

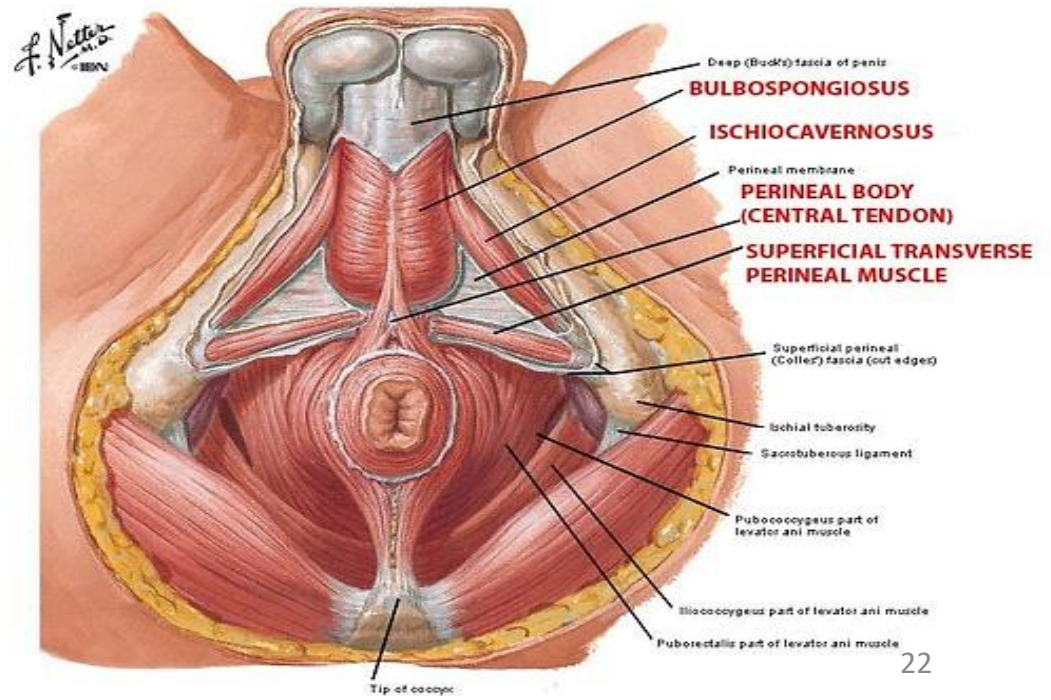
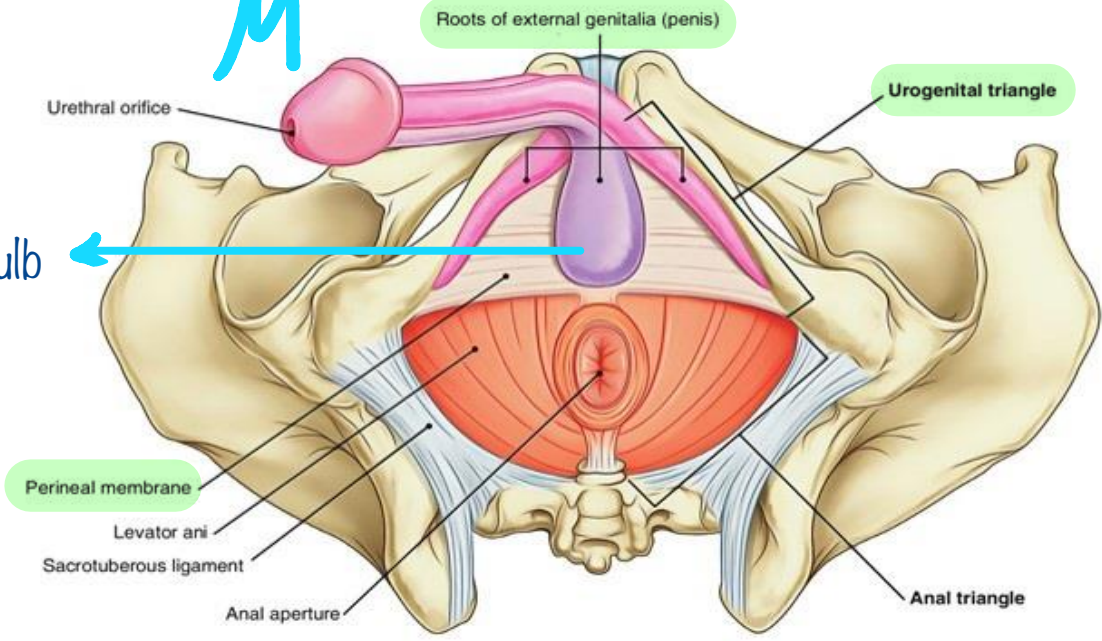
Bulb

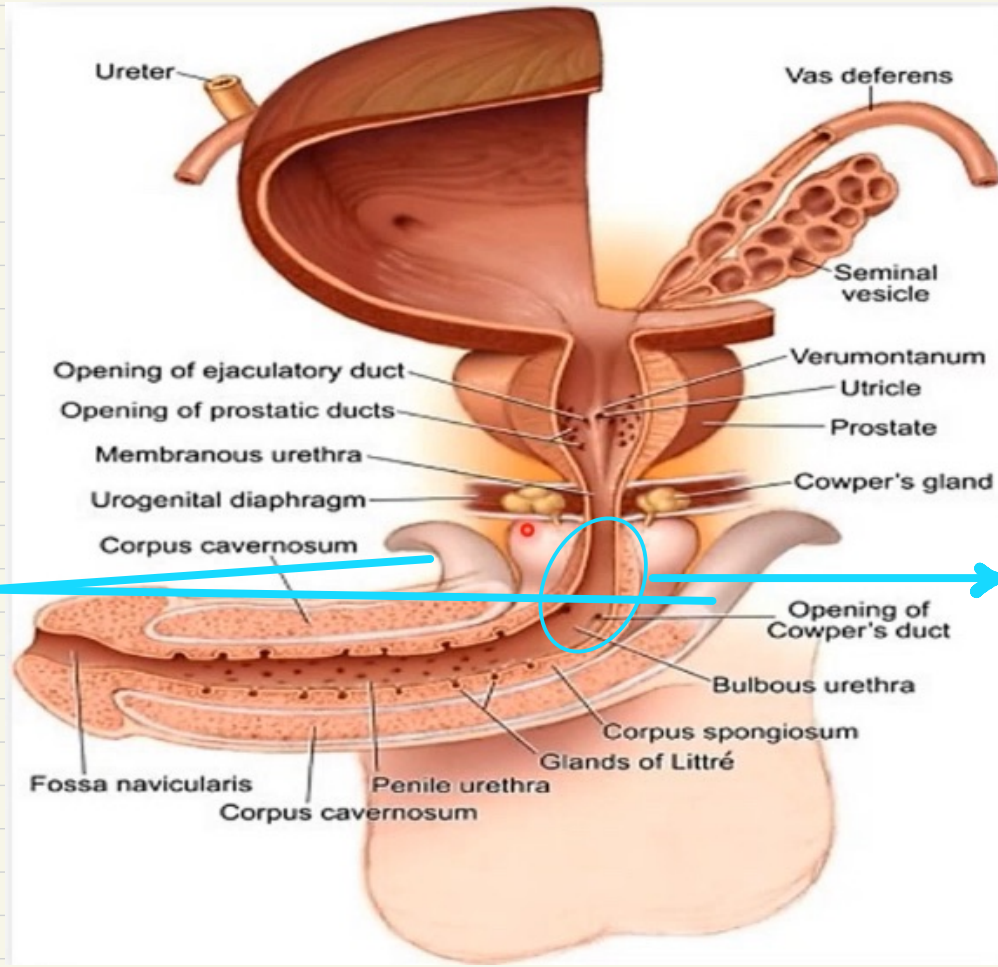
F



Bulb

M





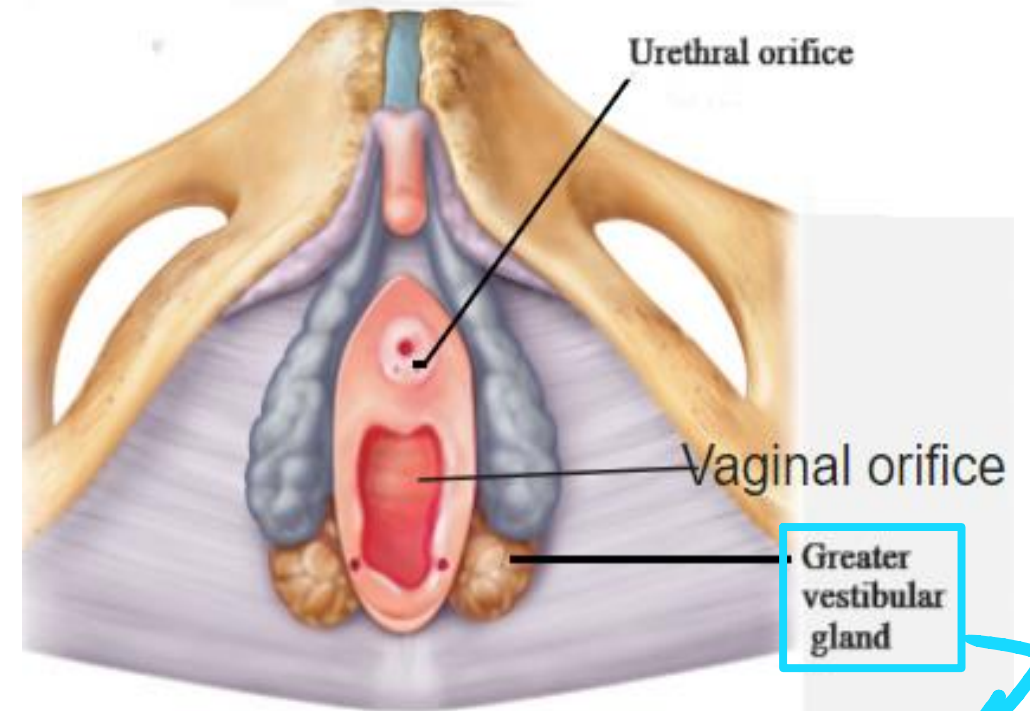
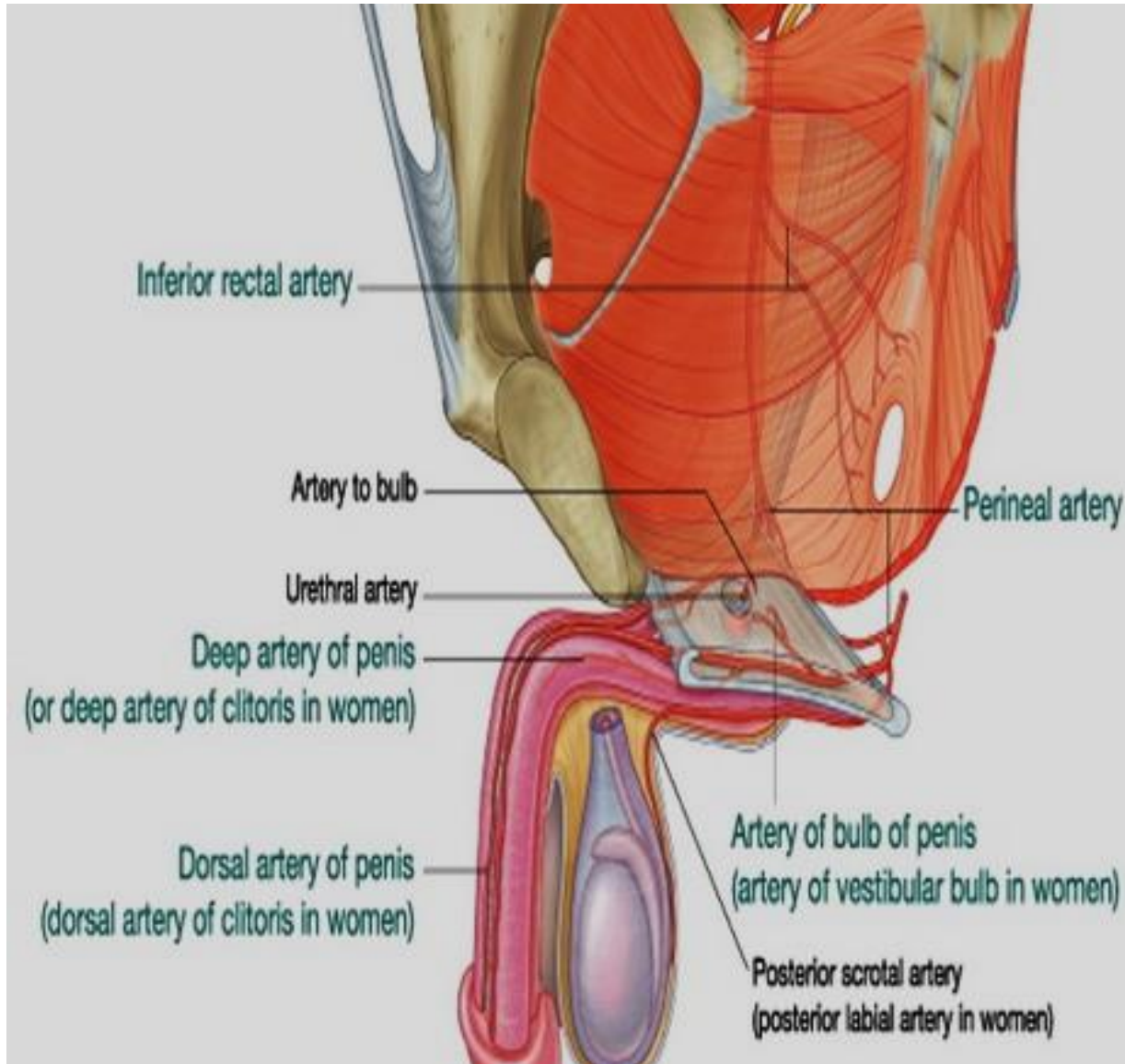
Right and left cruses (erectile tissue)

Bulby part of penile part of male urethra

ال internal pudendal artery بيغطي branch اسمه ال atery of the bulb اول ما يطلع بعمل piercing لل perineal membrane و يدخل ال bulb , عشانه هيك مكتوب انه هاد ال branch من ال contents of deep perineal pouch لكن مش من ال contents of superficial perineal pouch لانه هو مش موجود فيها ما بقدر امسكه بايدي لانه او ما عمل piercing فات ال bulb على طول

من الرسمة تبعوا على ال male urethra راح نشوف بالاول ال prostatic part بعدين ال membranous الي هي بال deep perineal pouch , ال bulby part of penile part of urethra is ال , the part of the urethra that lies in the bulb of the penis tissue تاها ب corpus cavernosum

ال cowper's gland موجودة بال deep perineal pouch و لكن ال duct تاعتها بتعمل piercing لل perineal membrane و بتخترق ال bulb و بتفتح بال penile urethra



* Mucus gland in the superficial perineal pouch which is related to posterior end of bulb of vestibule

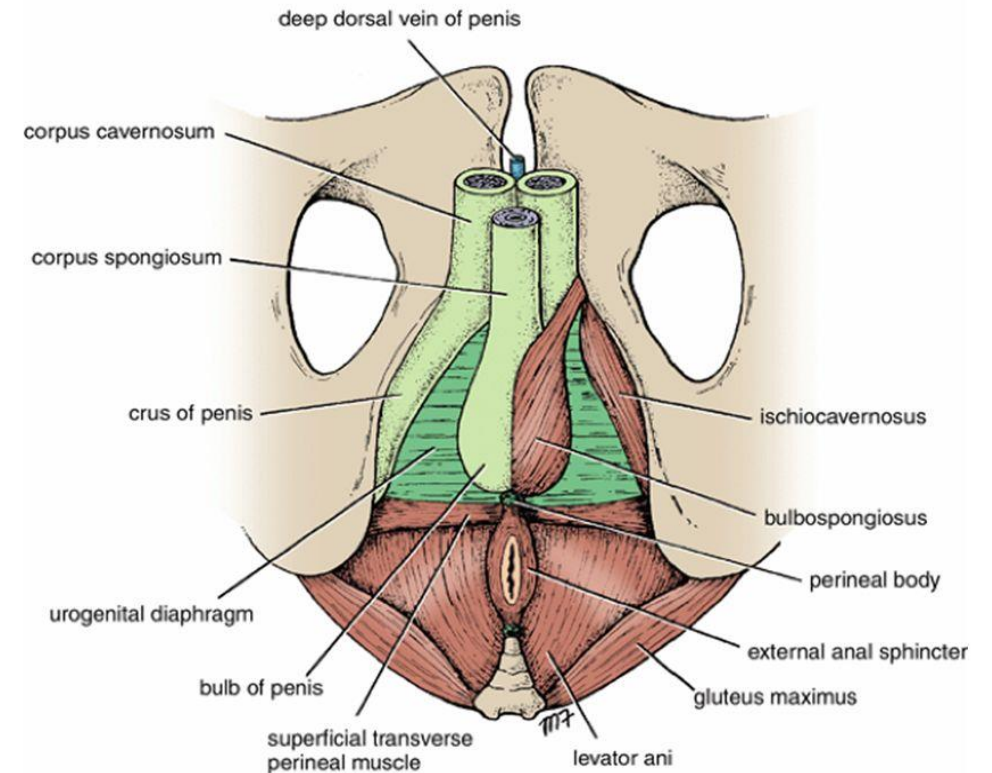
Action of muscles of superficial perineal pouch:

Ischiocavernosus muscles:

- Maintain erection of the penis by compressing the crus and the deep dorsal vein of the penis, thereby retarding venous return.

Bulbospongiosus muscle:

- **In Male:** Assist in erection of penis. And expelling last drops of urine during micturition or the final semen in ejaculation.
 - **In Female:** Act as sphincter vagina and help in erection of clitoris.
-
- All muscles in superficial perineal pouches are supplied by perineal branch of pudendal nerve.

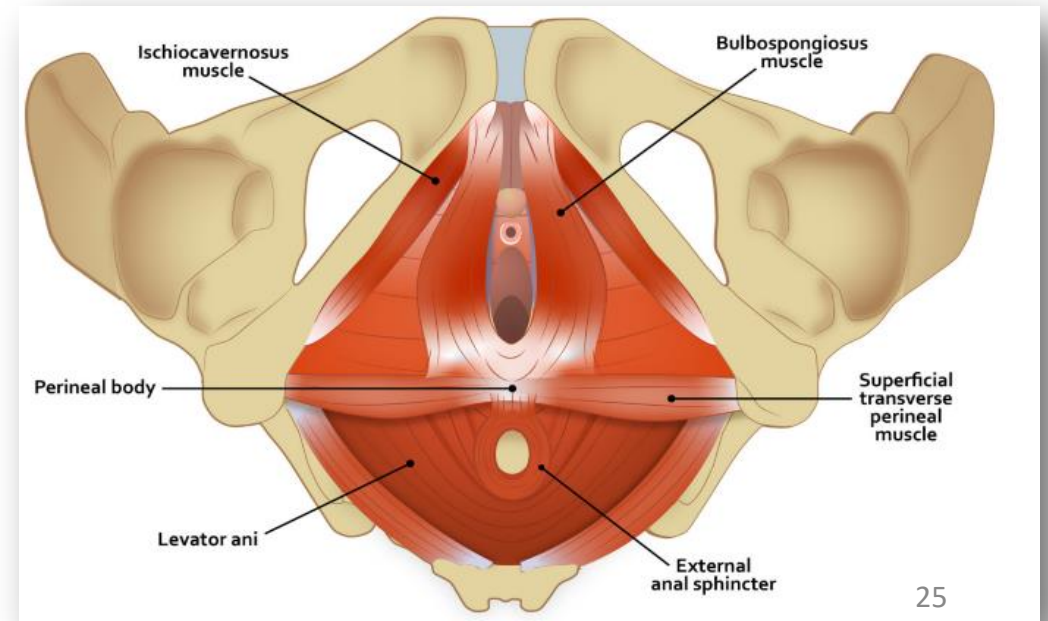
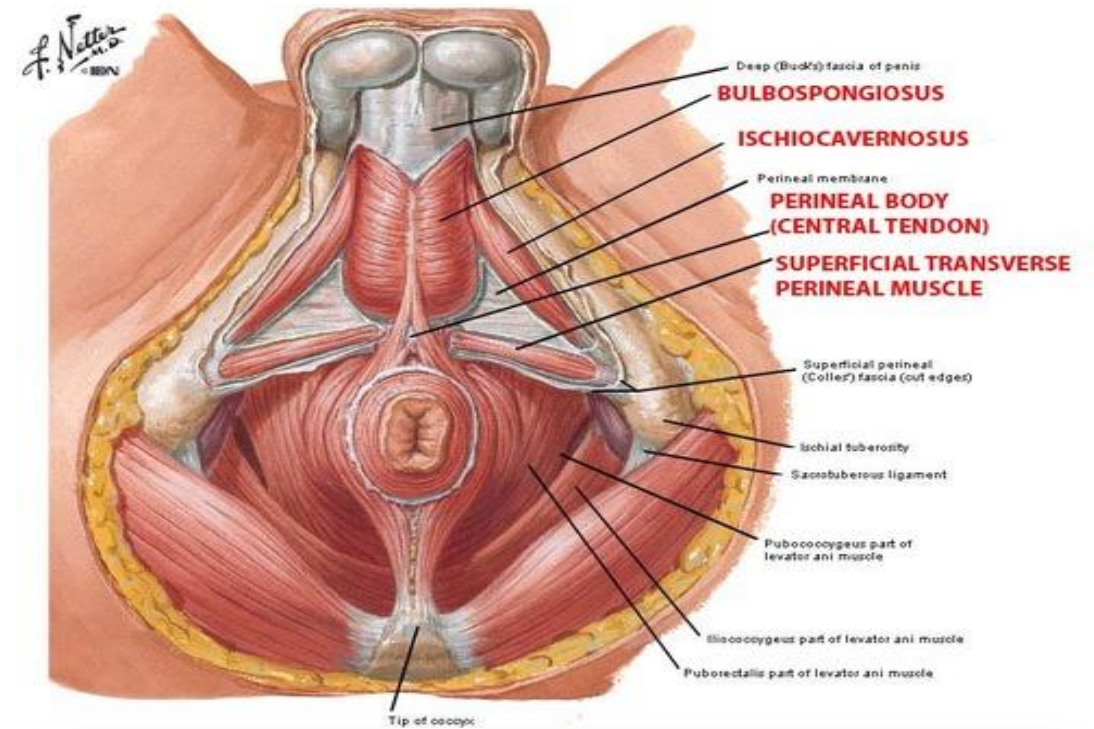


Perineal Body

↳ Central tendon of perineum

- Is a fibromuscular mass located in the center of the perineum between the anal canal and the vagina (or bulb of the penis).
- Serves as a site of attachment for the superficial and deep transverse perineal, bulbospongiosus, levator ani, and external sphincter muscles

* In females it supports the vagina and uterus to prevent prolapse

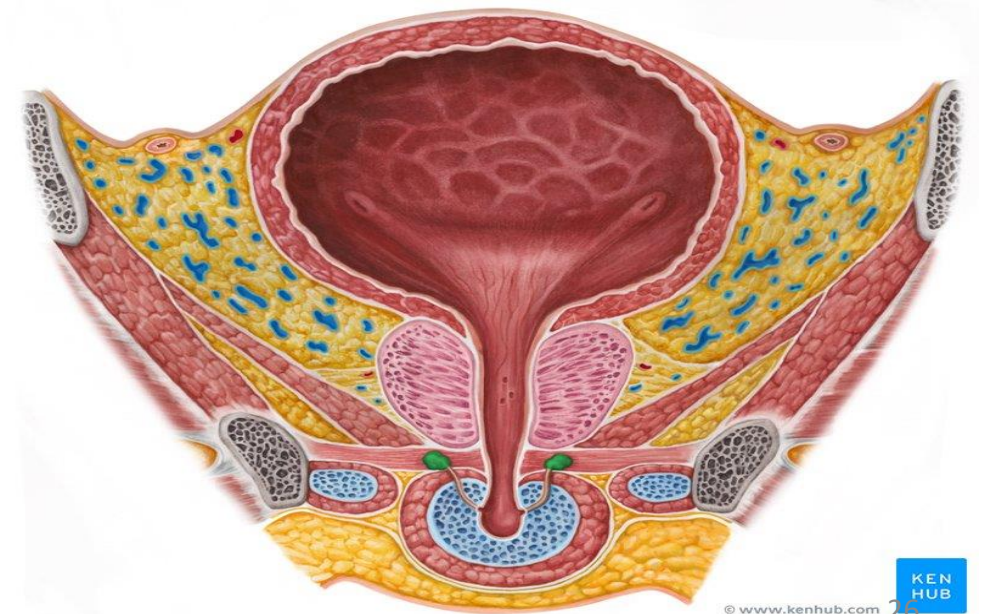
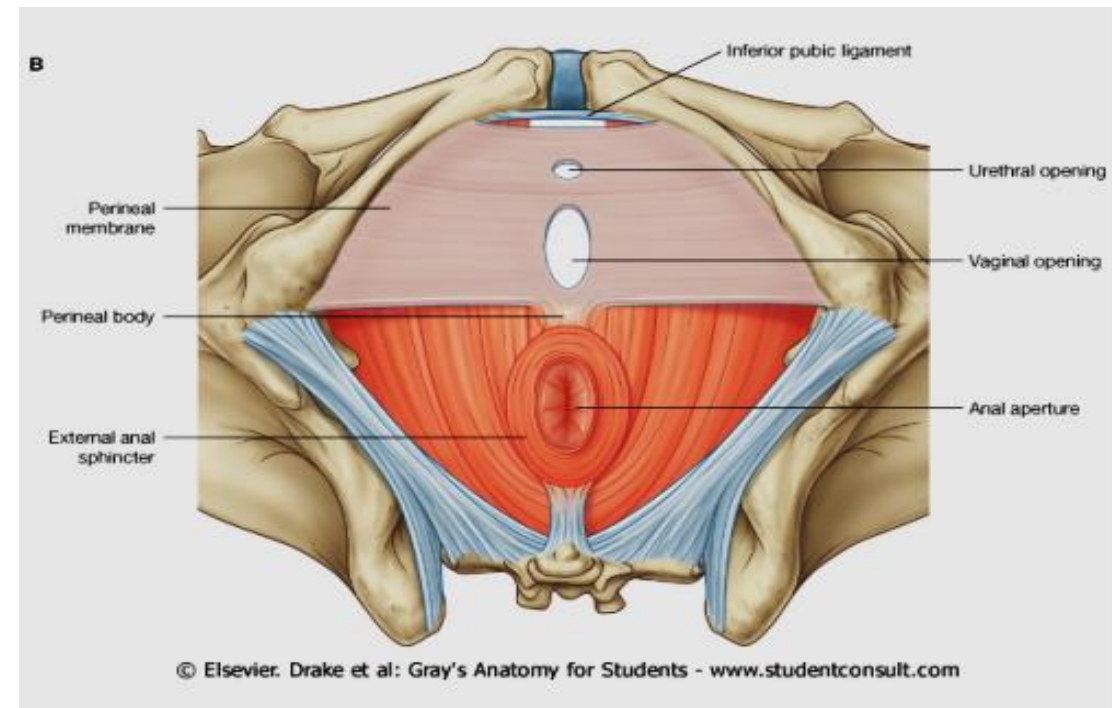


Perineal Membrane

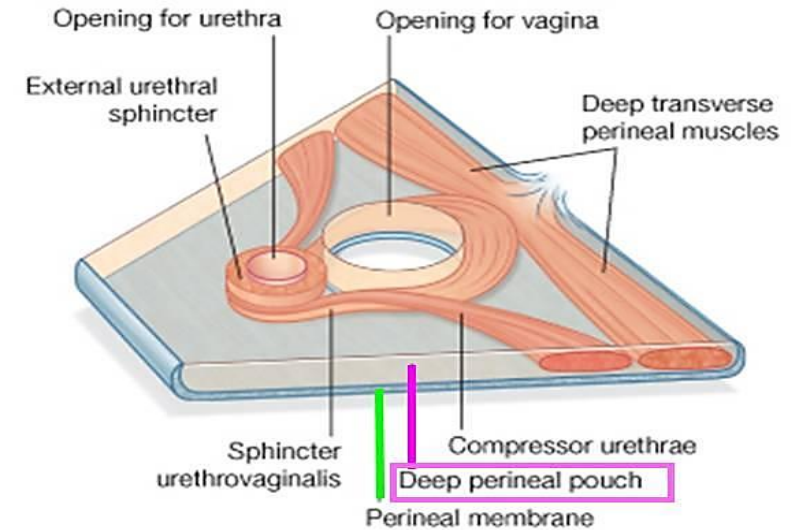
- It is a fibrous membrane in the perineum. "inferior fascia of urogenital diaphragm".
- It forms the floor of the deep perineal pouch.
- It forms the roof of the superficial perineal pouch.

It is perforated by:

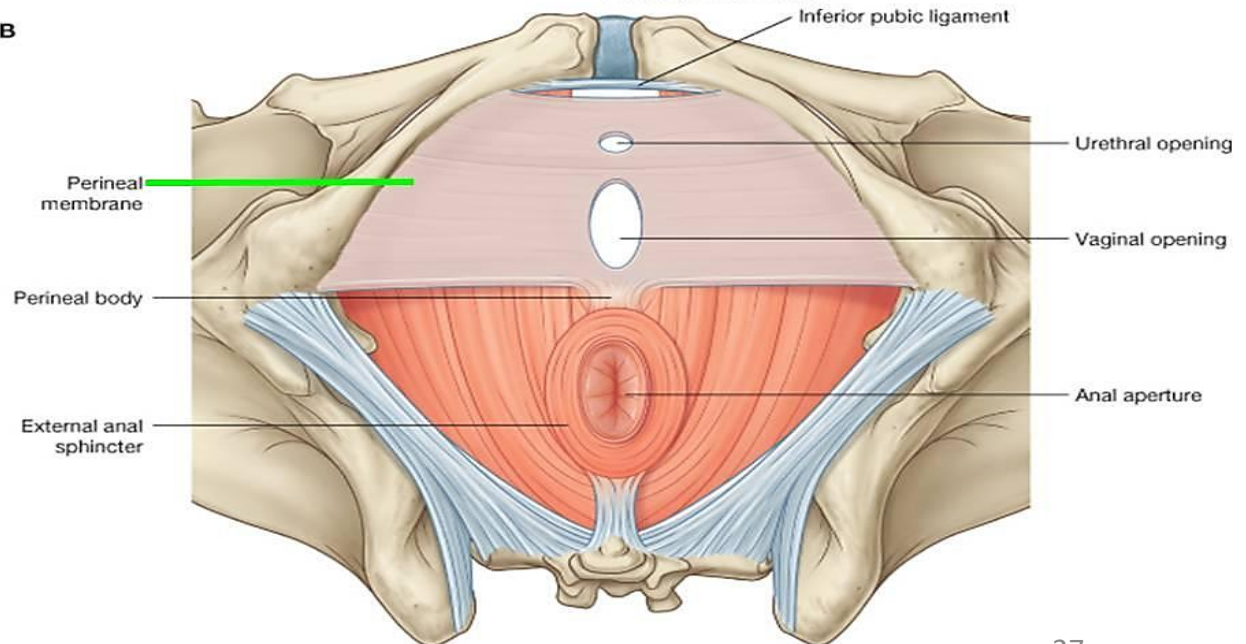
- Urethra.
- Vagina.
- Ducts of two bulbourethral gland (male).
- Internal pudendal A.
- Artery of bulb.
- Dorsal nerves of penis or clitoris.
- Posterior scrotal or labial nerves and vessels.



- Perineal membrane thickened anteriorly to form the transverse perineal ligament.
- The transverse perineal ligament is separated from the symphysis pubis by a gap.
- Through this gap the deep dorsal vein of penis enters the pelvis to join the prostatic venous plexus.



B



**Thank
you**