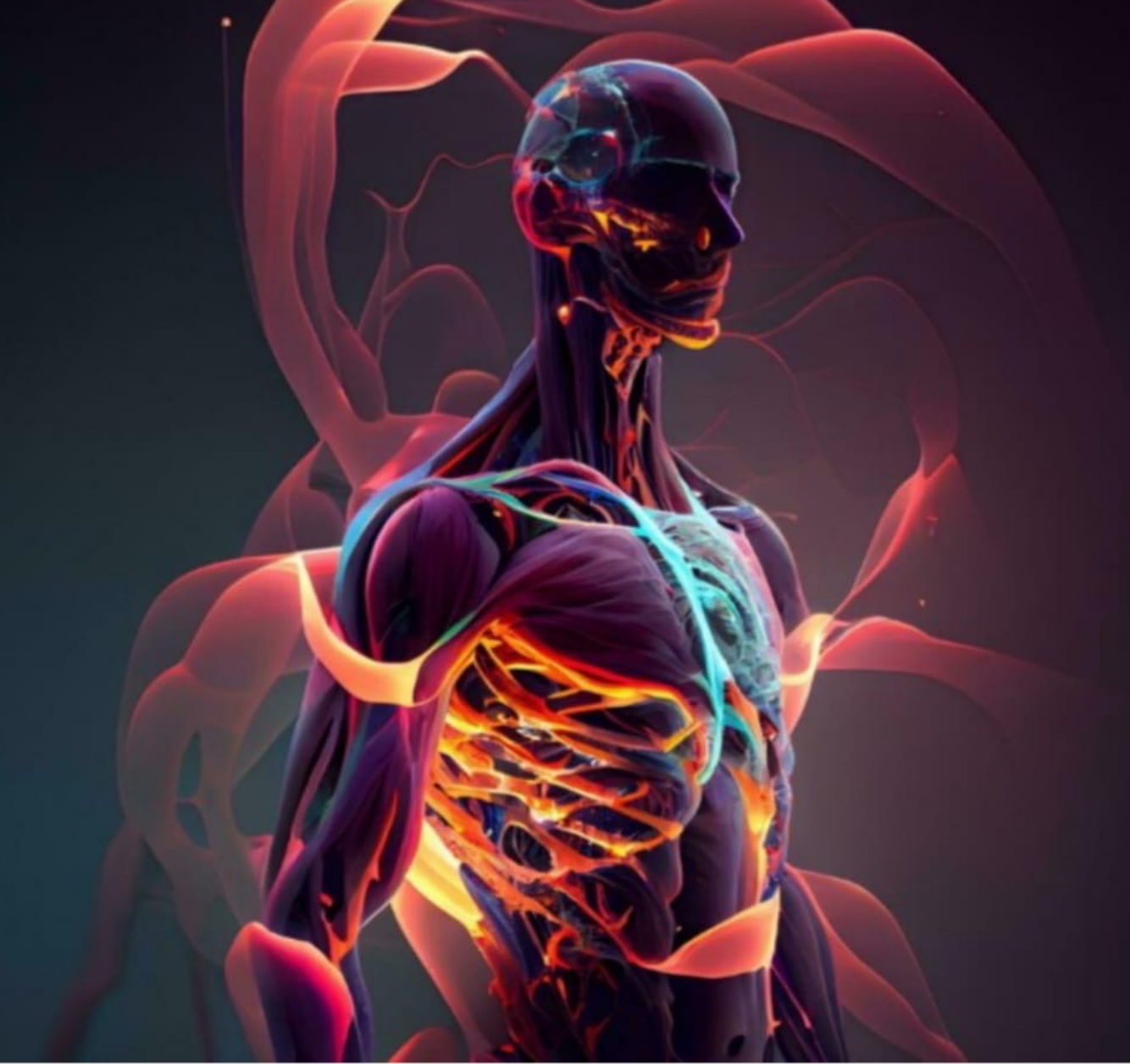



Lecture: Lab 7

Done By: Wafaa Alfarabshah

# **Lab 7**

## **Muscles of Head, Neck & Trunk**

لذاتها موجودة عند الـ  
lumber vertebrae

Quadratus Lumborum

لها شكلها رباعي

جزء منها يكون وراء الـ kidney

Transversus Abdominis

most lateral

iliac crest

Psoas Major

medial to quadratus lumborum.

Iliacus

لها العظمة التي يتكون

شابكية على الـ iliac fossa

medially

\* The above 4 muscles are part of the posterior abdominal wall.

Quadratus Lumborum

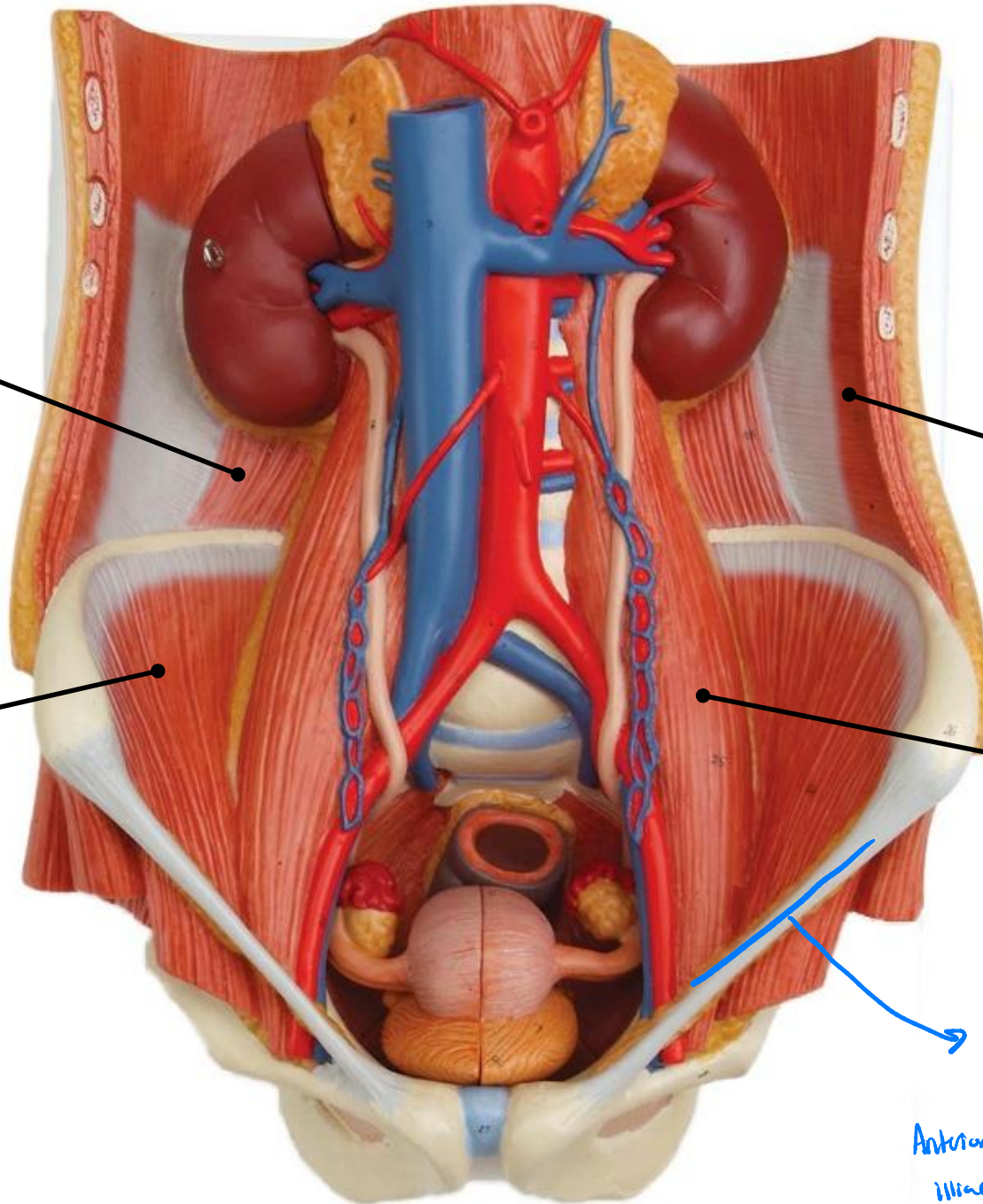
Transversus  
Abdominis

Iliacus

Psoas Major

inguinal ligament

و تكون مرتبطة مع  
Anterior superior  
iliac crest.



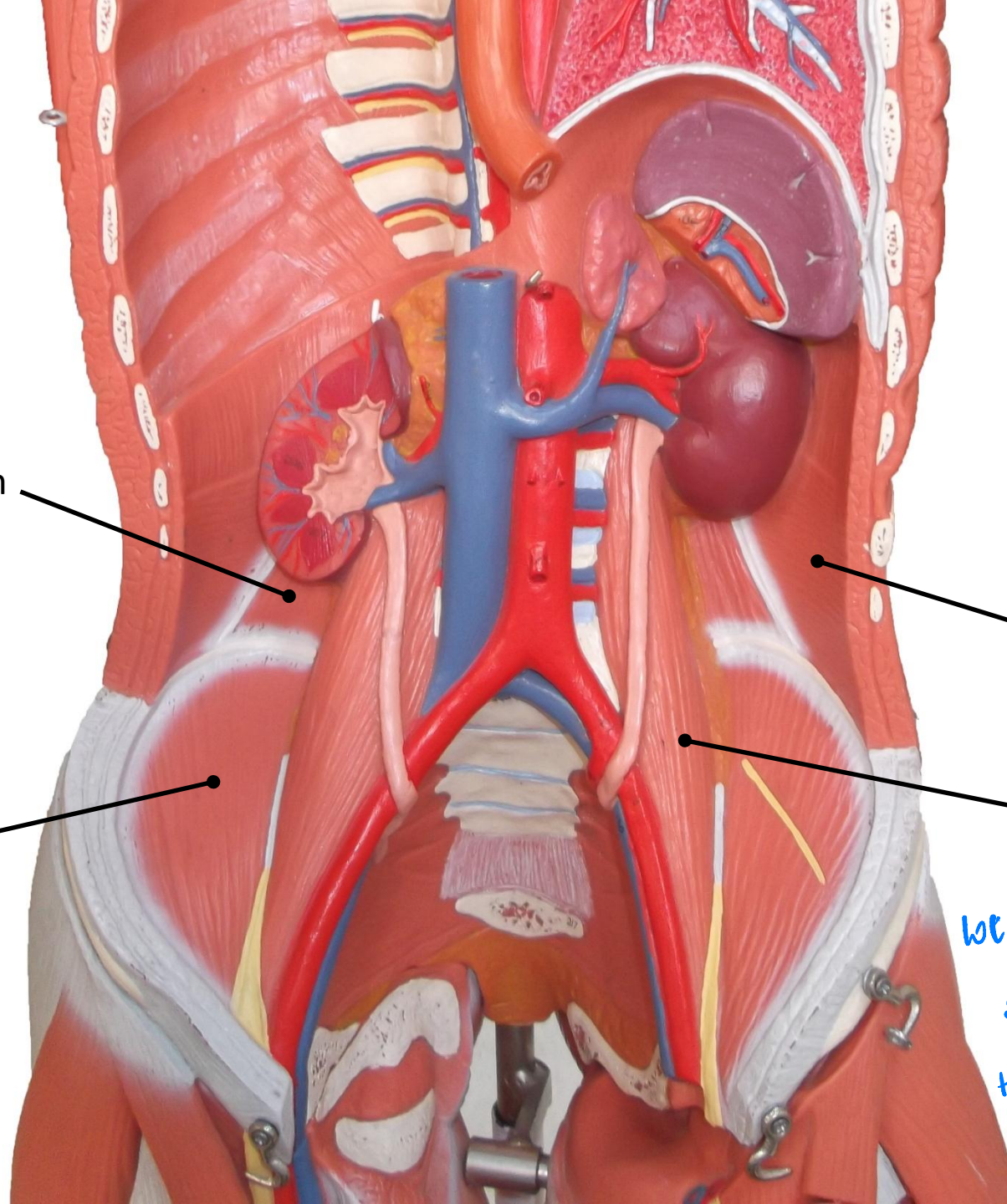
Quadratus Lumborum

Transversus  
Abdominis

Iliacus

Psoas Major

خلينا نذكر العنفة psoas illio ili أي أضلاع  
في lab 6 ، لكي العنفة تكونت نتيجة  
إتحاد tendon of psoas major + tendon + iliacus



opponerosty  
[ connective tissue ]

Occipitofrontalis  
(Frontal Belly)  
Plechy fiber ishty

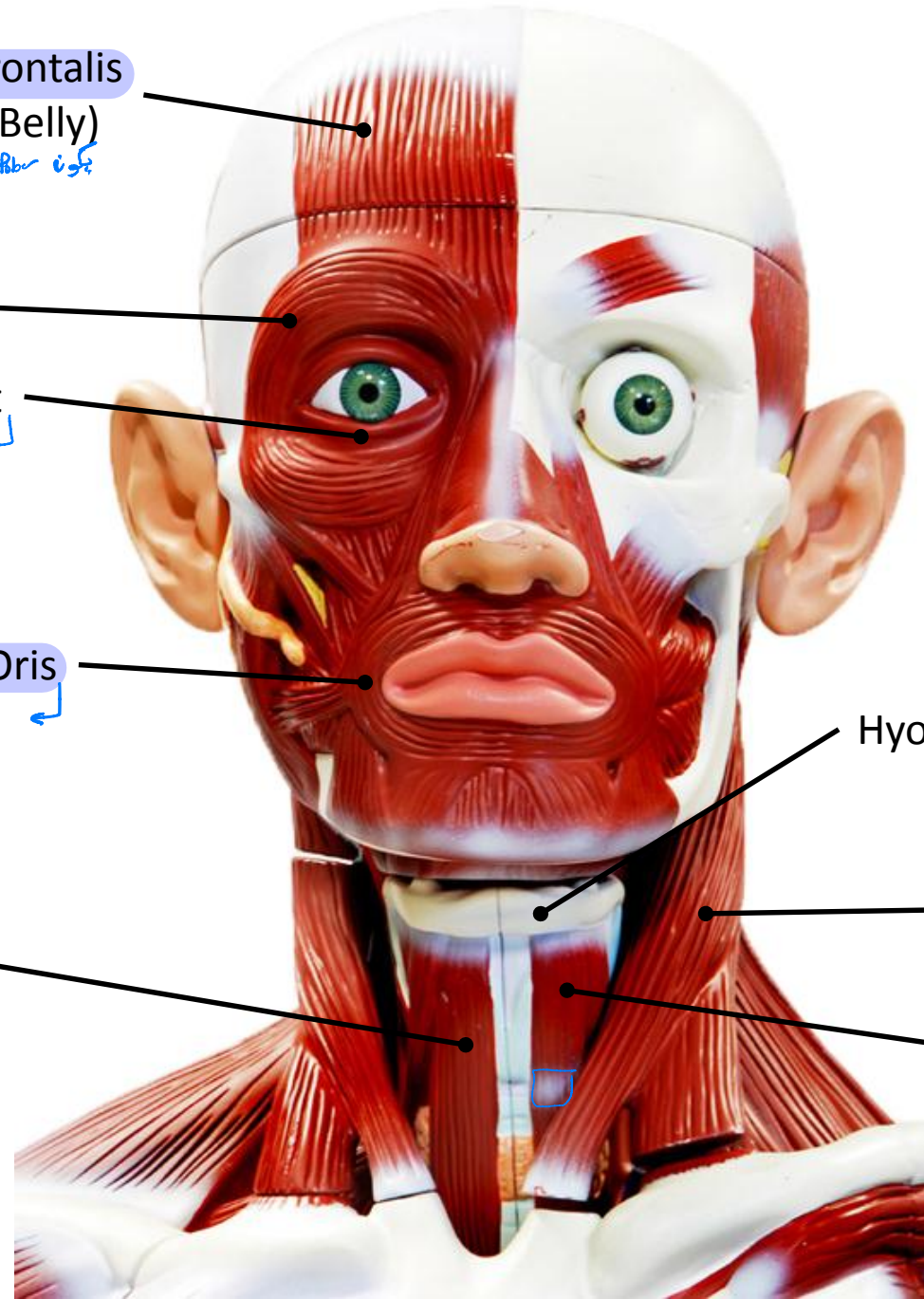
Orbicularis Oculi:  
1- Orbital Part  
2- Palpebral Part  
eye lids

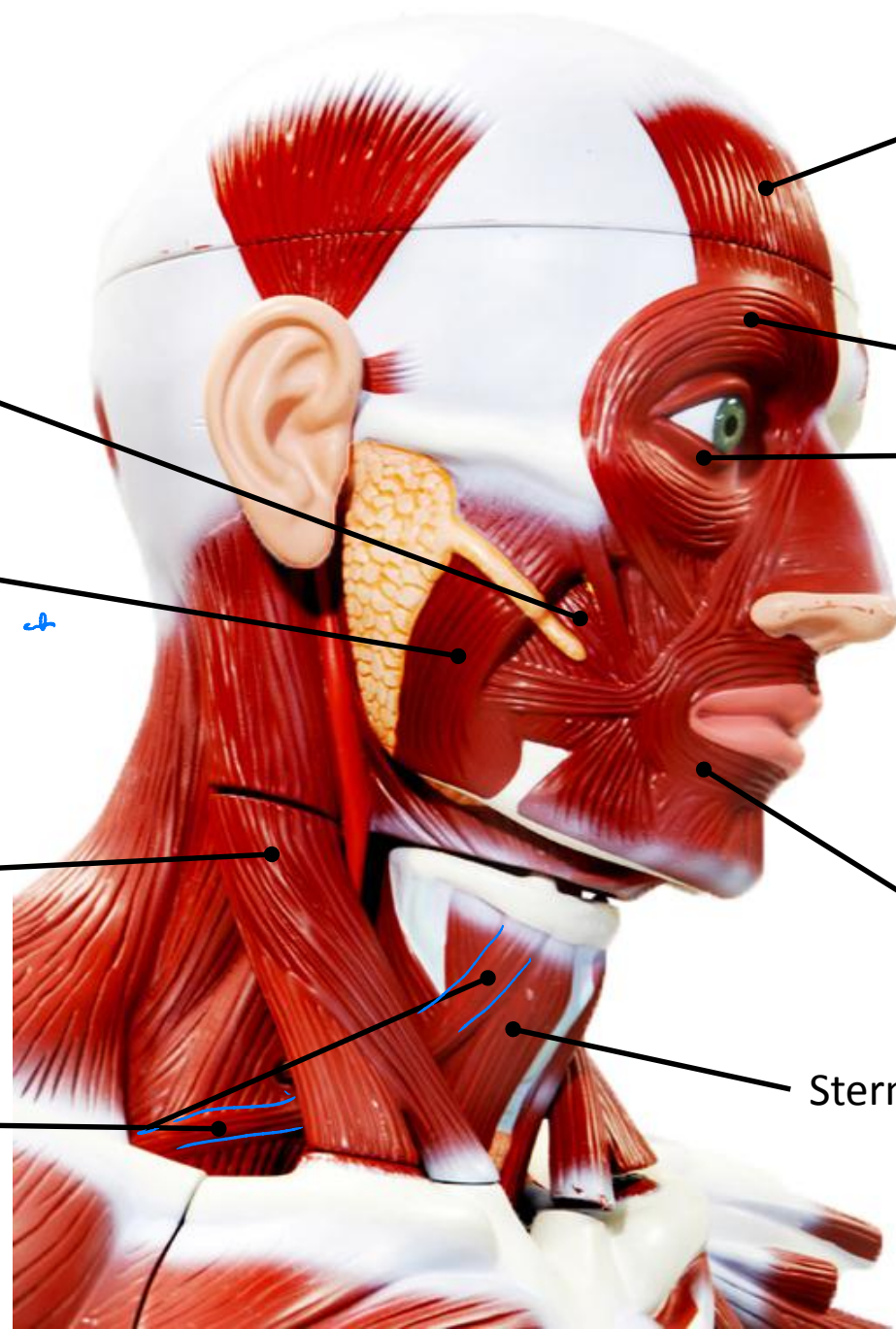
Orbicularis Oris  
Closes mouth

Sternohyoid  
found on each side of the midline  
superficial

Sternocleidomastoid  
(Sternomastoid)

Thyrohyoid  
Deep to Sternohyoid  
has a tendon in the middle  
thyroid





Occipitofrontalis  
(Frontal Belly)

Orbicularis Oculi:

1- Orbital Part

2- Palpebral Part

Buccinator

muscle of the  
cheek

Masseter

covers the ramus of  
the mandible

Sternocleidomastoid  
(Sternomastoid)

of temporal bone

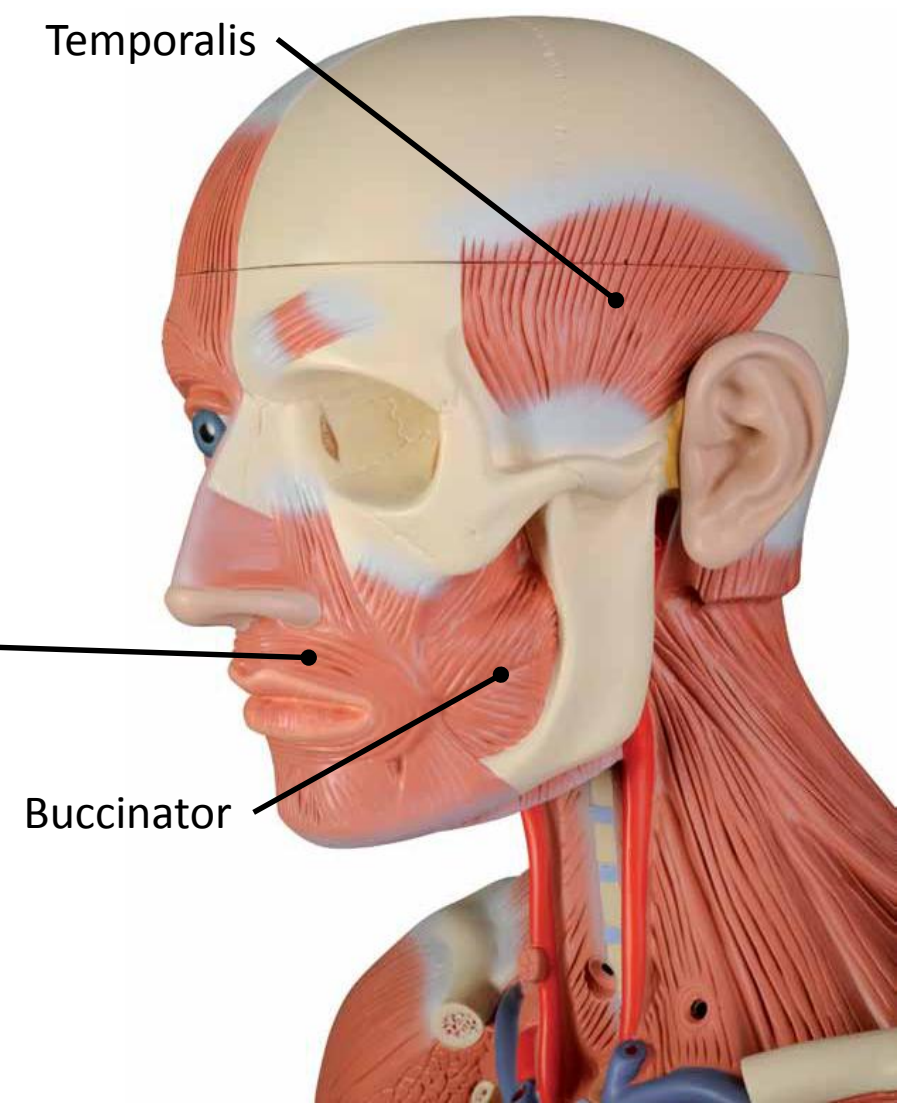
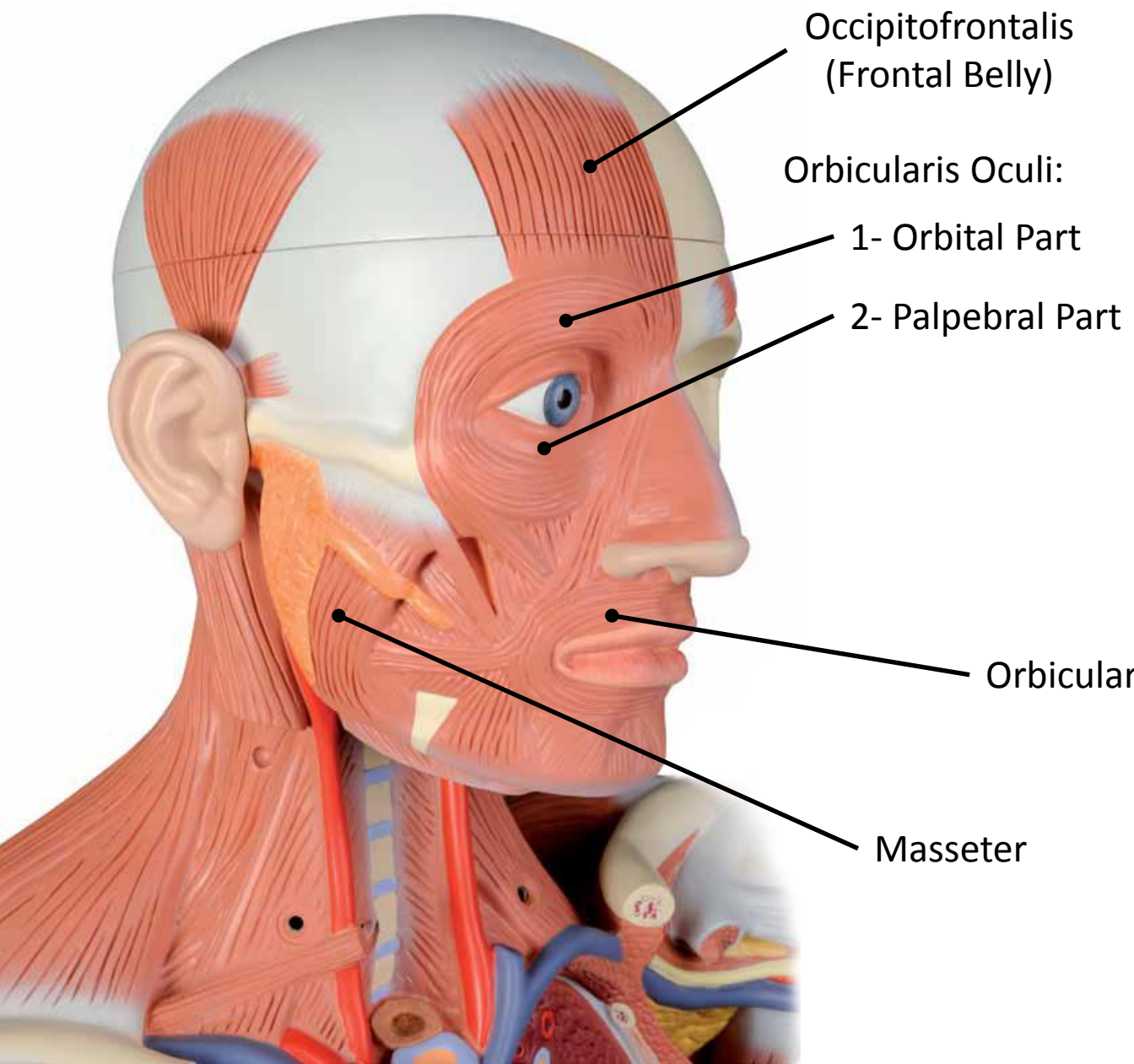
has 2 heads: clavicular and sternal

Omohyoid

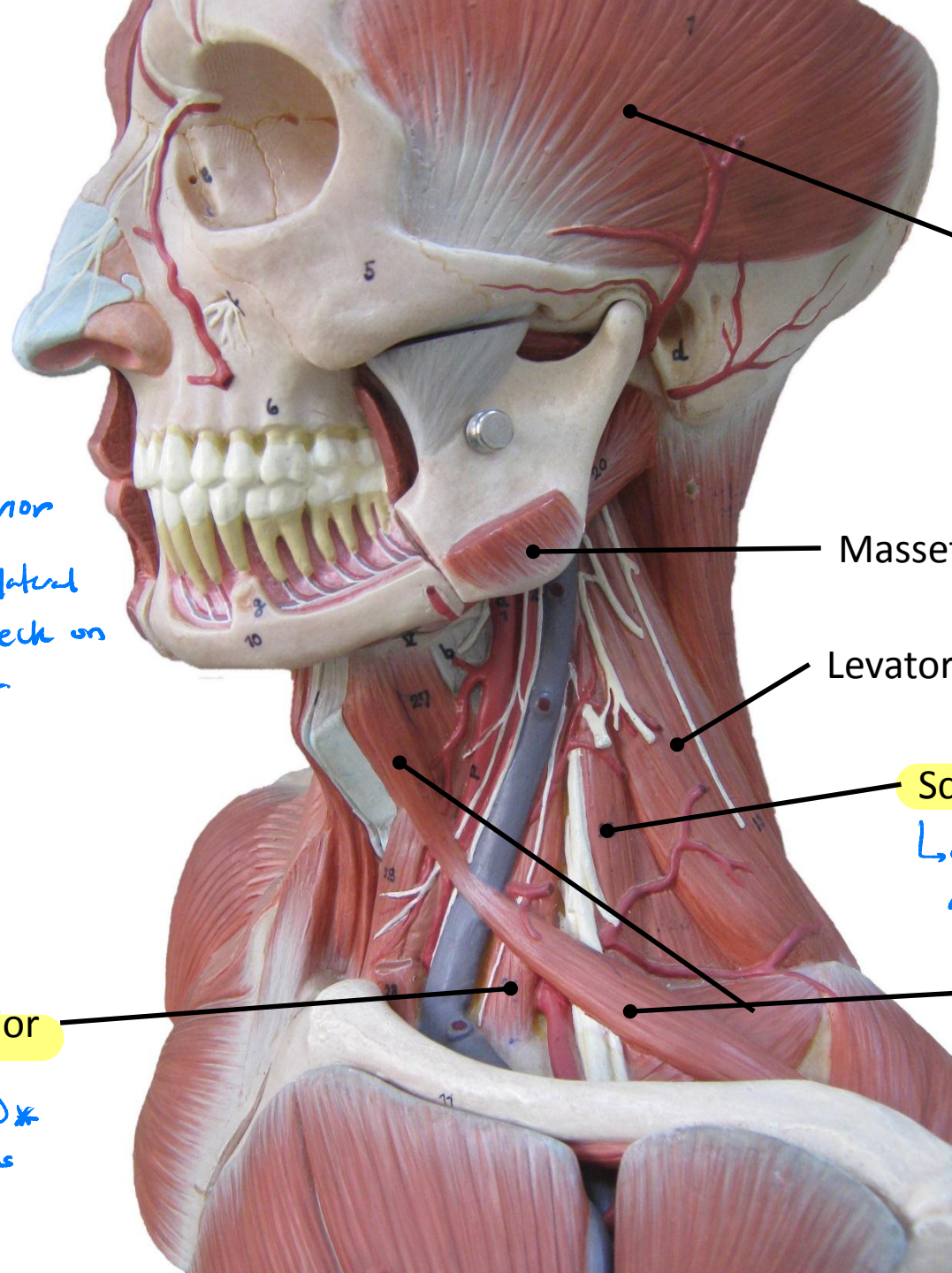
obliquely from clavicle  
to hyoid bone.

Orbicularis Oris

Sternohyoid







Temporalis

- ↳ muscles of mastication
- ↳ elevates mandible
- ↳ inserts in mandible

Masseter

Levator Scapulae

Scalenus Medius

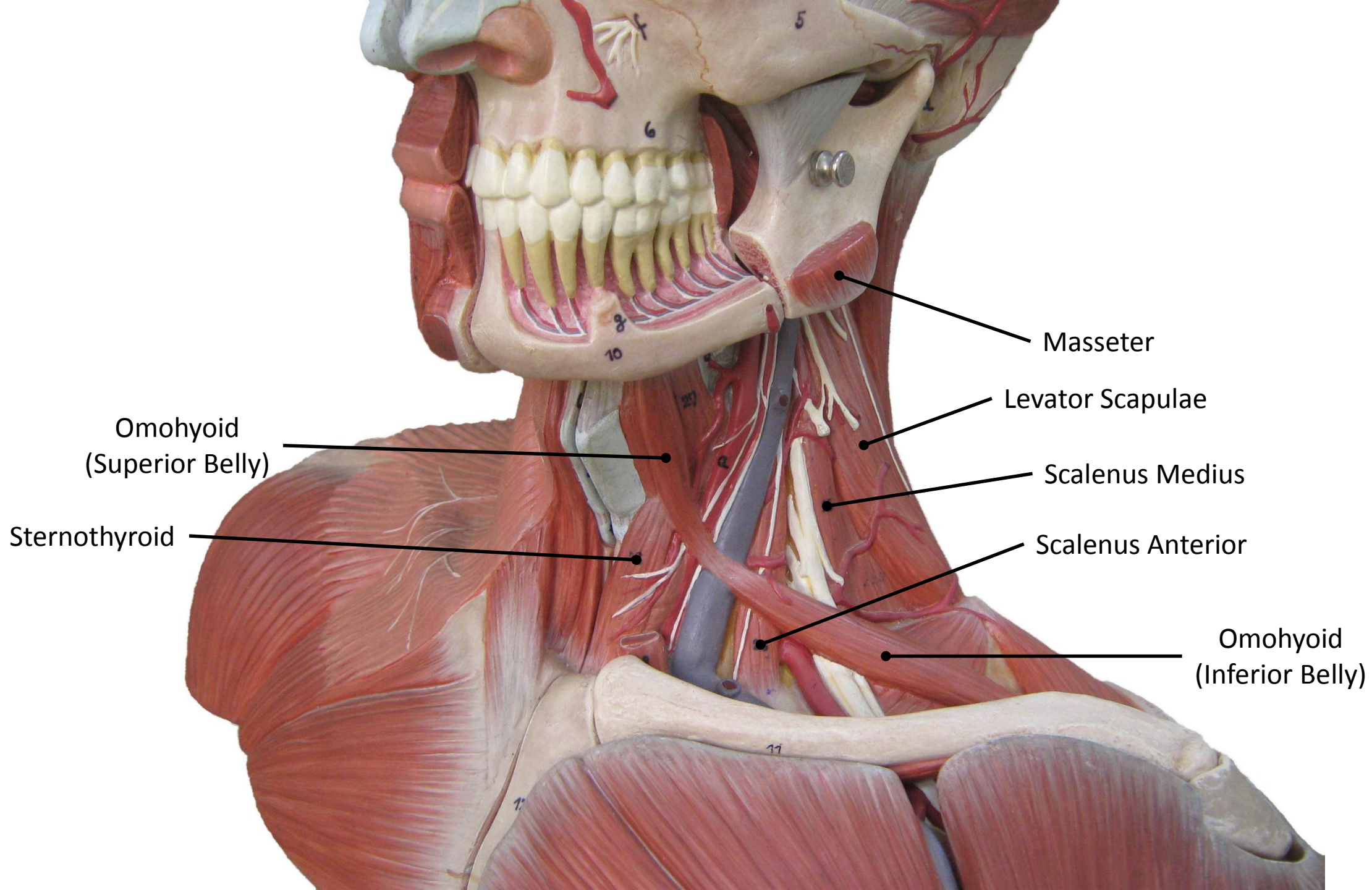
- ↳ Scalenus medius + Anterior are deep to Sternocleidomastoid muscle.

Omohyoid

Scalenus Anterior

\* تكون شللا ال Sternocleidomastoid  
عشان نقدر نشوف ابي تحسها.

→ Levator scapuli + Scalenus Anterior + medius ⇒ found on the lateral side of the neck on each side.



Masseter

Levator Scapulae

Scalenus Medius

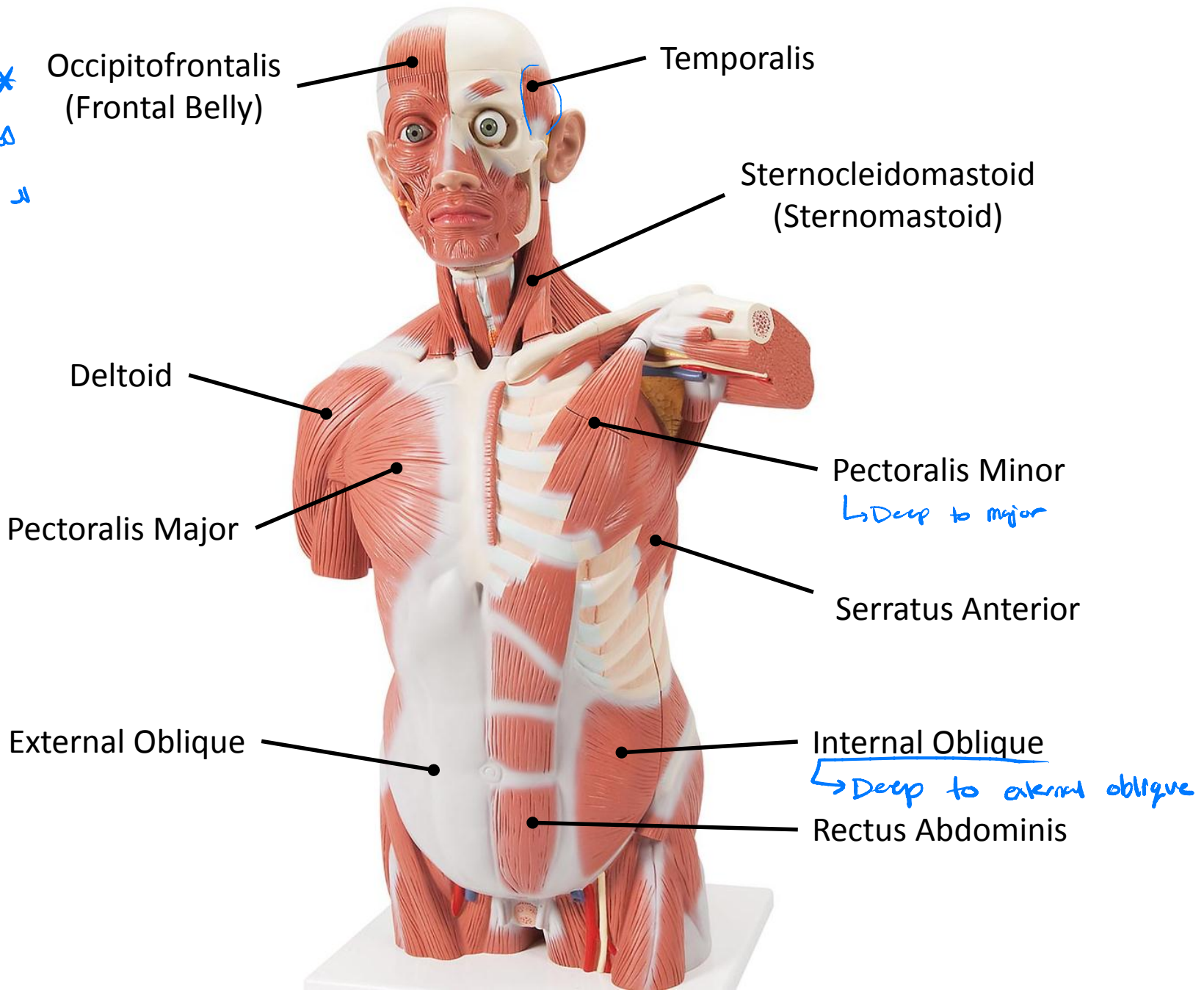
Scalenus Anterior

Omohyoid  
(Inferior Belly)

Omohyoid  
(Superior Belly)

Sternothyroid

\* من كون لآخر سلايدان  
لذا ال طباء ← مراجعة  
ال Upper limb .



all 3 are deep to trapezius  
نقذ كر آينها  
انه كدرول ال 3 عضلات  
يكون ال insertion تبصير  
ميدان border ال ال ال  
the scapula.

Levator Scapulae

Rhomboideus Minor

Supraspinatus

Infraspinatus

Rhomboideus Major

Occipitofrontalis (Occipital Belly)

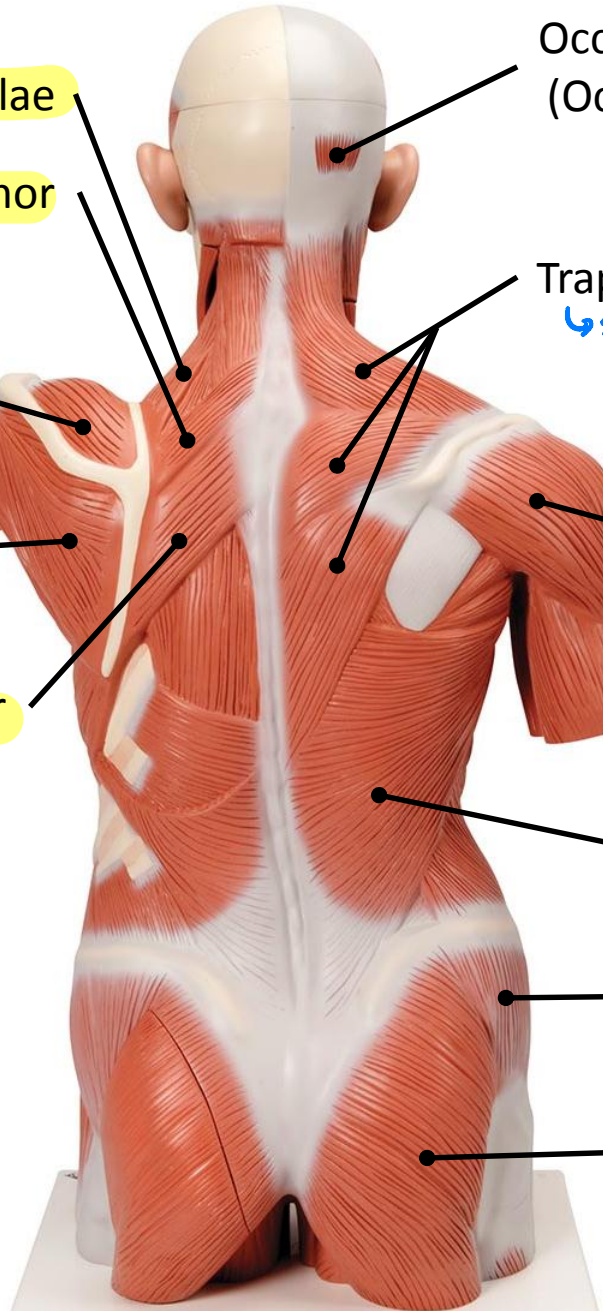
Trapezius  
↳ superficial

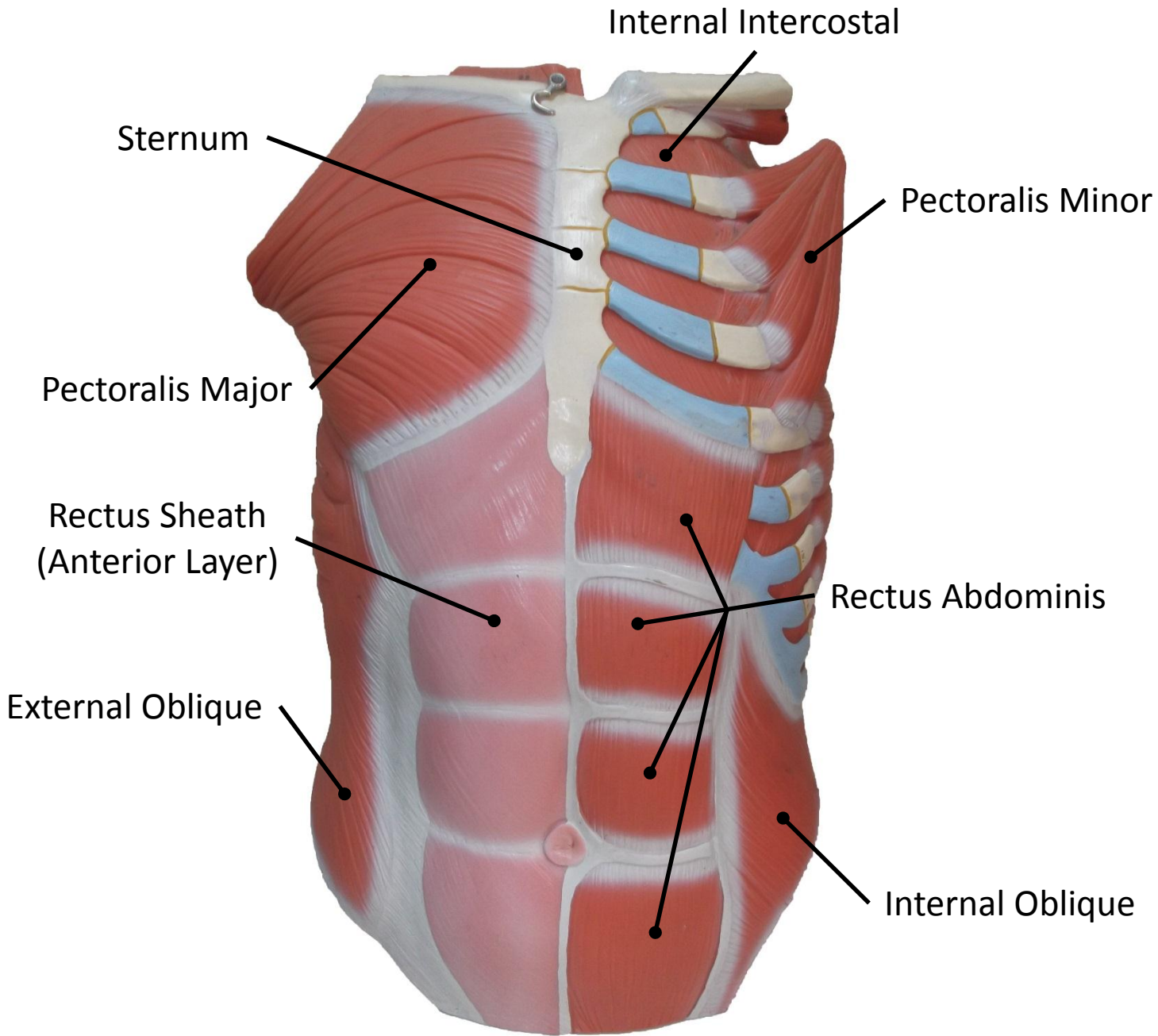
Deltoid

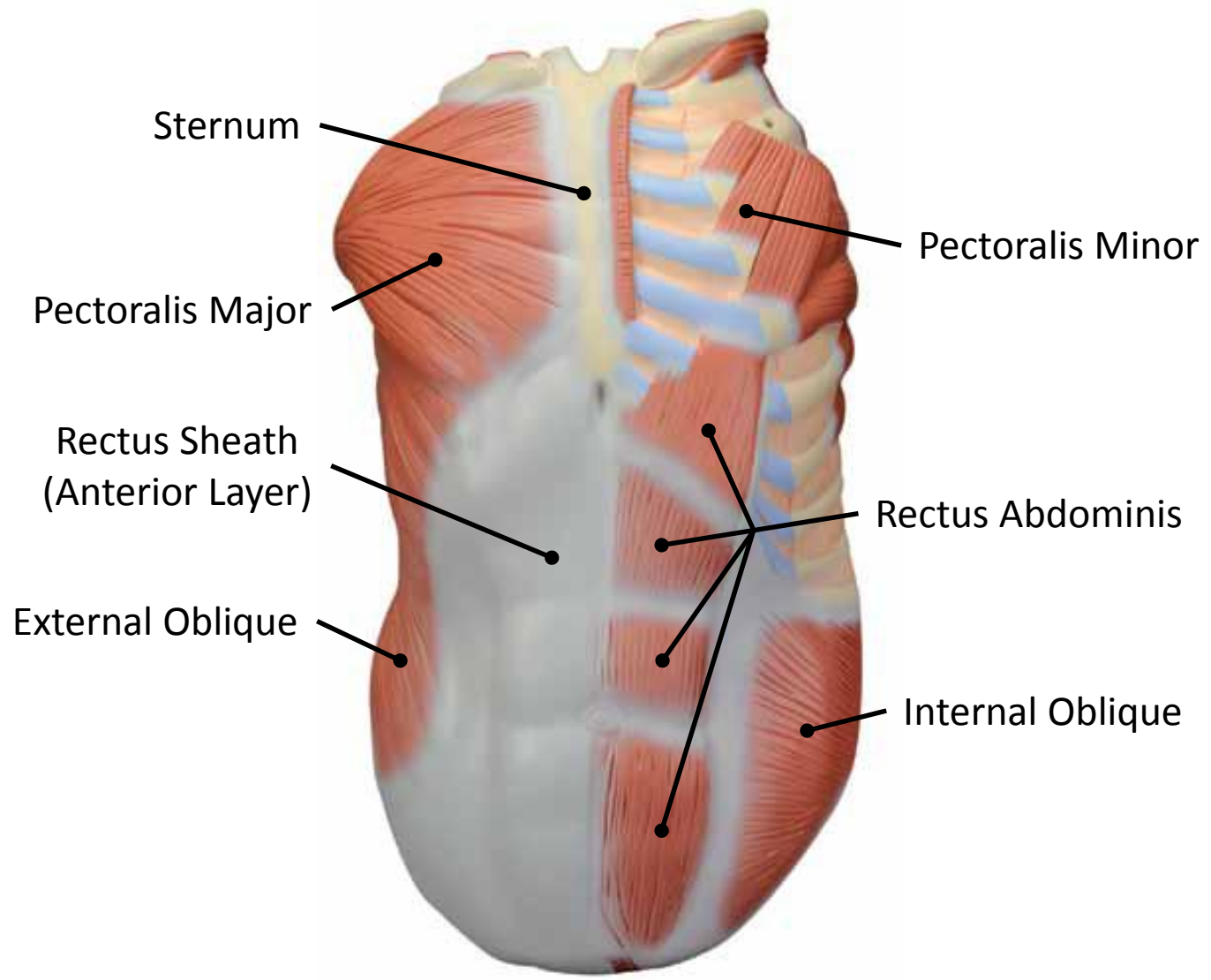
Latissimus Dorsi  
↳ superficial, cover lower part of the back.

Gluteus Medius

Gluteus Maximus







Sternum

Pectoralis Minor

Pectoralis Major

Rectus Sheath  
(Anterior Layer)

Rectus Abdominis

External Oblique

Internal Oblique