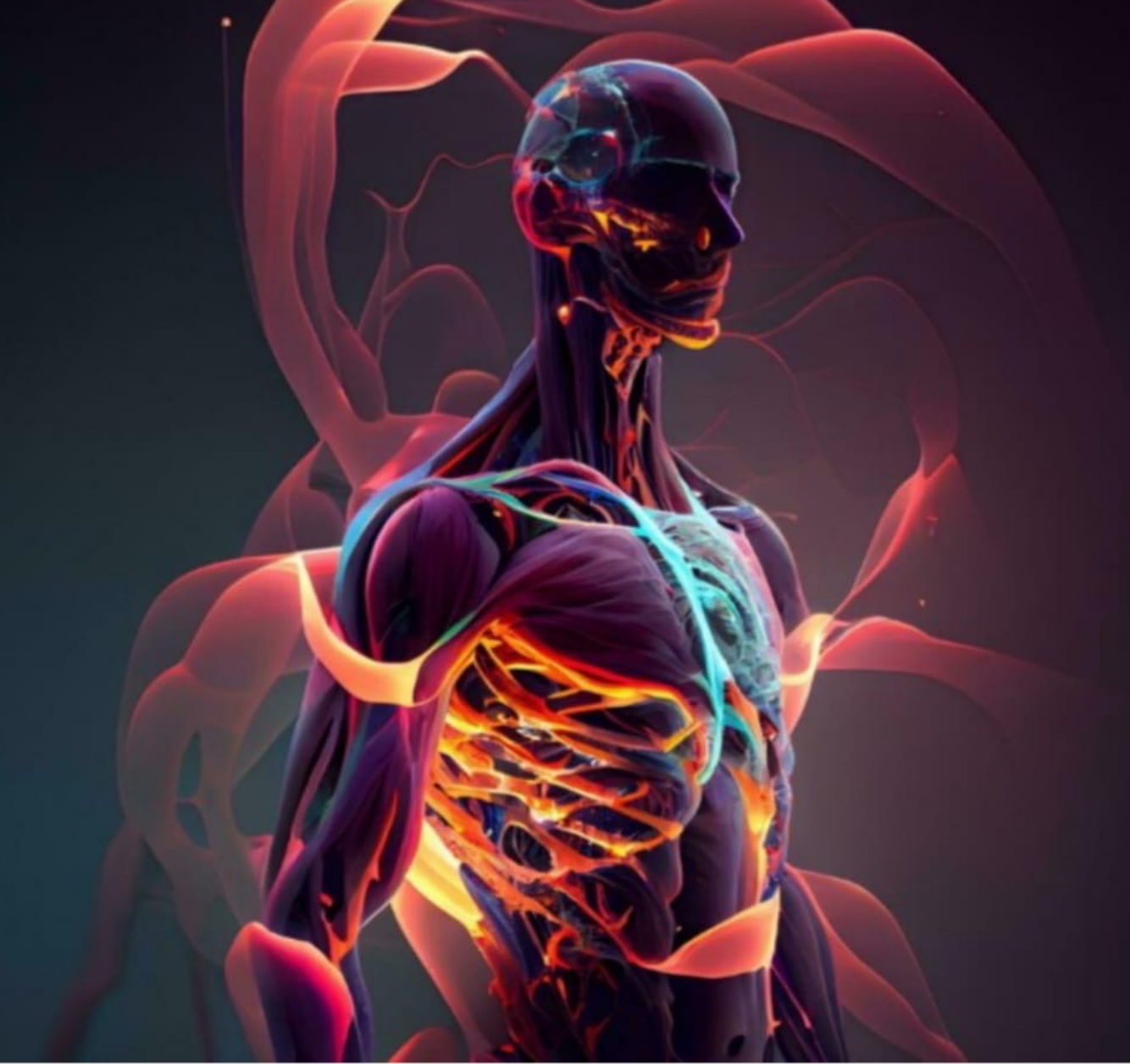



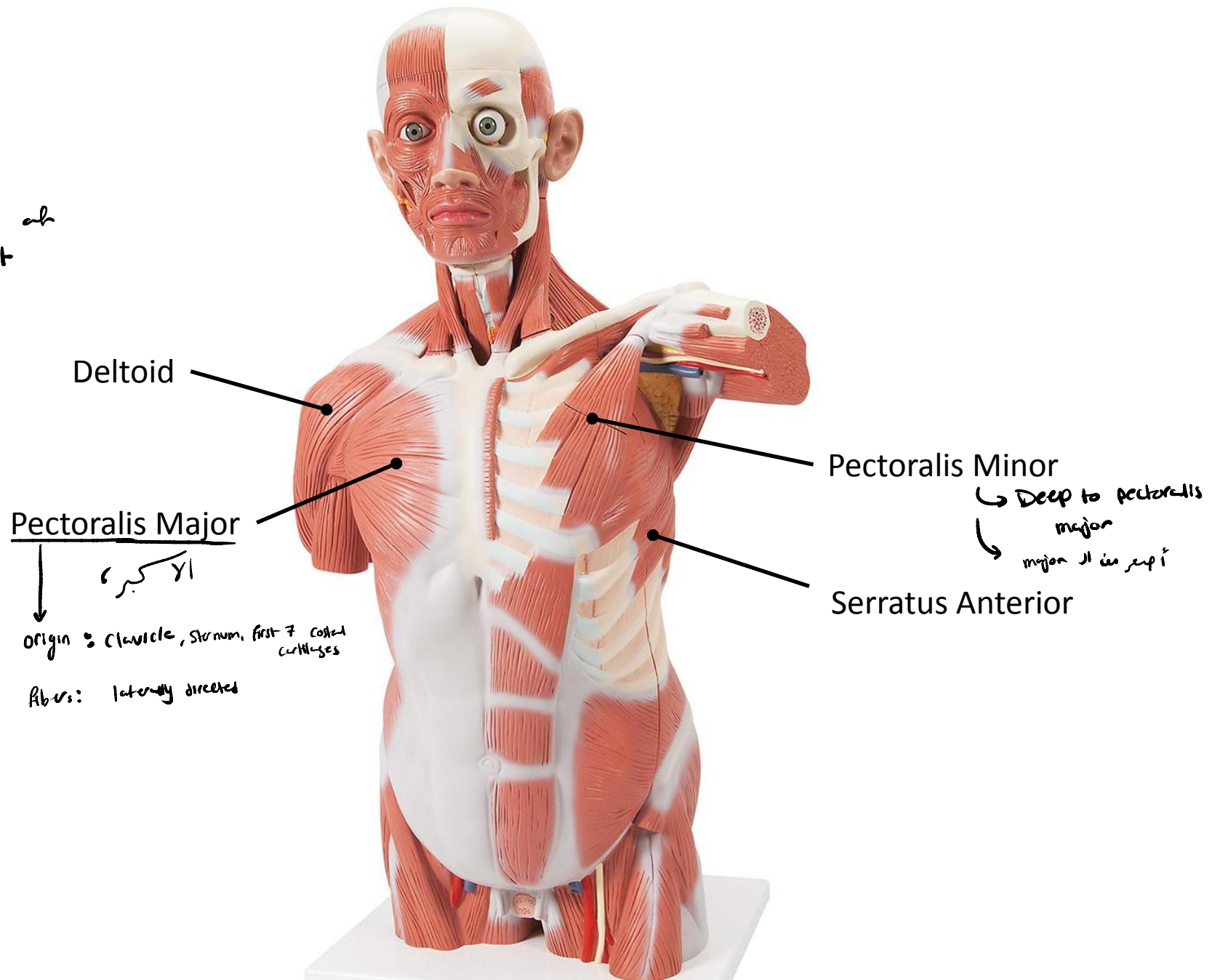
Lecture: Lab 5

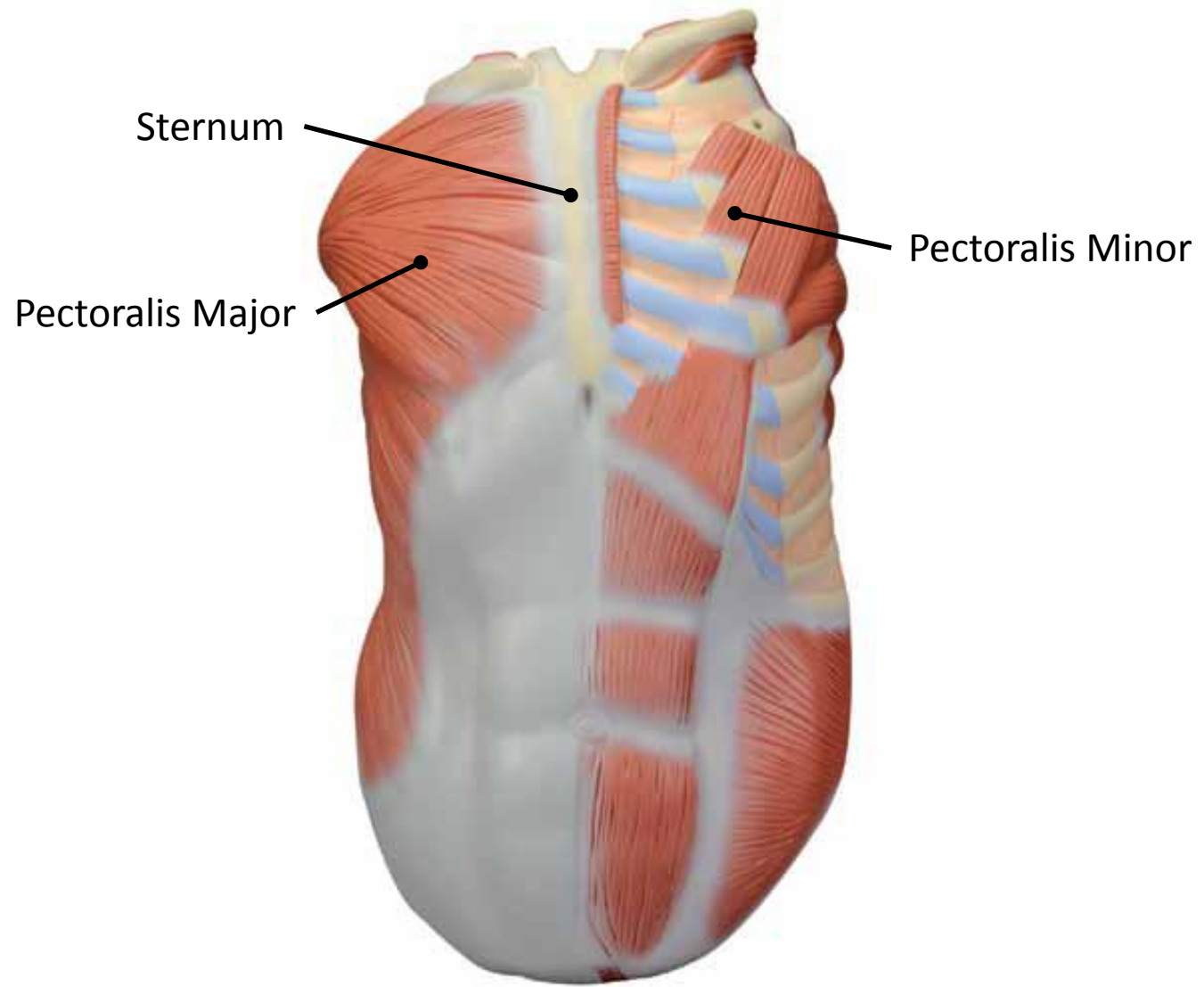
Done By: Wafaa Alkarabshah

# **Lab 5**

## **Muscles of Upper Limb**

\* Pectoral : upper part of the chest





# Back :

↳ 2 superficial

↳ 3 deep muscles

deep to trapezius  
↳ latissimus dorsi

Levator Scapulae  
Rhomboides Minor

Trapezius  
superficial

Supraspinatus

Attached to the  
Suprascapular fossa

Infraspinatus

attached to infrascapular fossa

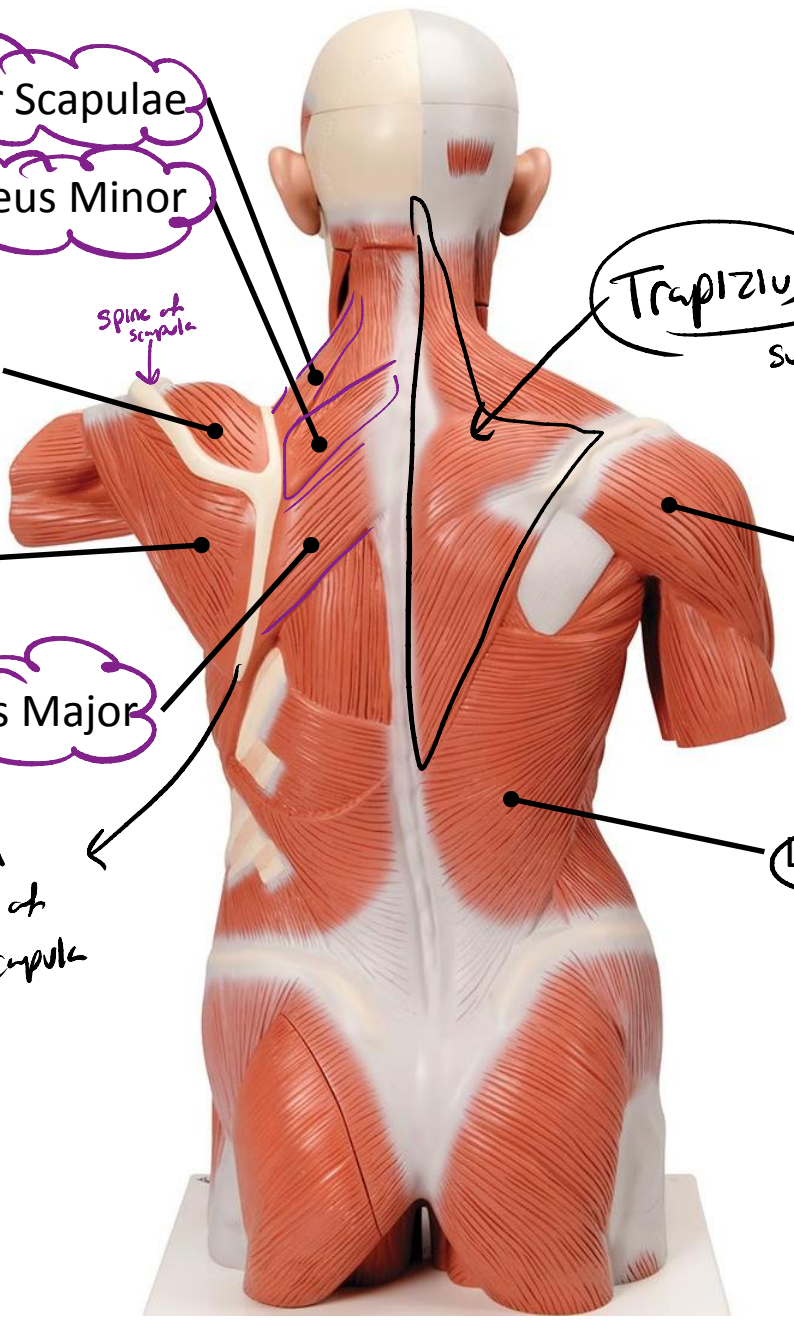
Rhomboides Major

medial  
border of  
the scapula

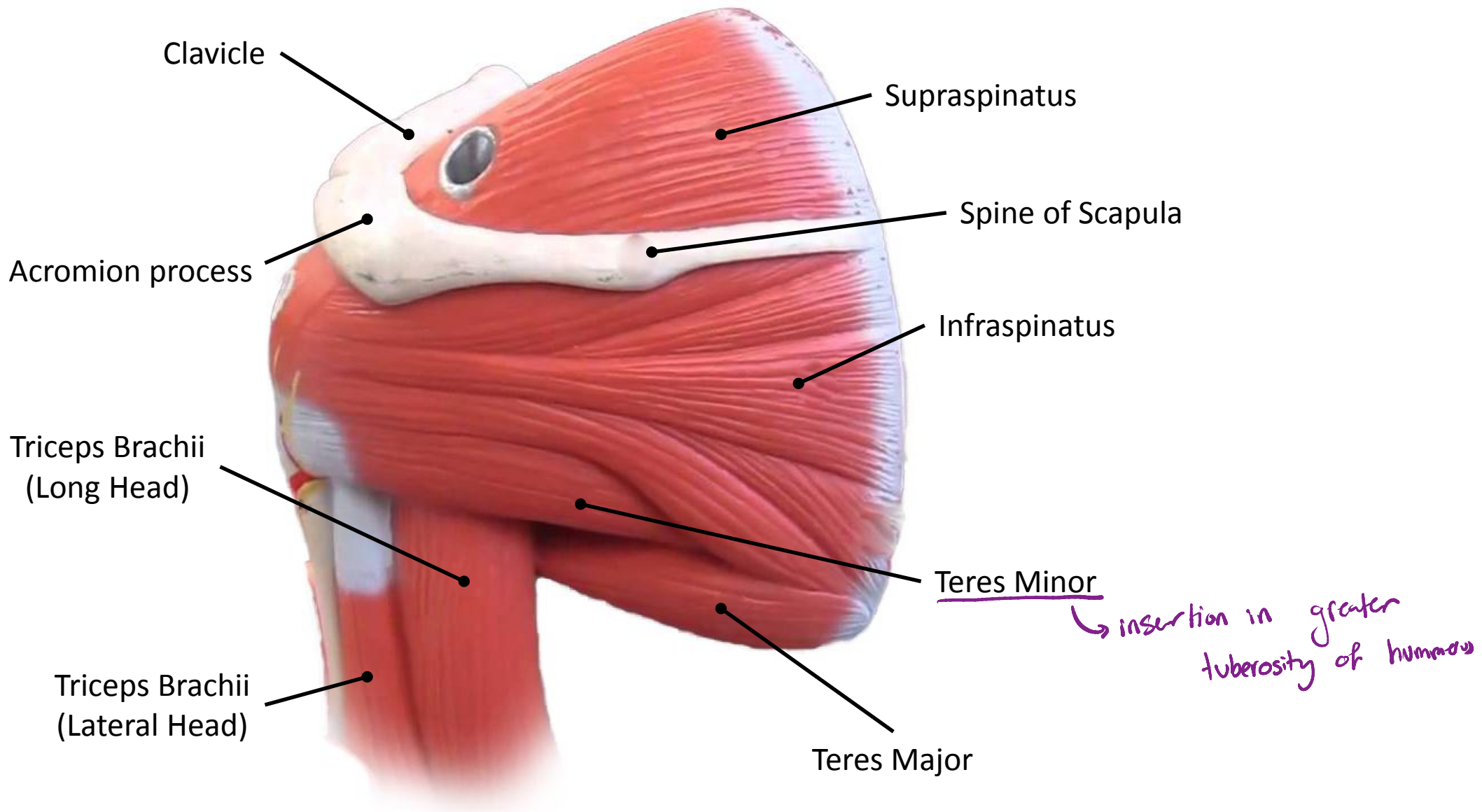
Latissimus Dorsi  
superficial

origin: clavicle, scapula, Acromion process // insertion: Deltoid tuberosity [lateral border of humerus]  
↳ Triangular in shape  
↳ responsible for the round shape of the shoulder.

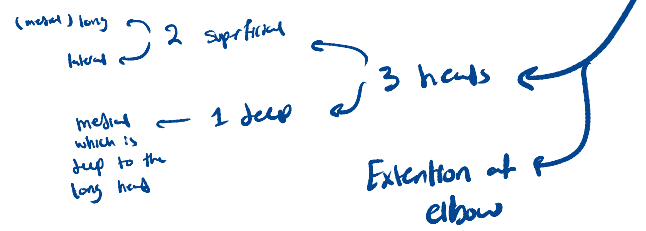
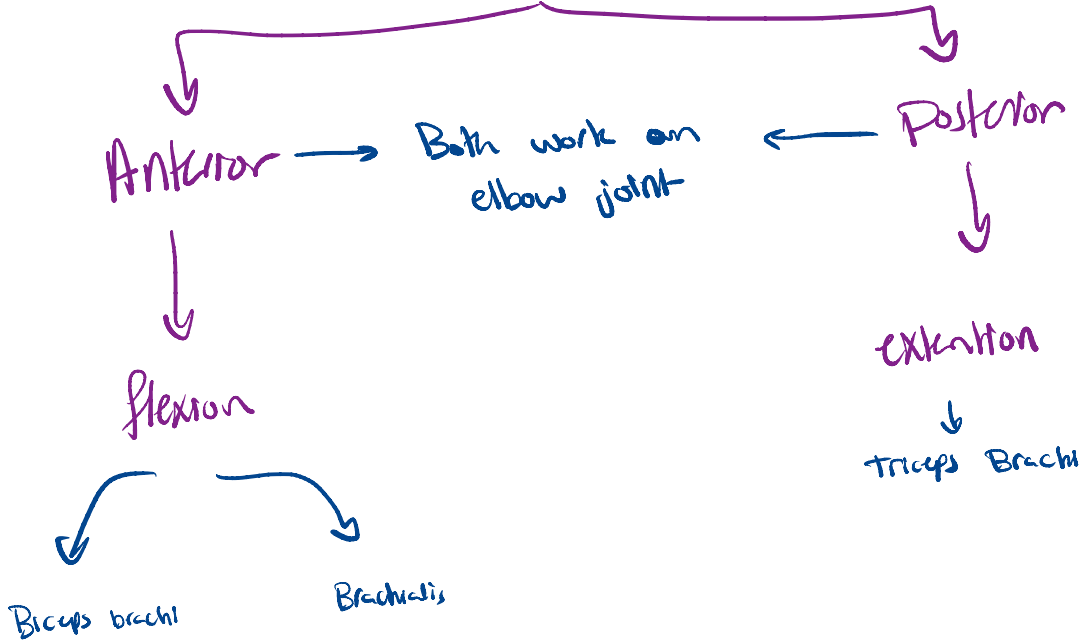
ديكون مقل فيه :  
- Rhomboides minor  
- Rhomboides major  
- Levator scapulae



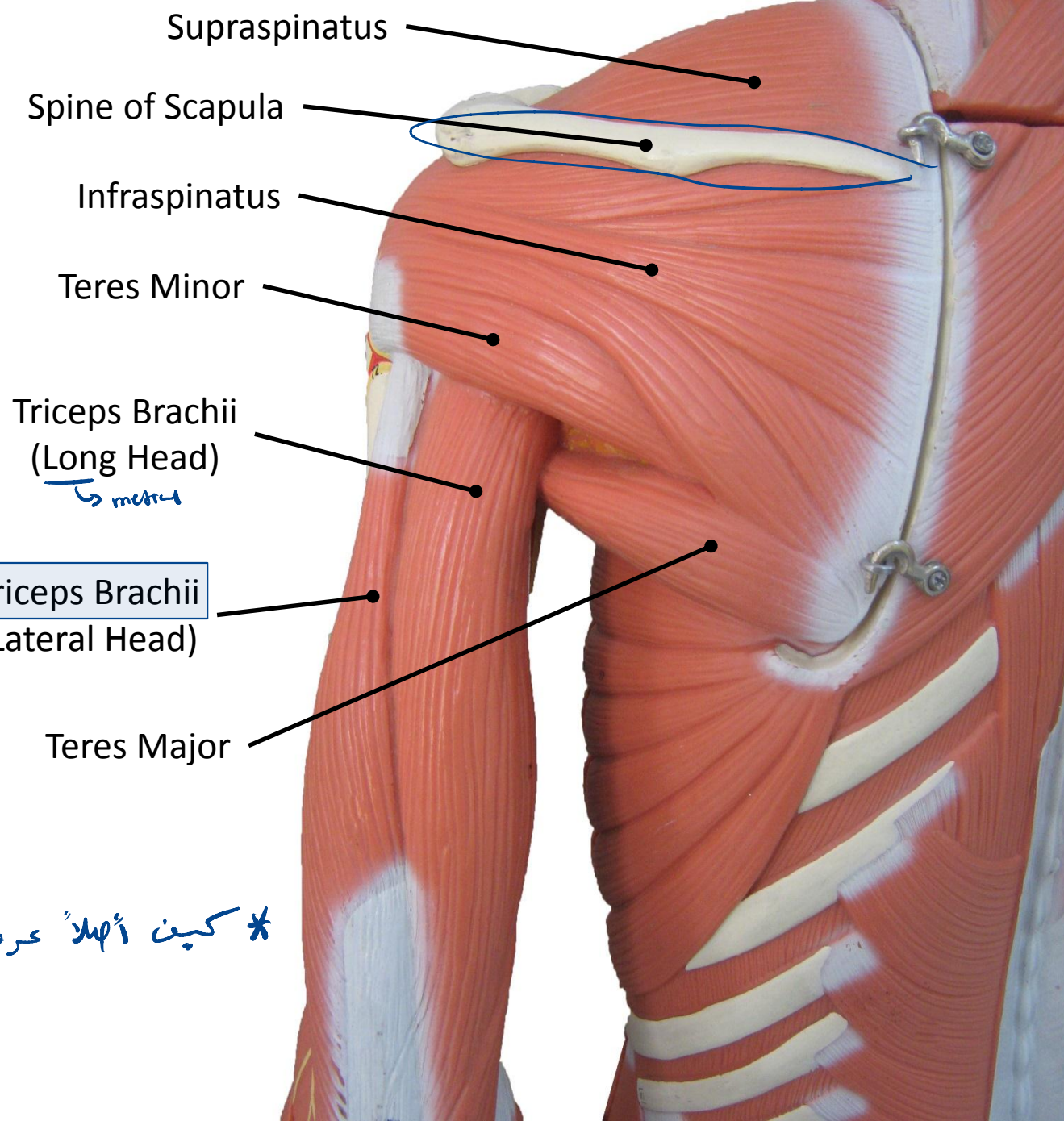




# muscles of the arm



\* کینت اہل عرفنا، انہ لار کو ال Posterior view  
 spine of the scapula



Biceps Brachii  
(Short Head)  
*medial*

Biceps Brachii  
(Long Head)  
*lateral*

→ insertion: proximal end of radius

Subscapularis

Coracobrachialis

↳ medial  
↳ has the same origin as the short head of Biceps brachii.

↳ flex arm at elbow  
↳ insertion: middle of the medial border of the humerus

Brachialis

↓  
Deep to biceps  
↳ insertion: proximal end of ulna

Biceps Brachii

Brachioradialis

Pronator Teres

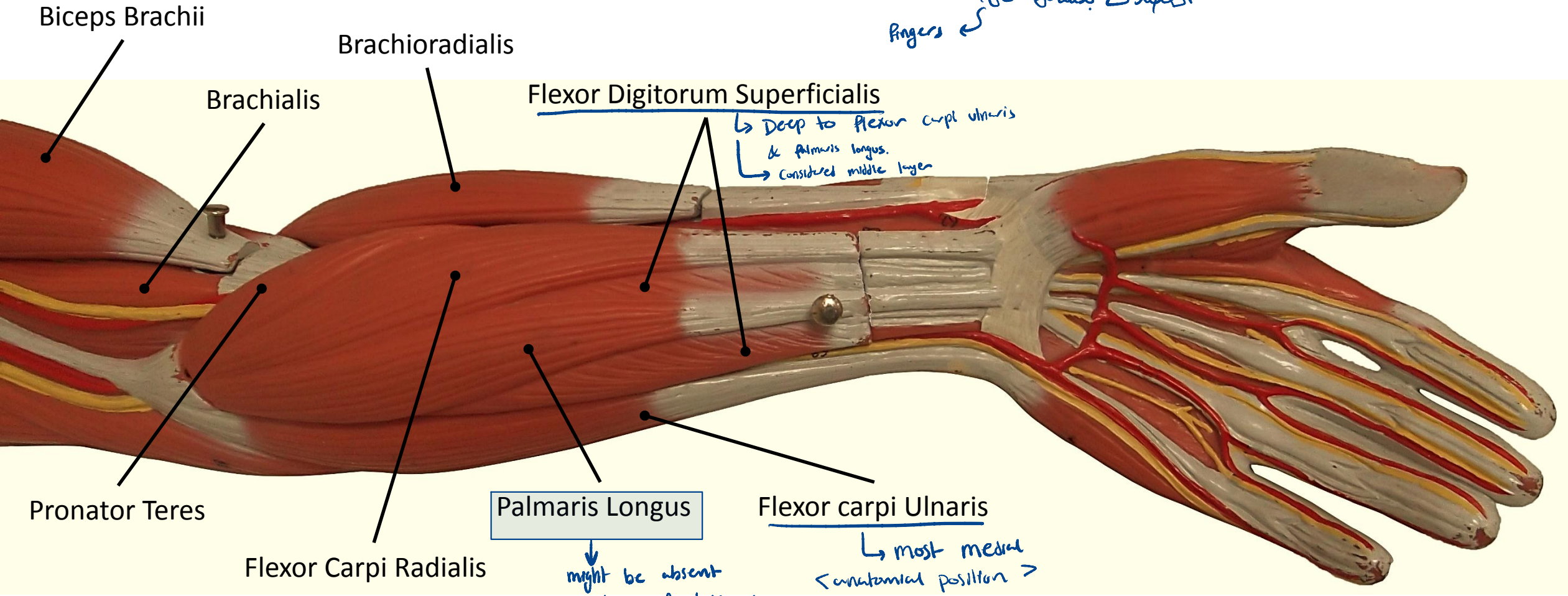


\* حتى تغادر تشتغل العظمة على  
ال joint elbow لازم تكون عدت  
مسان لكليك بنادحلا او Brachialis + Biceps brachii  
بنا ! انه بصلو flexion او extension فنج يكون  
اد insertion تبعهم ليس في ال elbow ؛ انما جده  
في ال proximal end اما ال ulna او ال radius .



# Forearm :

Wrist → *كشافة*  
 Fingers → *أصابع*



\* Anterior view of the forearm,  
 palm of the hand ↓ *كشافة*

→ flexion ← Anterior muscles ↓ *كشافة*

\* Carpi ⇒ related to carpal bones  
 \* digitorum ⇒ All fingers except thumb  
 \* profundus ⇒ Deep

Dorsal aspect of forearm:  
(posterior side)

extension of  
wrist

Extensor carpi Radialis Longus

Extensor carpi Radialis Brevis

Brachioradialis

هو العضو  
الذي يمتد  
من الكتف الى  
الساعد

Extensor Digitorum

Extensor Carpi Ulnaris

Extensor Digiti Minimi

extension of little finger

Anconeus

هو العضو الطبيعى  
الذي يمتد من الكتف الى  
الساعد

Triceps Brachii

