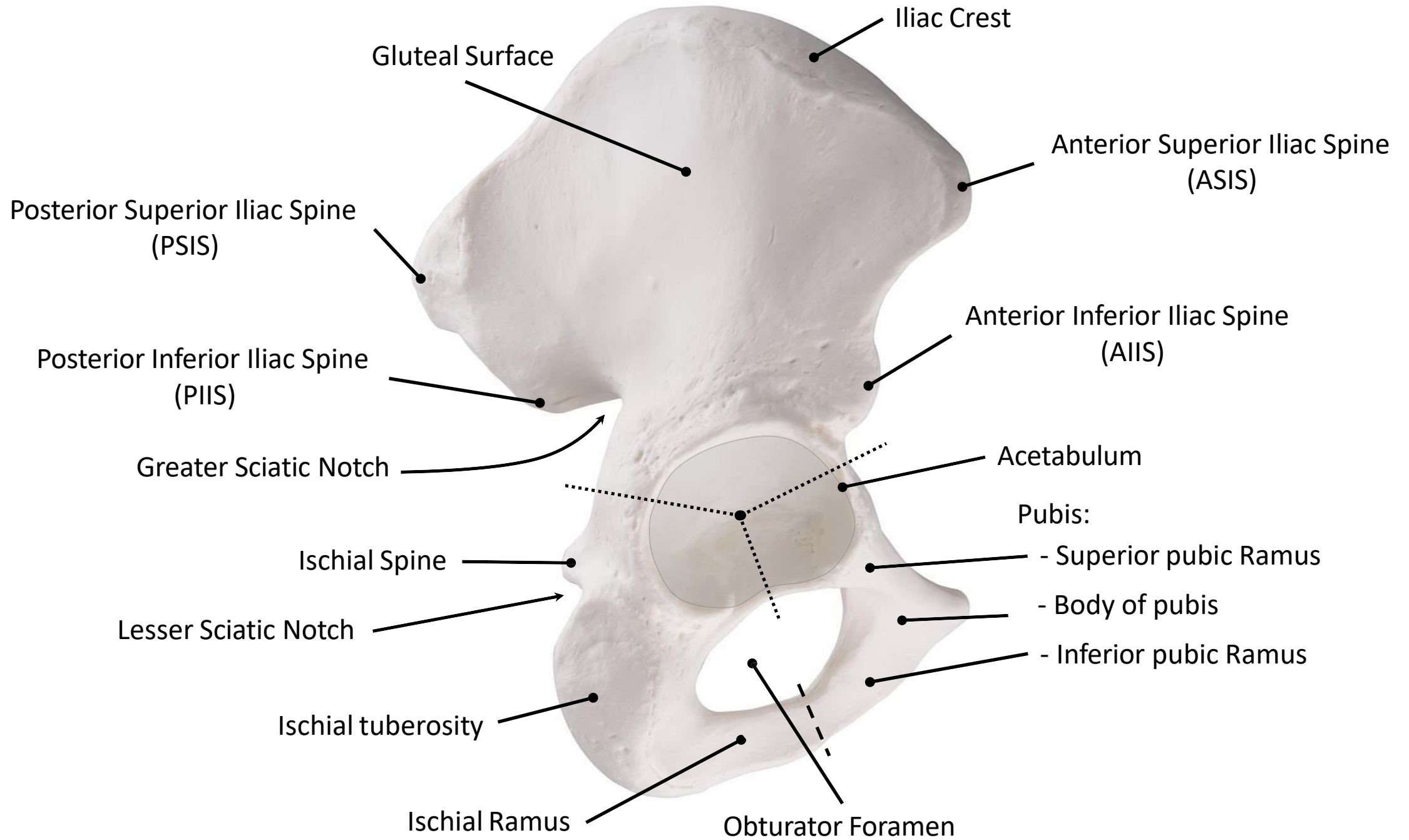
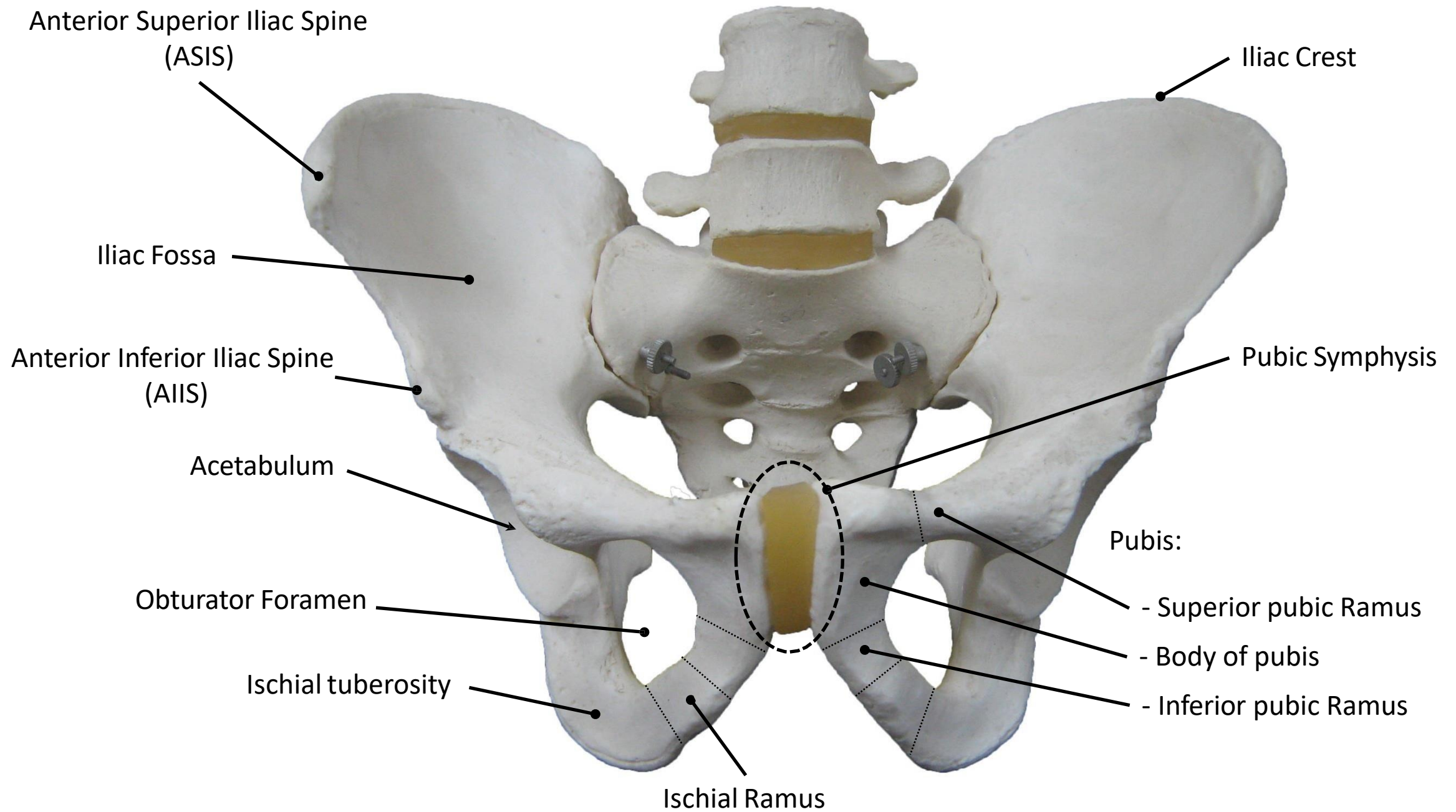
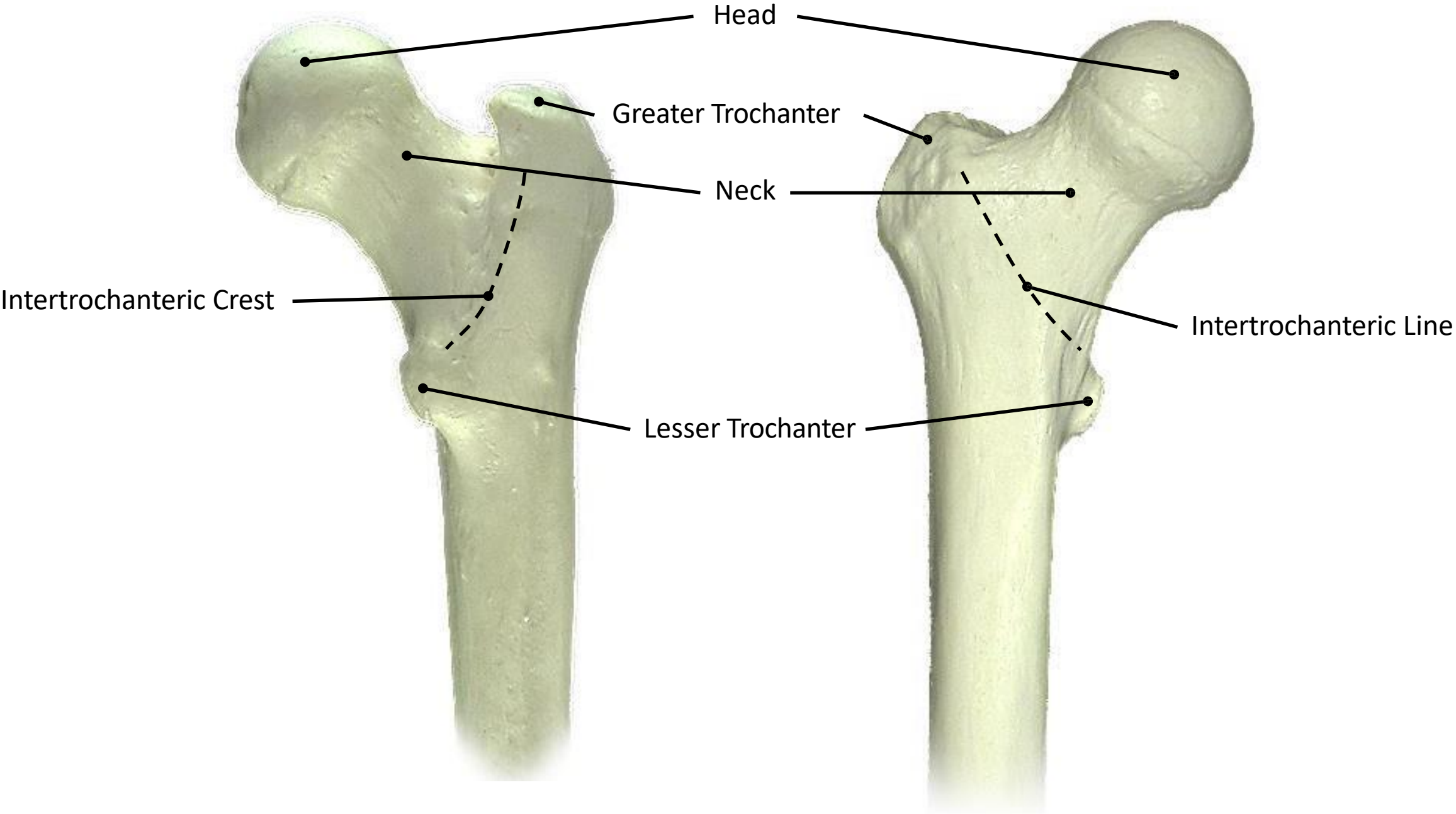


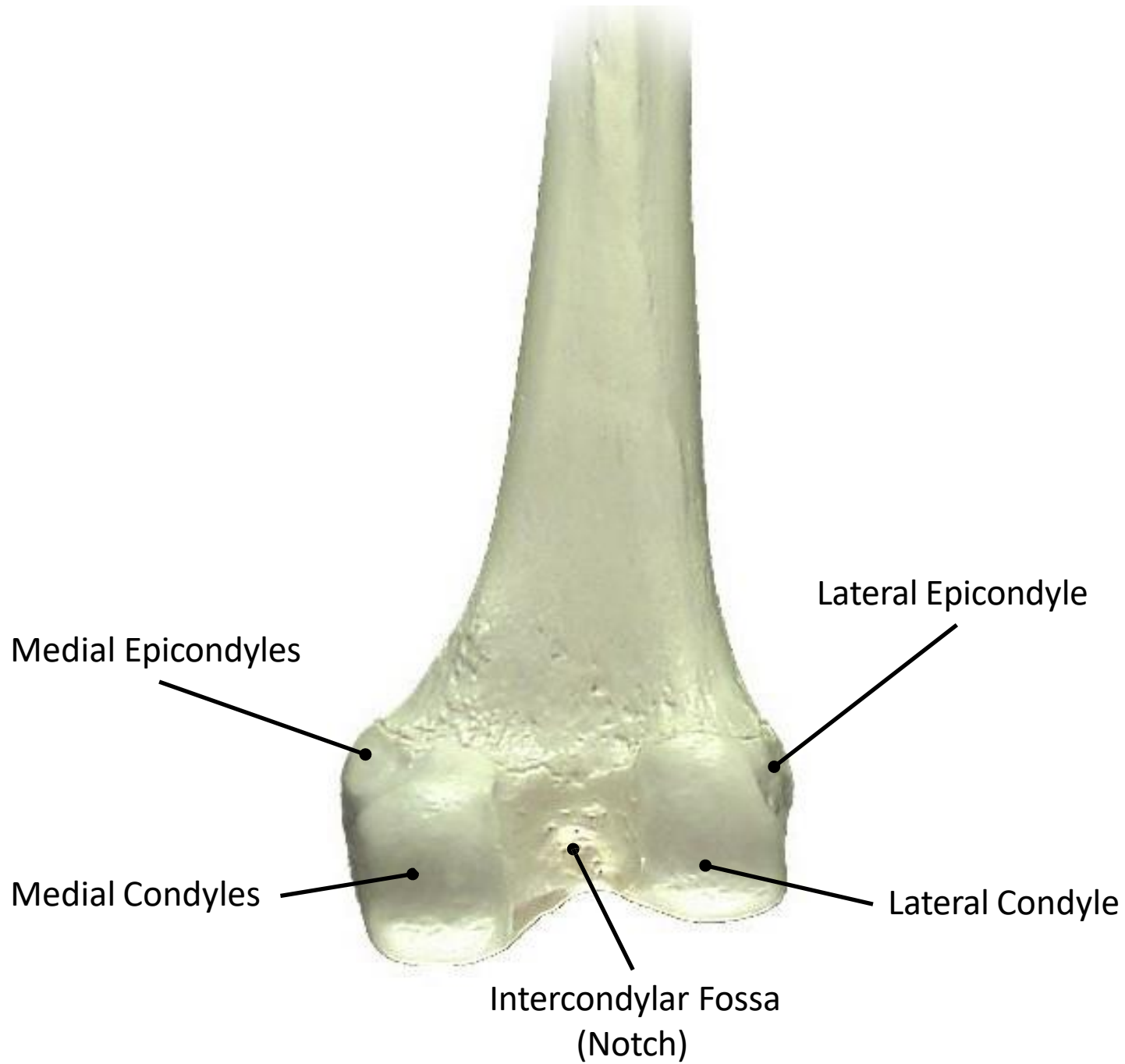
Lab 4

Bones of Lower Limb



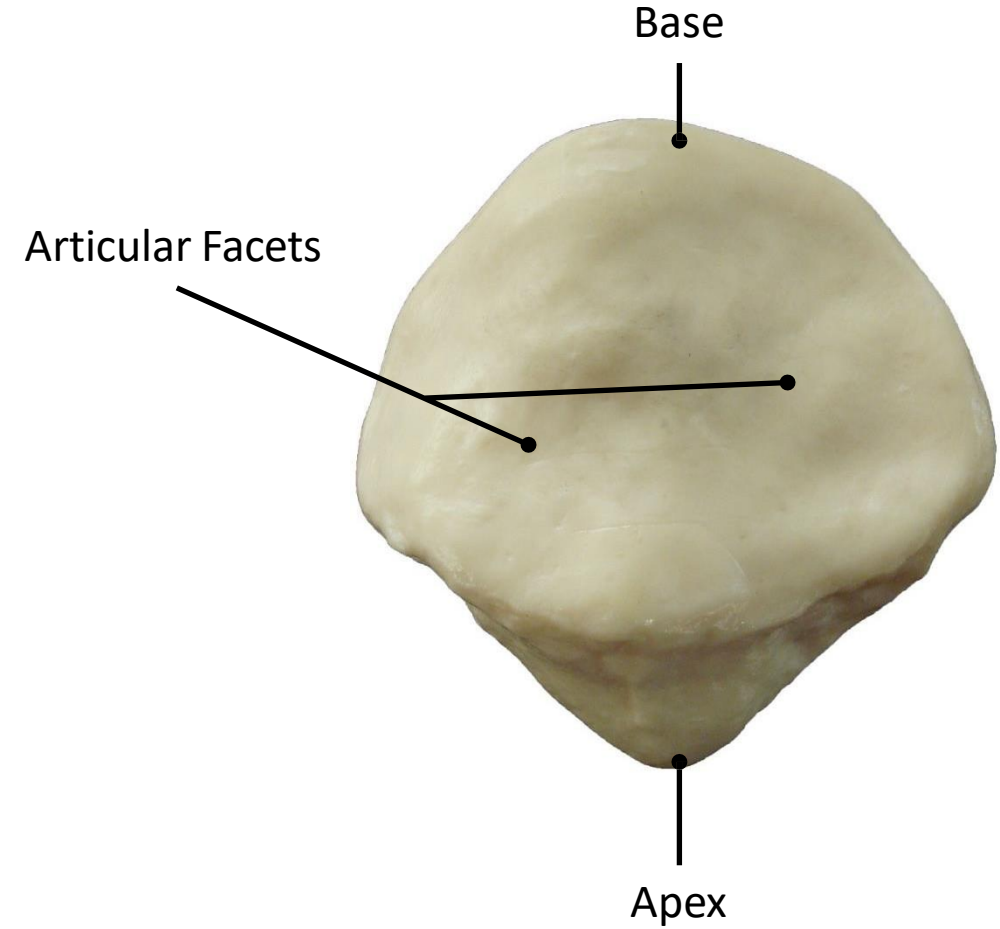




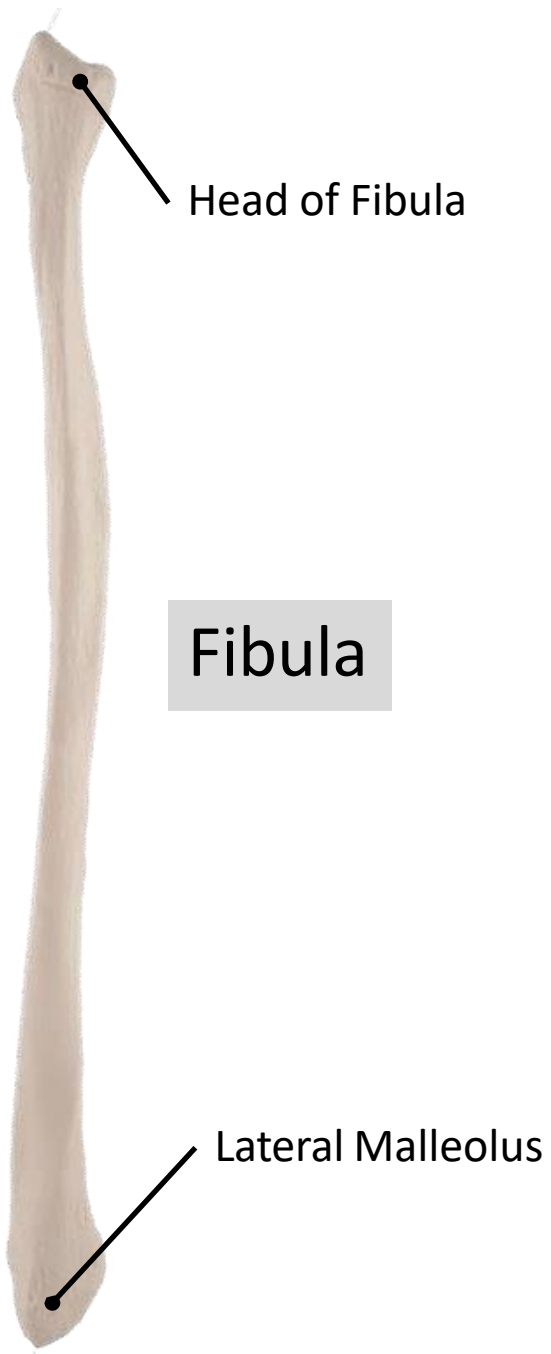




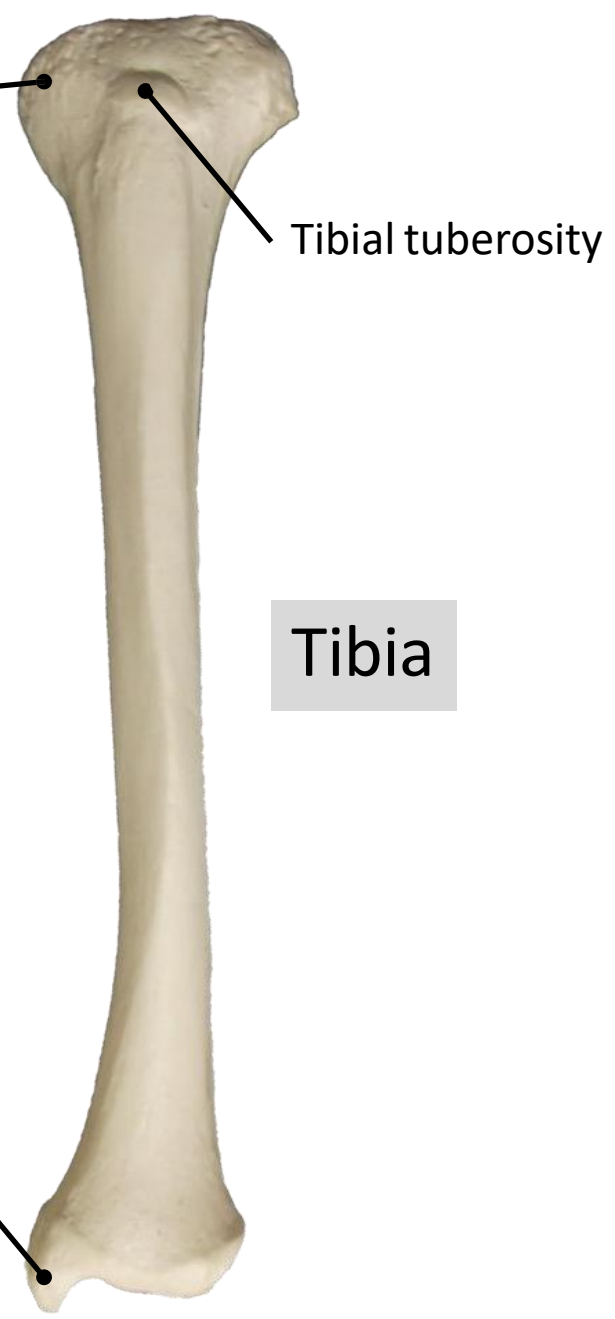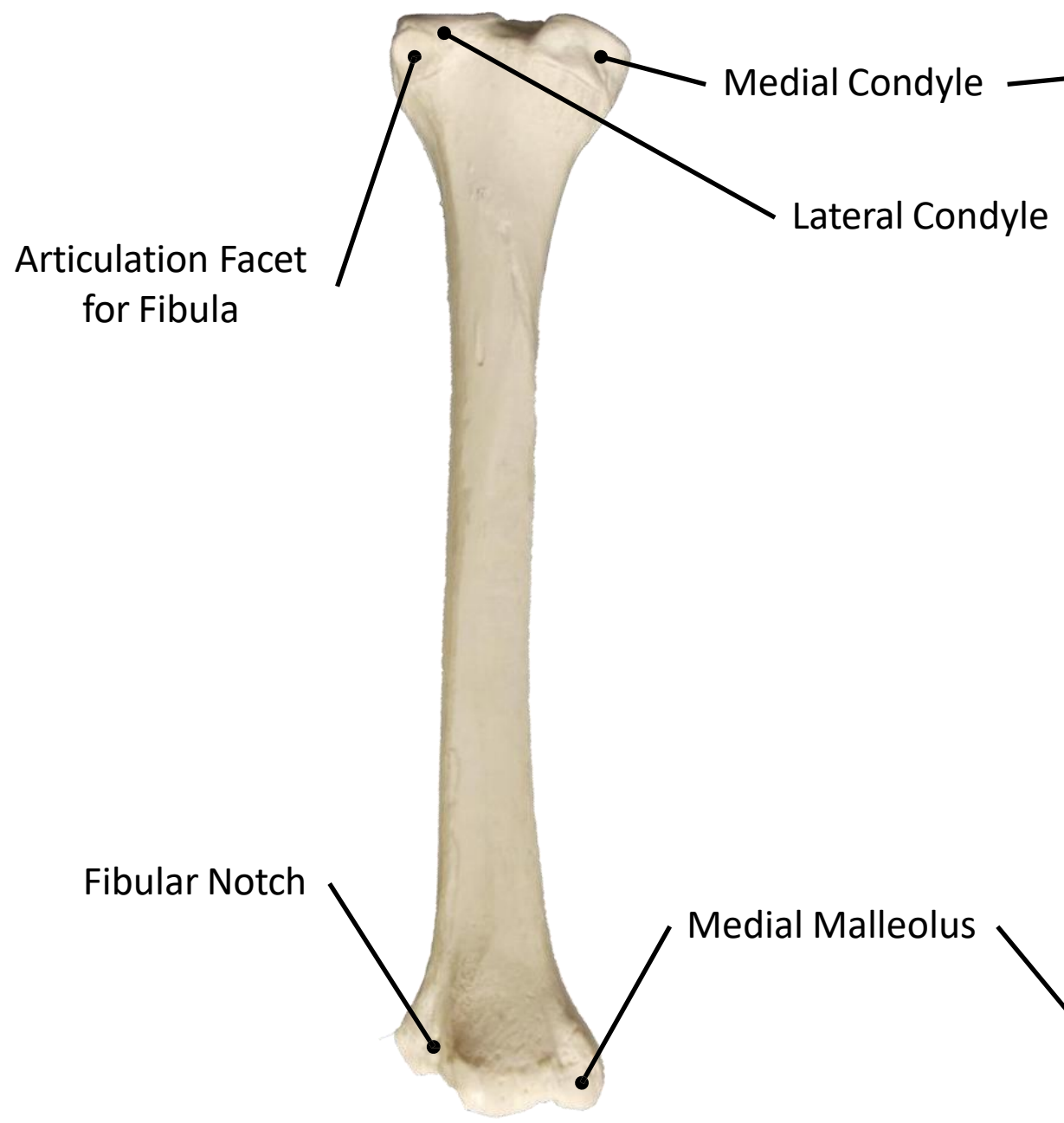
Patella
(Anterior Surface)



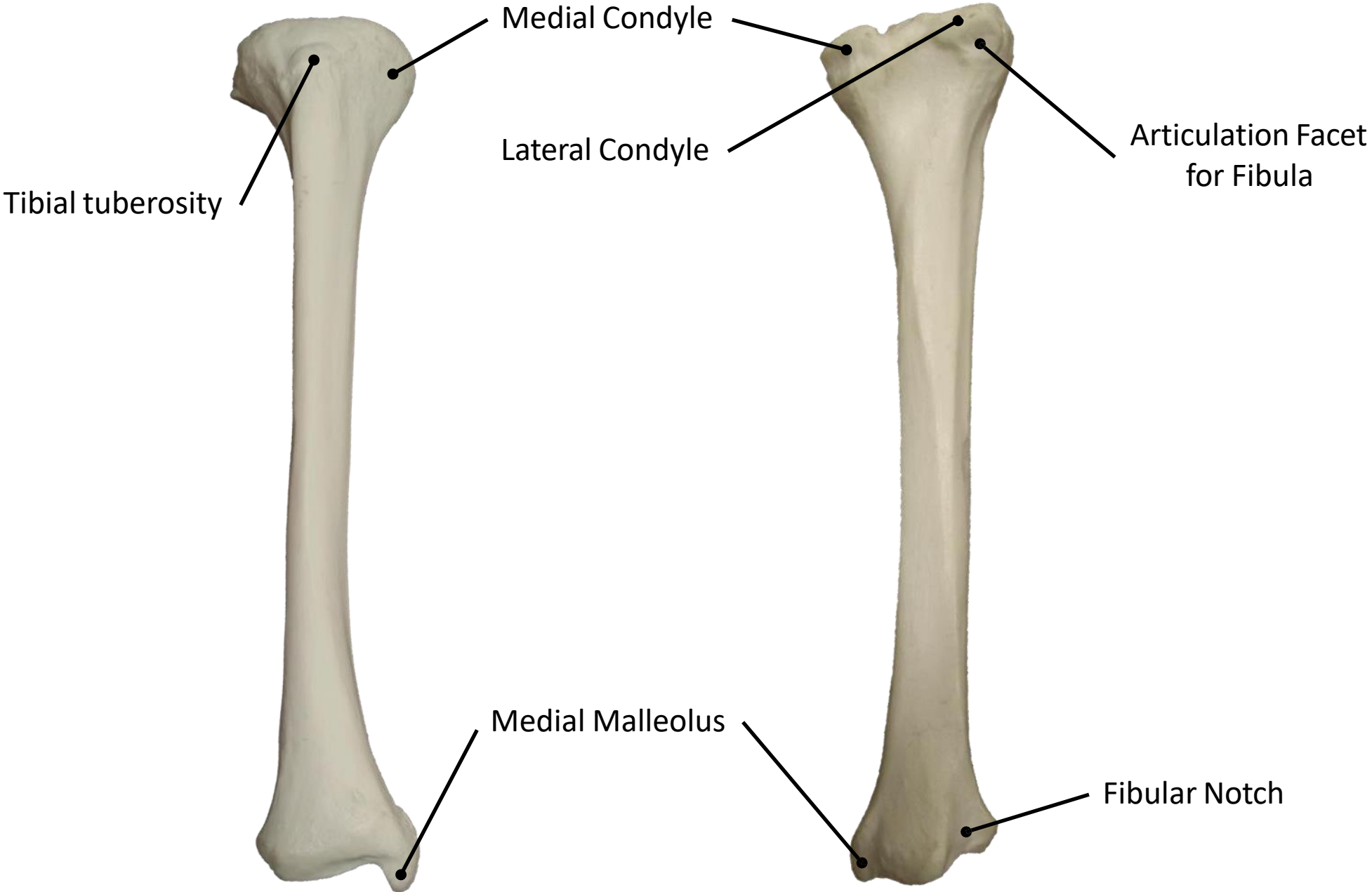
Patella
(Posterior Surface)

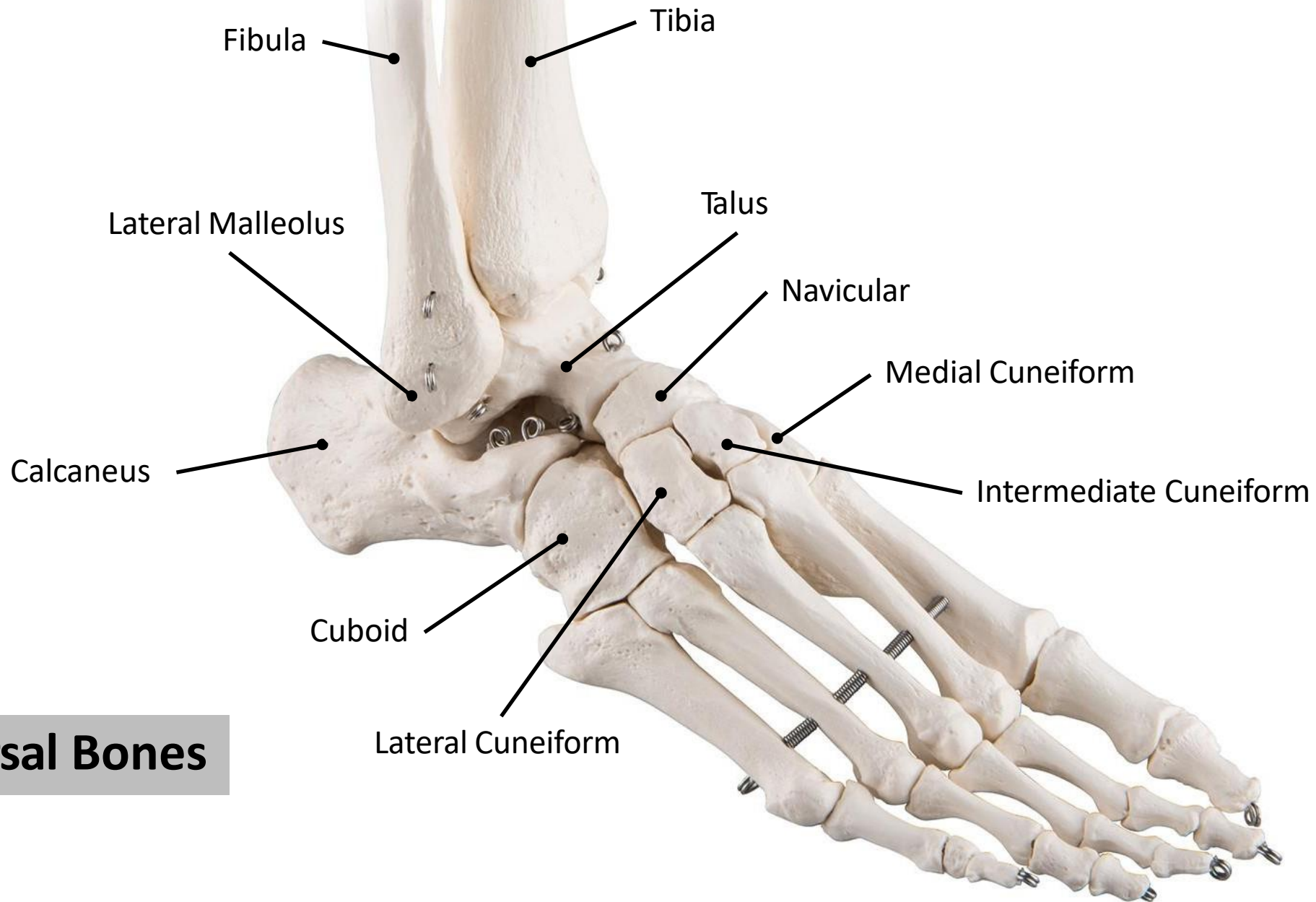


Fibula



Tibia





Tarsal Bones

Metatarsal Bones:

- Base (Proximal)

- Shaft

- Head (Distal)

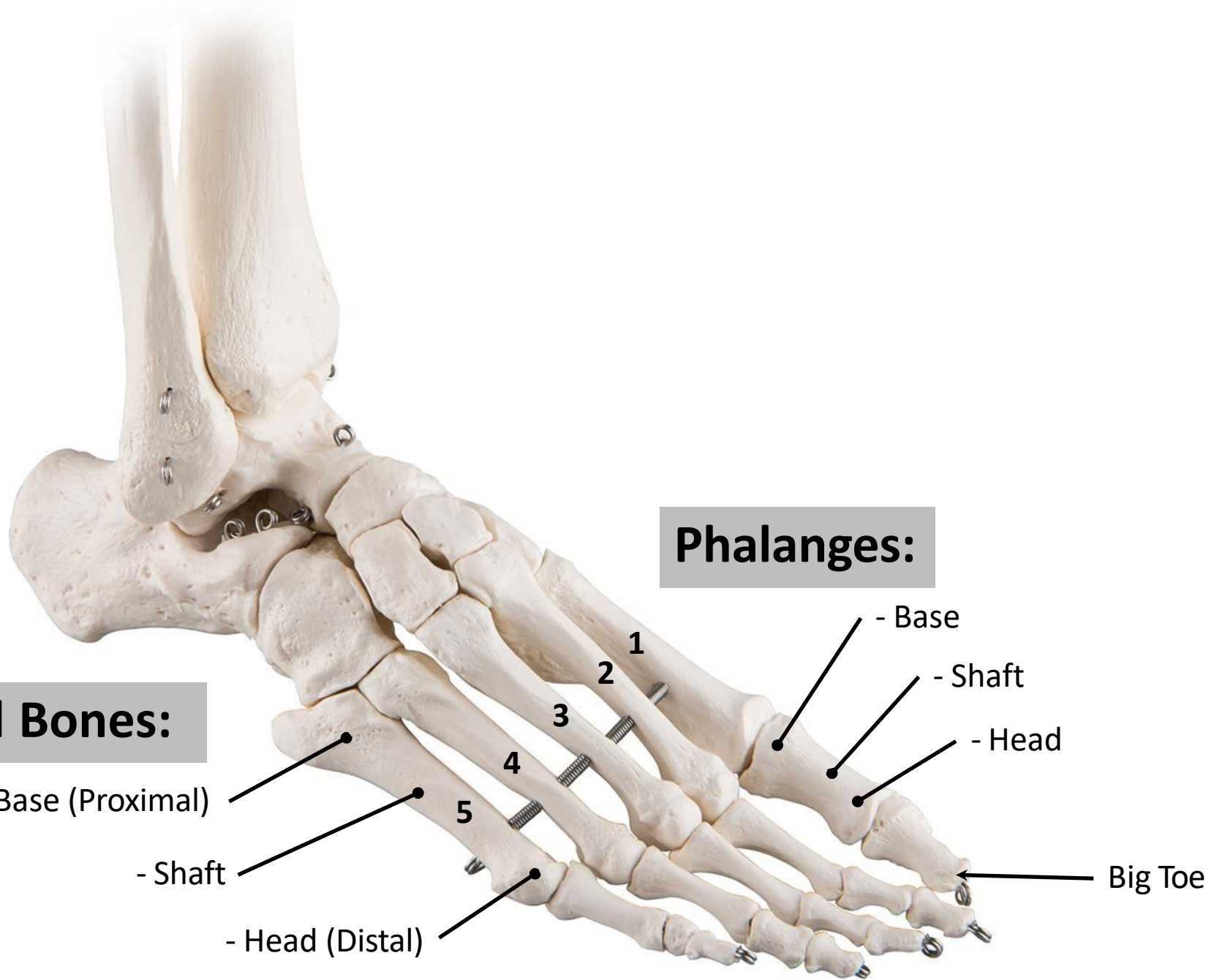
Phalanges:

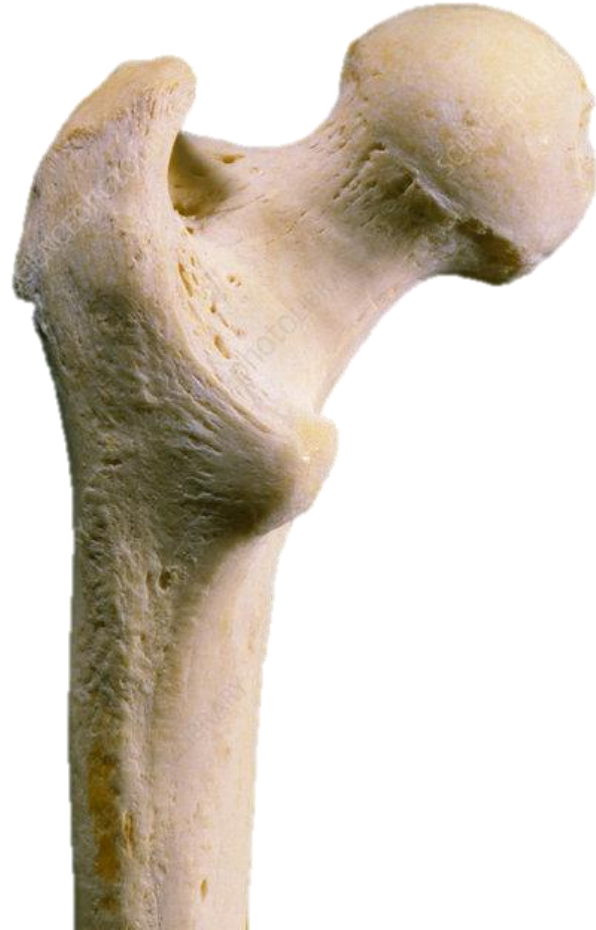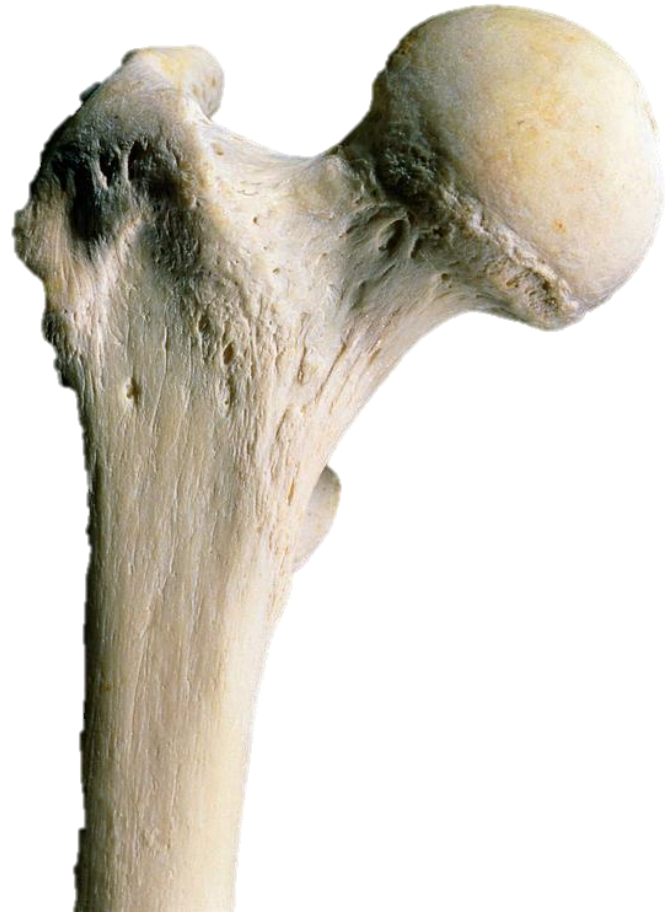- Base

- Shaft

- Head

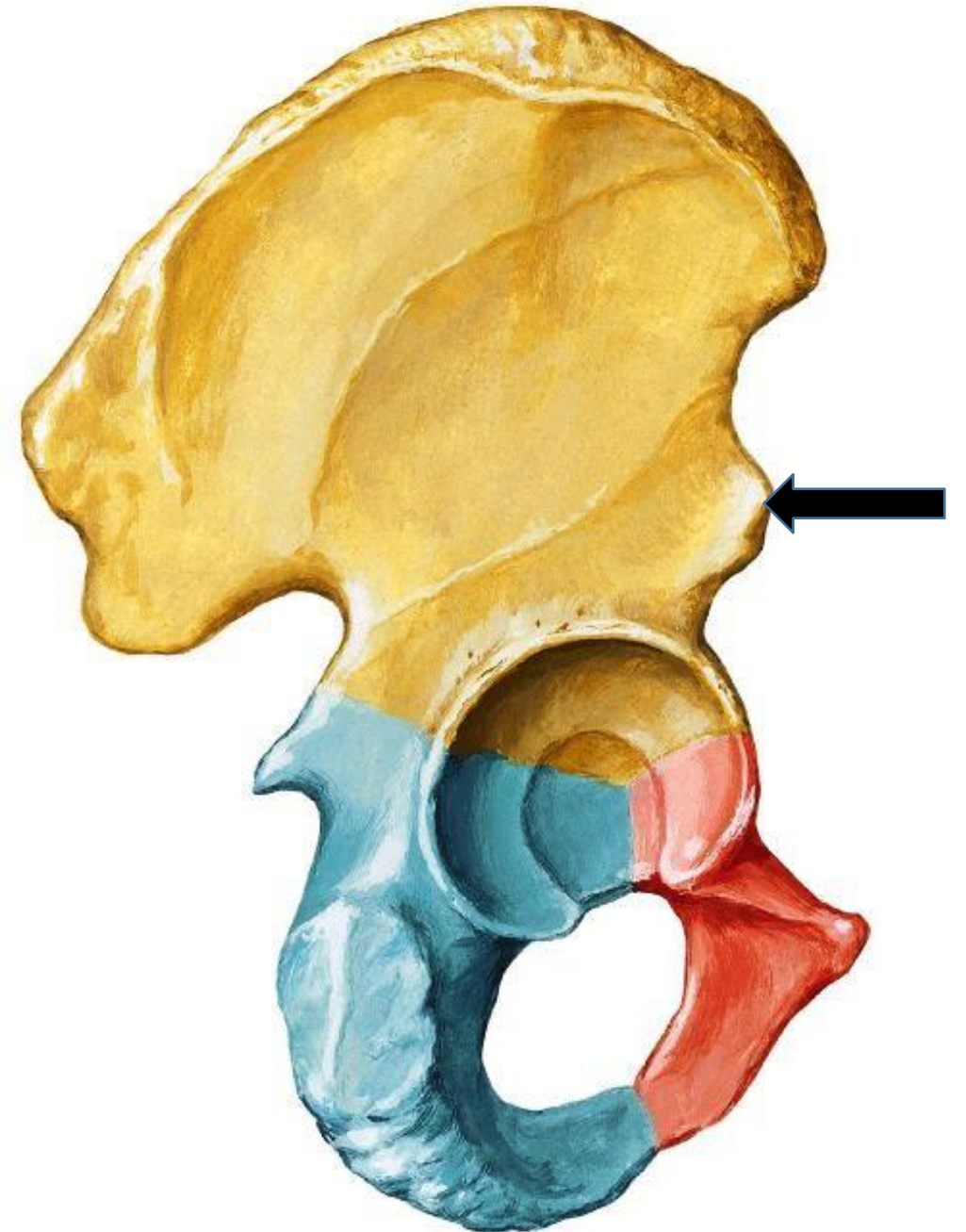
Big Toe





Questions of Lab 2

- 1. The marked structure is:**
- a. Anterior superior iliac spine.**
 - b. Anterior inferior iliac spine.**
 - c. Ischial spine.**
 - d. Posterior superior iliac spine.**
 - e. Posterior inferior iliac spine.**



- 2. The marked structure is:**
- a. Lesser trochanter.**
 - b. Greater trochanter.**
 - c. Head.**
 - d. Neck.**
 - e. Intertrochanteric line.**



- 3. The marked structure is:**
- a. Intertrochanteric line.**
 - b. Intertrochanteric crest.**
 - c. Intercondylar fossa.**
 - d. Medial condyle.**
 - e. Lateral condyle.**



4. The marked structure is:

- a. Tibial tuberosity.**
- b. Lateral malleolus.**
- c. Medial malleolus.**
- d. Medial condyle.**
- e. Lateral condyle.**



5. The marked structure is:

- a. Navicular.**
- b. Cuboid.**
- c. Lateral cuneiform.**
- d. Intermediate cuneiform.**
- e. Medial cuneiform.**

