



GENITOURINARY SYSTEM

SUBJECT : Anatomy Lab

LEC NO. : One

DONE BY : Batool ALzubaidi

وَقُلْ رَبِّ زِدْنِي عِلْمًا

GUS

Lab (1)

Anatomy of Urinary System

* Level of right kidney (rib 12) is lower than level of left kidney (rib 11+12) that's because of liver → **حوم**

1- Left kidney.

2- Left gonadal vessels → Artery + vein

3- Left vas deferens. - Male » testicular, female » ovarian

4- Urinary bladder.

5- Right external iliac vessels.

6- Right Psoas major muscle.

7- Right ureter.

8- Right renal vessels.

لما ال ureter يعمل crossing لل

9- Left suprarenal gland. common iliac artery بنقسم ل

external and internal iliac arteries

10- Spleen.

11- Diaphragm.

Inferior vena cava

Aorta

Common iliac artery

Left ureter

ال gonadal

vessels ماشيين

على psoas

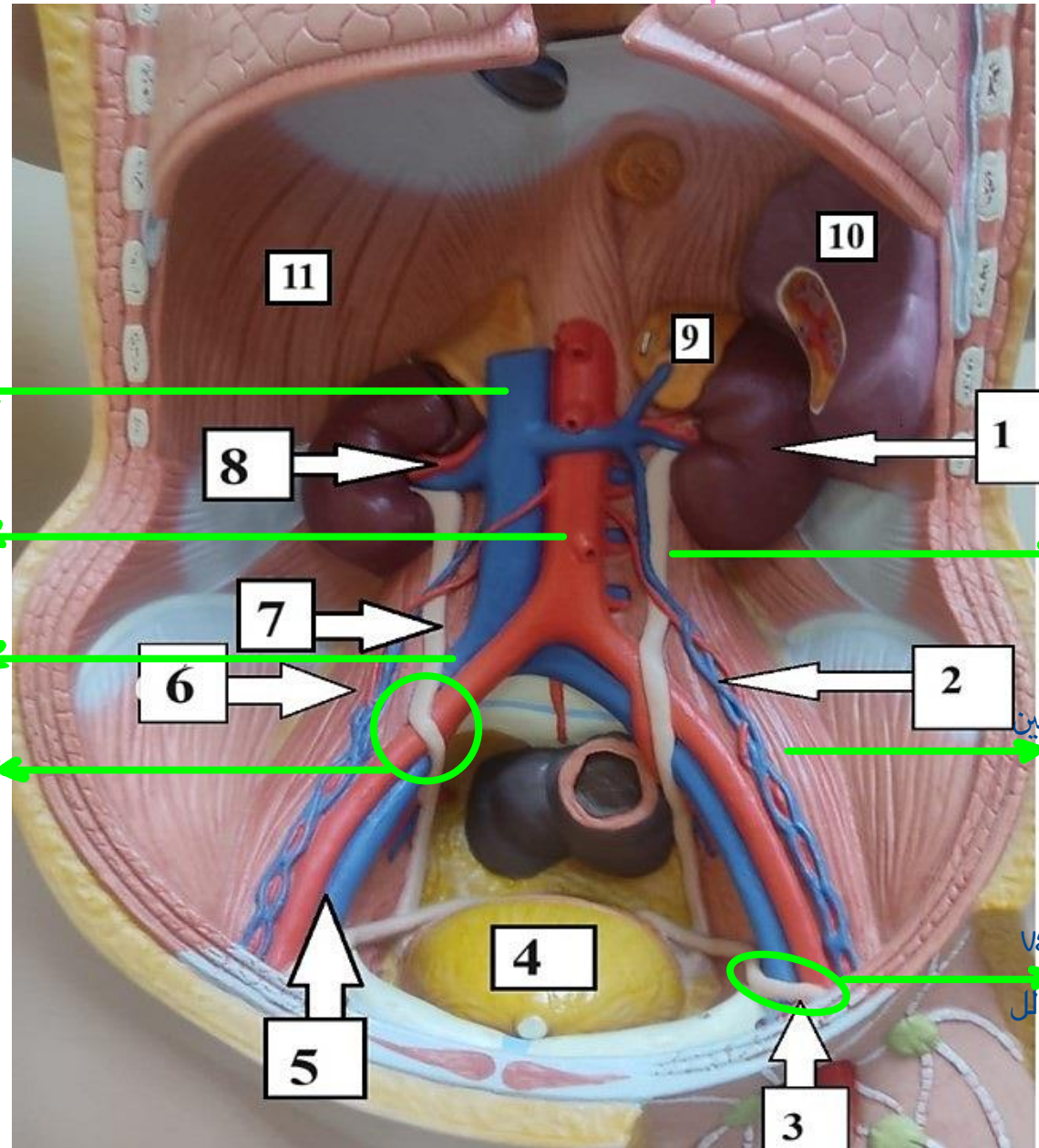
major muscle

ال vas deferense

بعمل crossing لل

external iliac

artery



Anterior relation of kidney

Suprarenal impression
1- Suprarenal area.

2- Hepatic area.

3- Duodenal area.

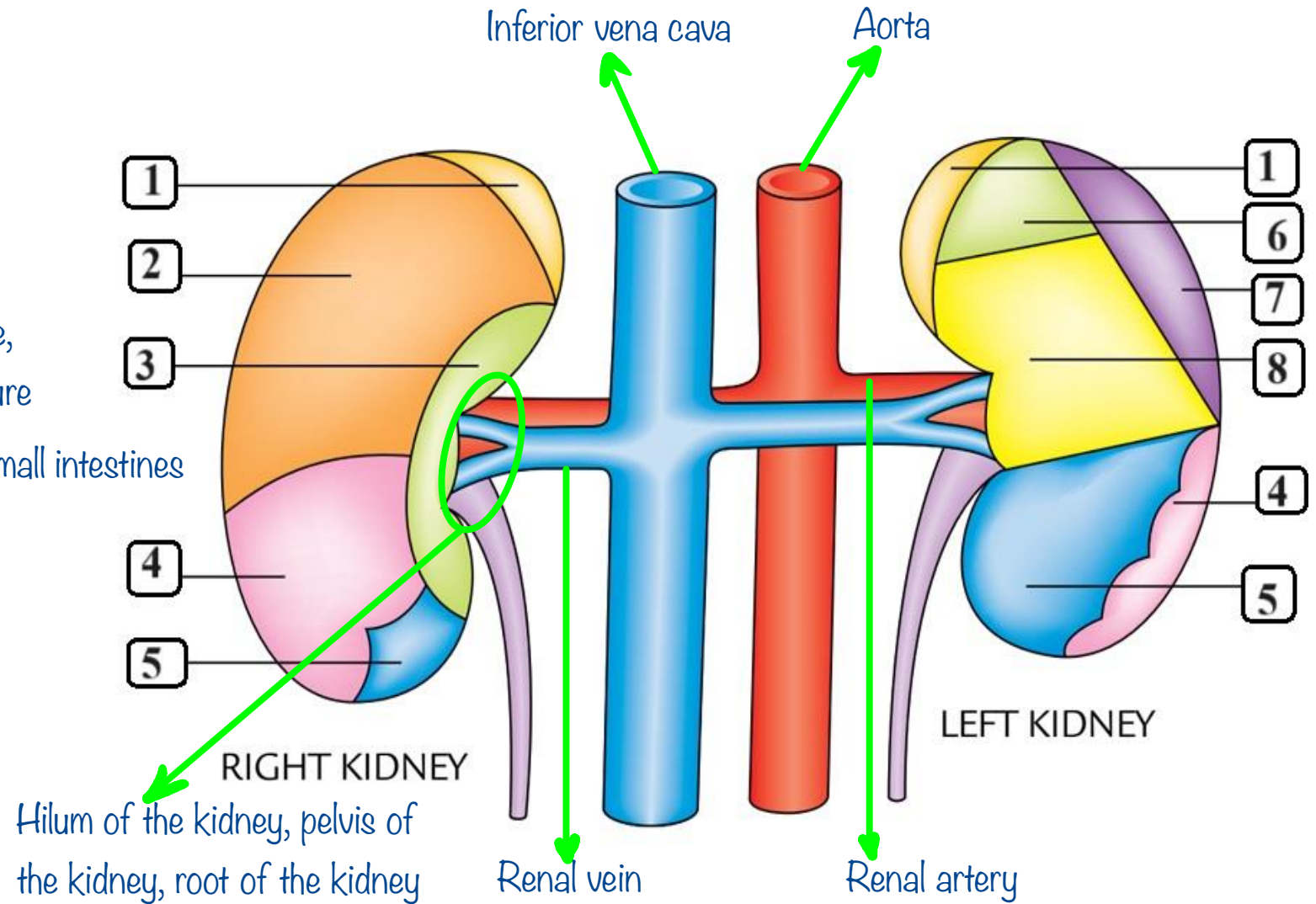
4- Colic area. Hepatic flexure,
right colic flexure

5- Jejunal area. Coils of small intestines

6- Gastric area.

7- Splenic area.

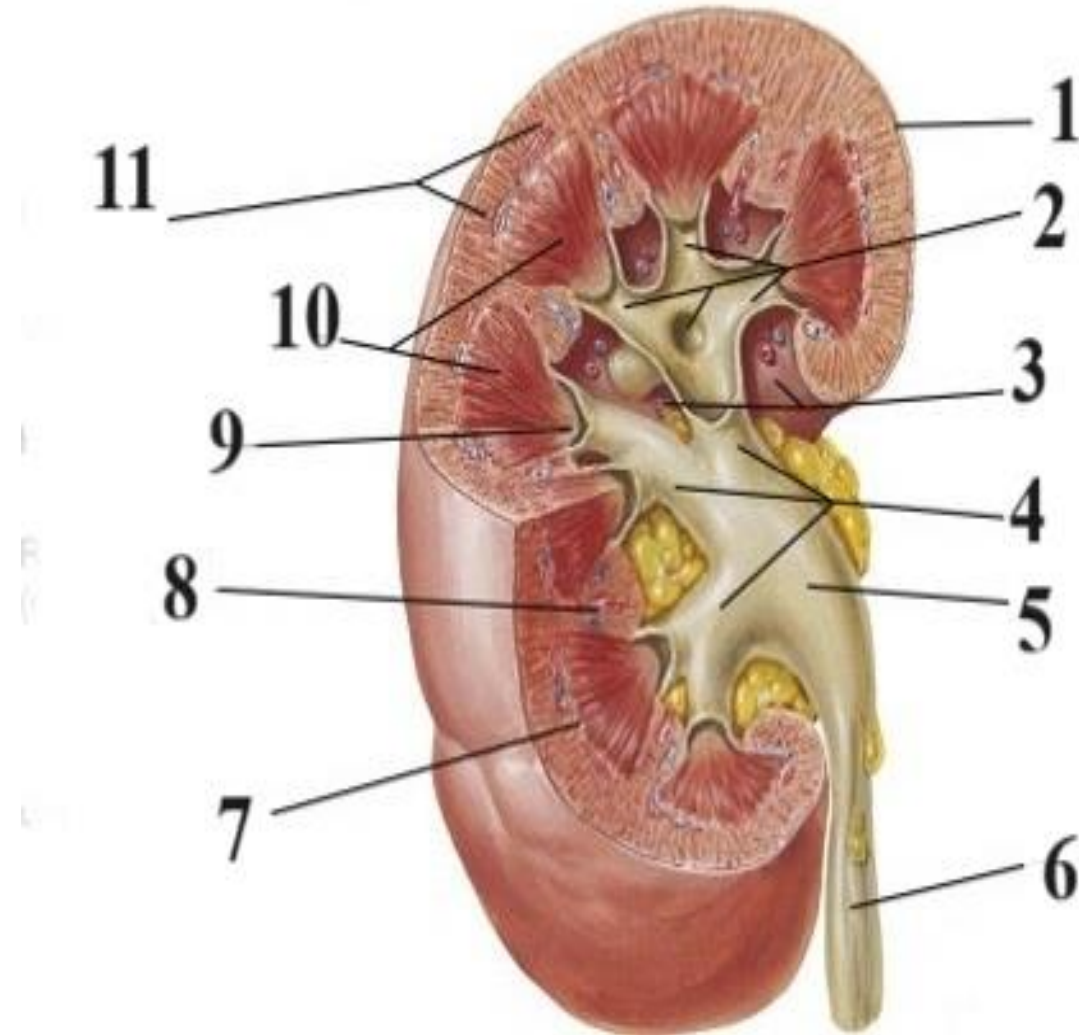
8- Pancreatic area.



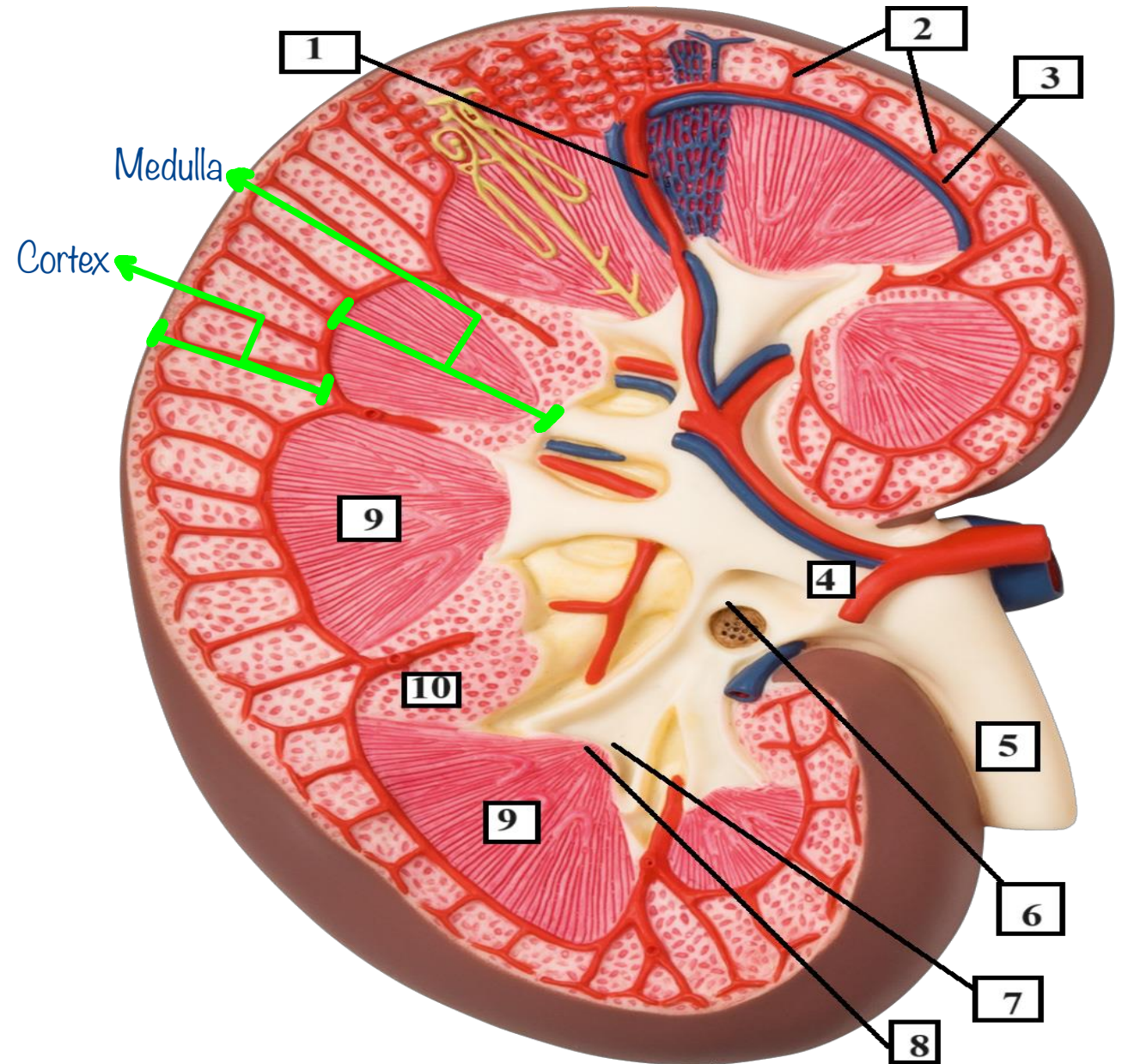
✦ Renal papilla → minor calyces → major calyces → renal pelvis → ureter

✦ Kidney is retroperitoneal organ

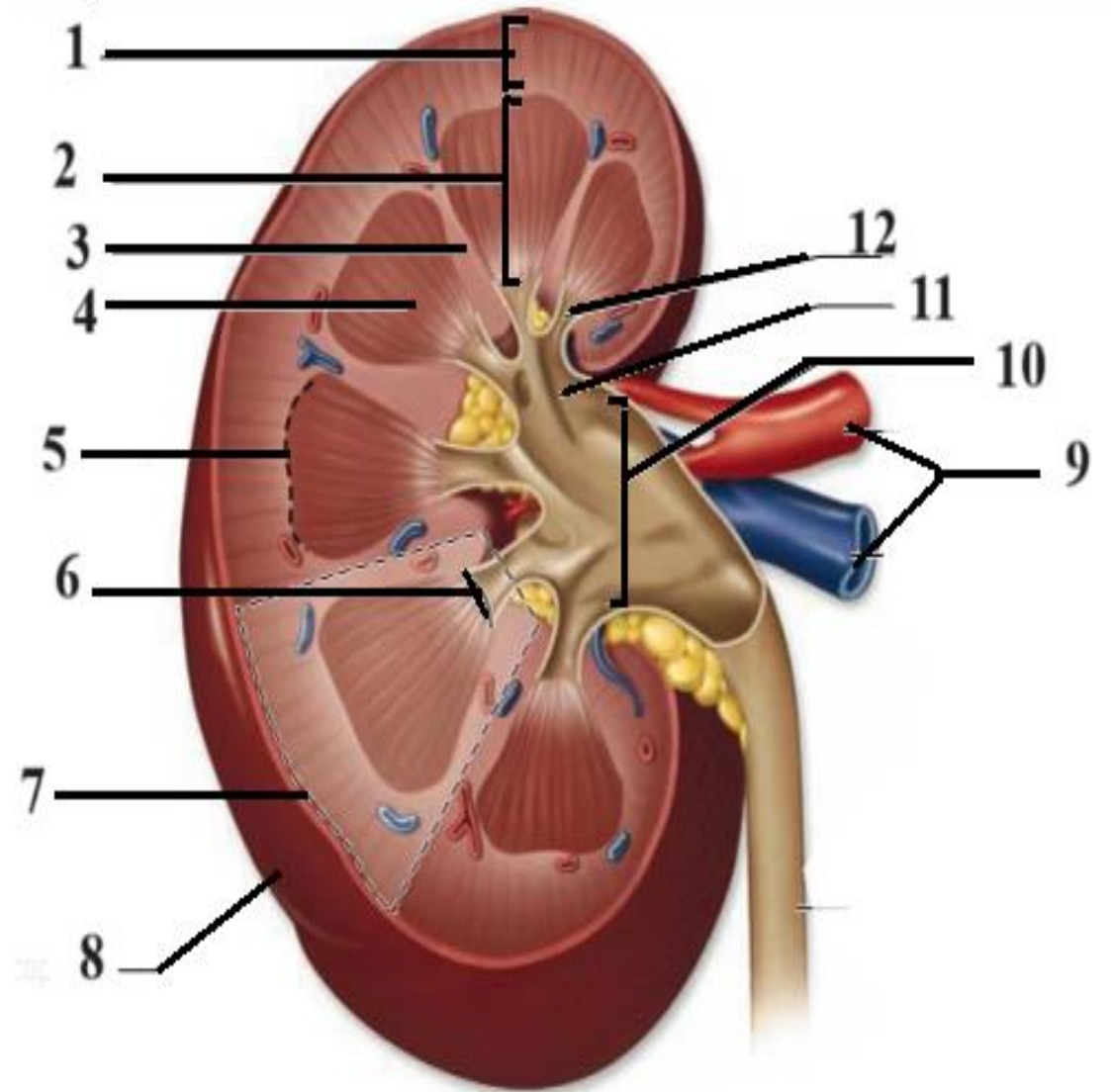
- 1- Renal capsule.
- 2- Minor calyces.
- 3- Renal sinus.
- 4- Major calyces.
- 5- Renal pelvis.
- 6- Ureter.
- 7- Base of renal pyramid.
- 8- Renal column of Bertin.
- 9- Renal papilla.
- 10- Pyramids of renal medulla.
- 11- Renal cortex.



- 1- Interlobar artery.
- 2- Interlobular arteries.
- 3- Arcuate artery.
- 4- Renal pelvis.
- 5- Ureter.
- 6- Major calyx.
- 7- Minor calyx.
- 8- Renal papilla
- 9- Renal pyramids.
- 10- Renal column of Bertin.



- 1- Renal cortex.
- 2- Renal medulla.
- 3- Renal column of Bertin.
- 4- Pyramid.
- 5- Corticomedullary junction.
- 6- Renal papilla.
- 7- Renal lobe.
- 8- Renal capsule.
- 9- Renal vessels.
- 10- Renal pelvis.
- 11- Major calyx.
- 12- Minor calyx.



كيف اميز اذا الصورة الي عندي male or female بتطلع على عضمتين من قدام ال pubis وراها يكون ال urinary bladder و ال coccyx من ورا قدامها ال large intestines and ال rectum بشوف بين ال bladder و ال rectum في عضو بالنص او لا الي هو الرحم، اذا في معناها female اذا ما في بدور على external genitalia اذا لقيت معناها male (ملاحظة صغيرة ممكن ما يكون في الرحم بالنص و ما في external genitalia هاي بتكون female بس عاملة عملية شايلة الرحم بس ما بيجي اشني زي هيك حبيت اكتبها عشان ذكرها باللاب)

1- Right ureter.

2- Uterus.

3- Urinary bladder.

حدد اذا ل male او female

4- Urethra.

5- Vagina.

6- Uterovesical pouch.

المكان هاد اله اهمية كبيرة لما يكون فيه pus بال lower abdomen بفعل الجاذبية راح يتجمع بهاد ال pouch يكون female حرارتها ٤٠ و موجوعة و عندها تقل بسبب تجمع ال pus فدكتور النسائية و التوليد بالعيادة بعمل ال procedure التالية بقطع جزء صغير من ال posterior wall of vagina و كل ال pus راح ينزل تلقائي و بصير immediate relief و بنعطي المريضة antibiotics لسبع ايام و برجع بخيط المكان

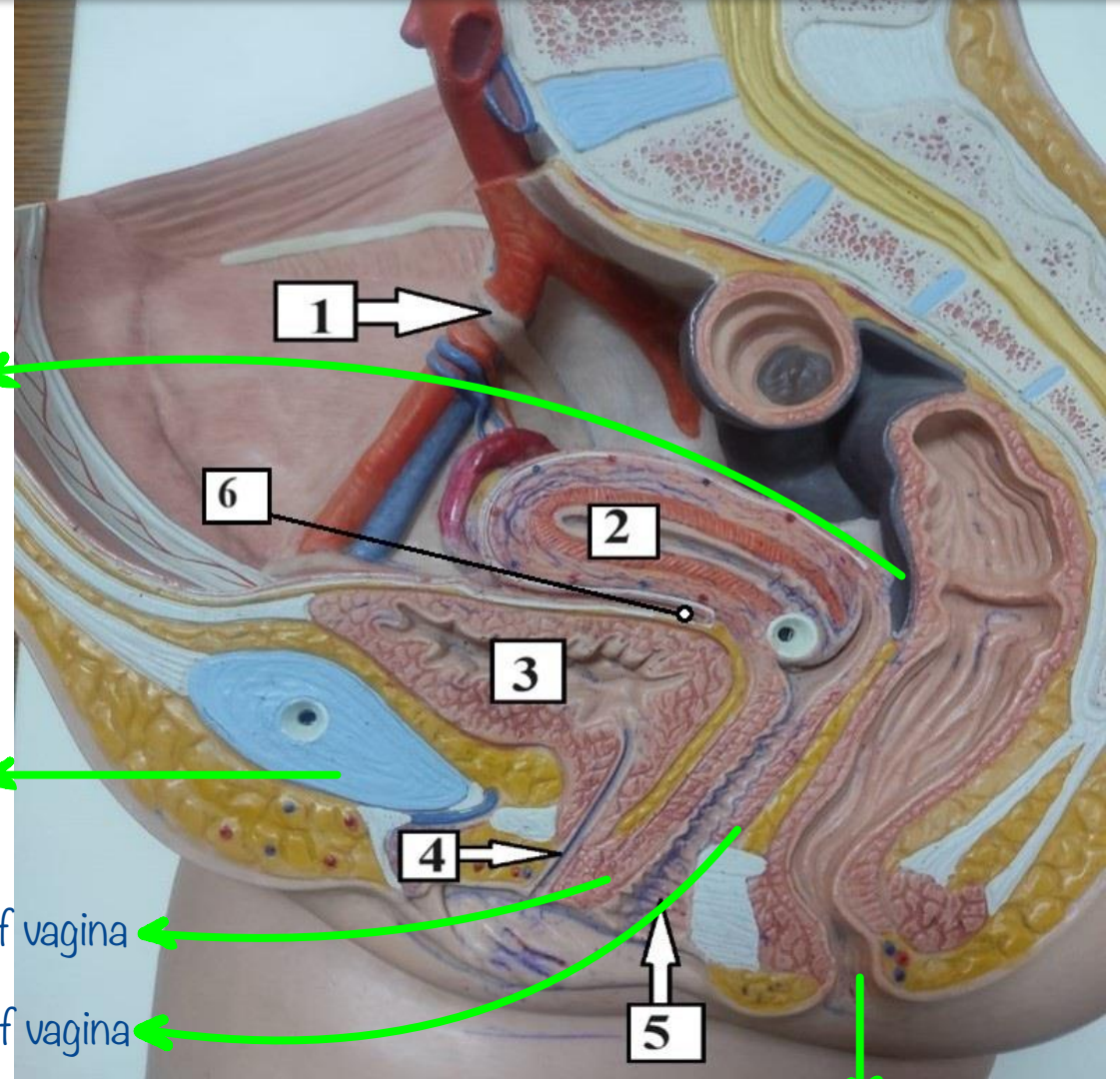
Rectovaginal pouch

Body of pubis

Anterior wall of vagina

Posterior wall of vagina

Anal canal



1- Uterus.

2- Urinary bladder.

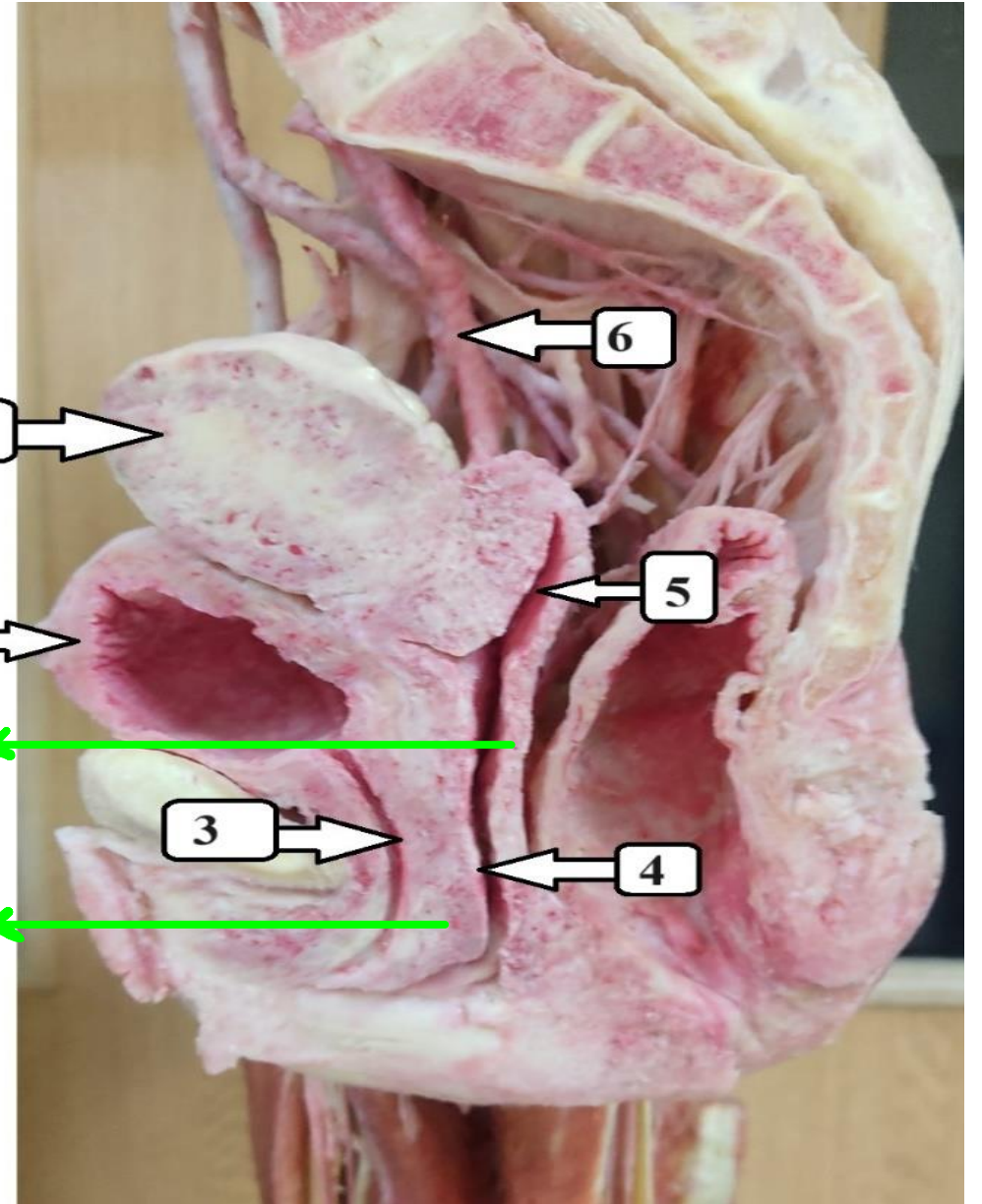
Female

3- Urethra.

4- Vagina.

5- Posterior vaginal fornix.

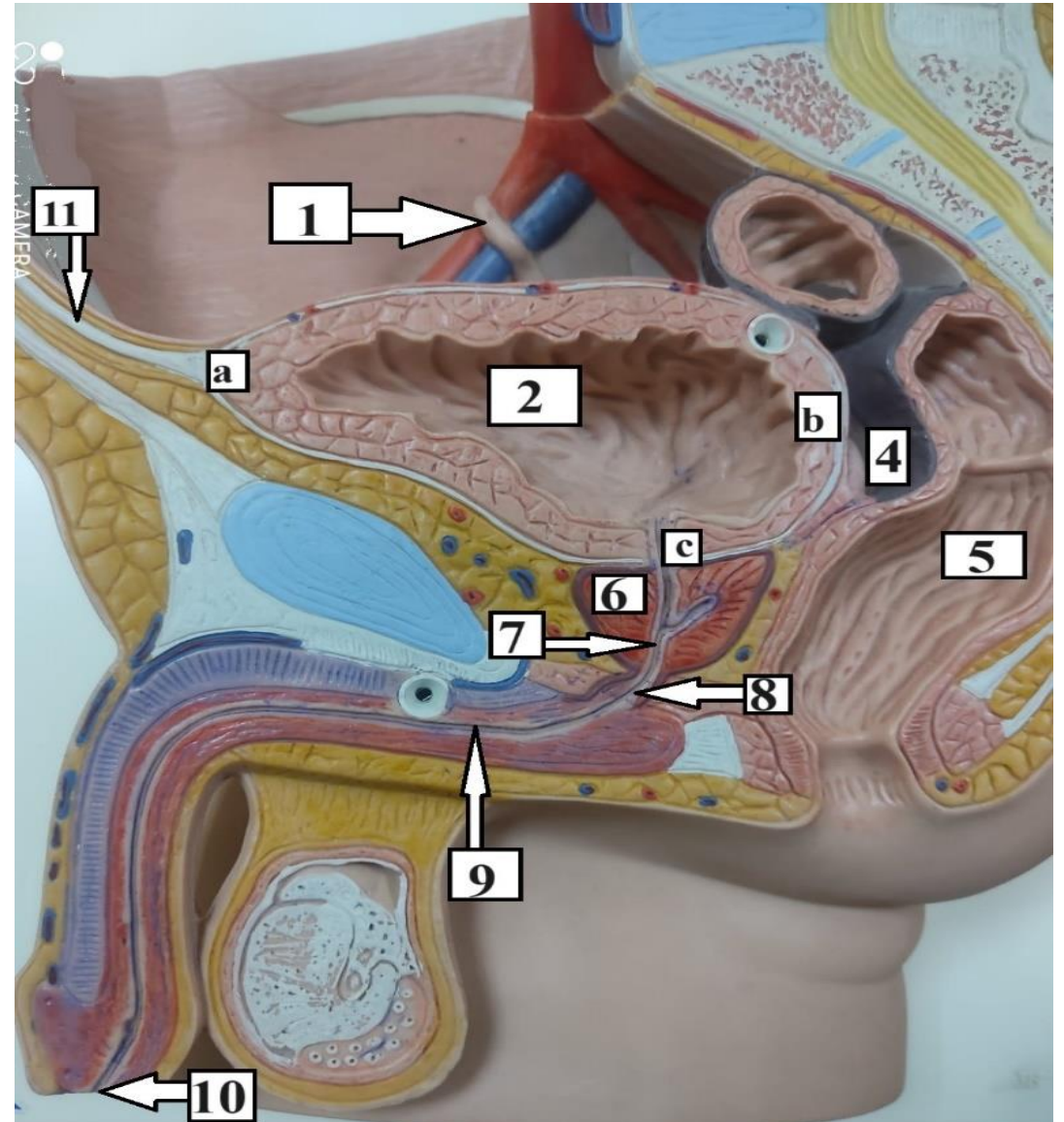
6- Right ureter.



Posterior wall of
vagina → it's longer

Anterior wall of vagina → it's shorter

- 1- Ureter.
 - 2- Urinary bladder.
 - 4- Rectovesical pouch.
 - 5- Rectum.
 - 6- Prostate.
 - 7- Prostatic urethra.
 - 8- Membranous urethra.
 - 9- Penile urethra.
 - 10- External urethral orifice.
 - 11- Median umbilical ligament.
- a- Apex of urinary bladder.
b- Base of urinary bladder.
c- Neck of urinary bladder.



1-Right external iliac vessels.

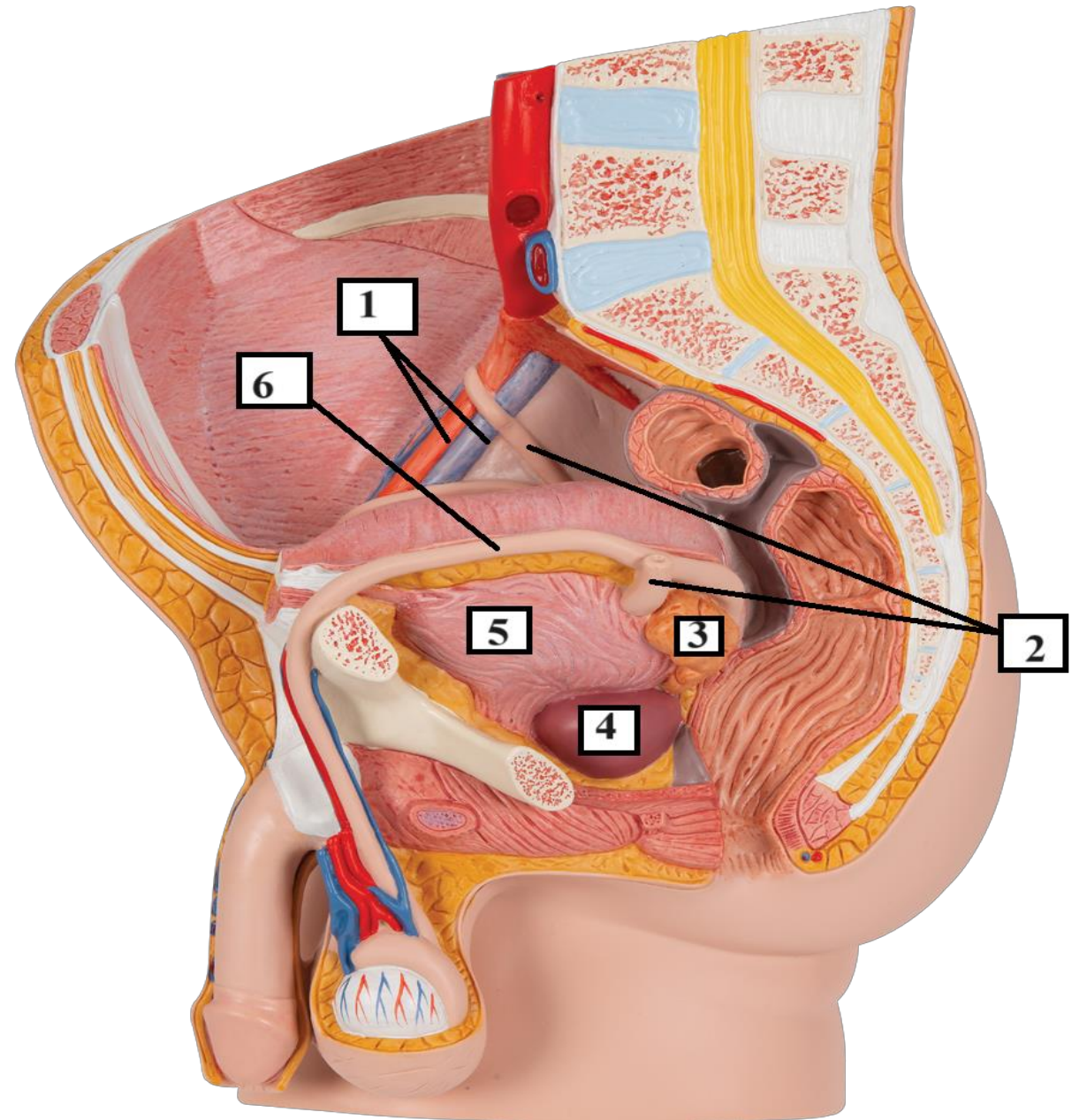
2- Ureters.

3- Seminal vesicle.

4- Prostate gland.

5- Urinary bladder.

6- Left vas deferens.



1- Right ureter.

2- Median umbilical ligament.

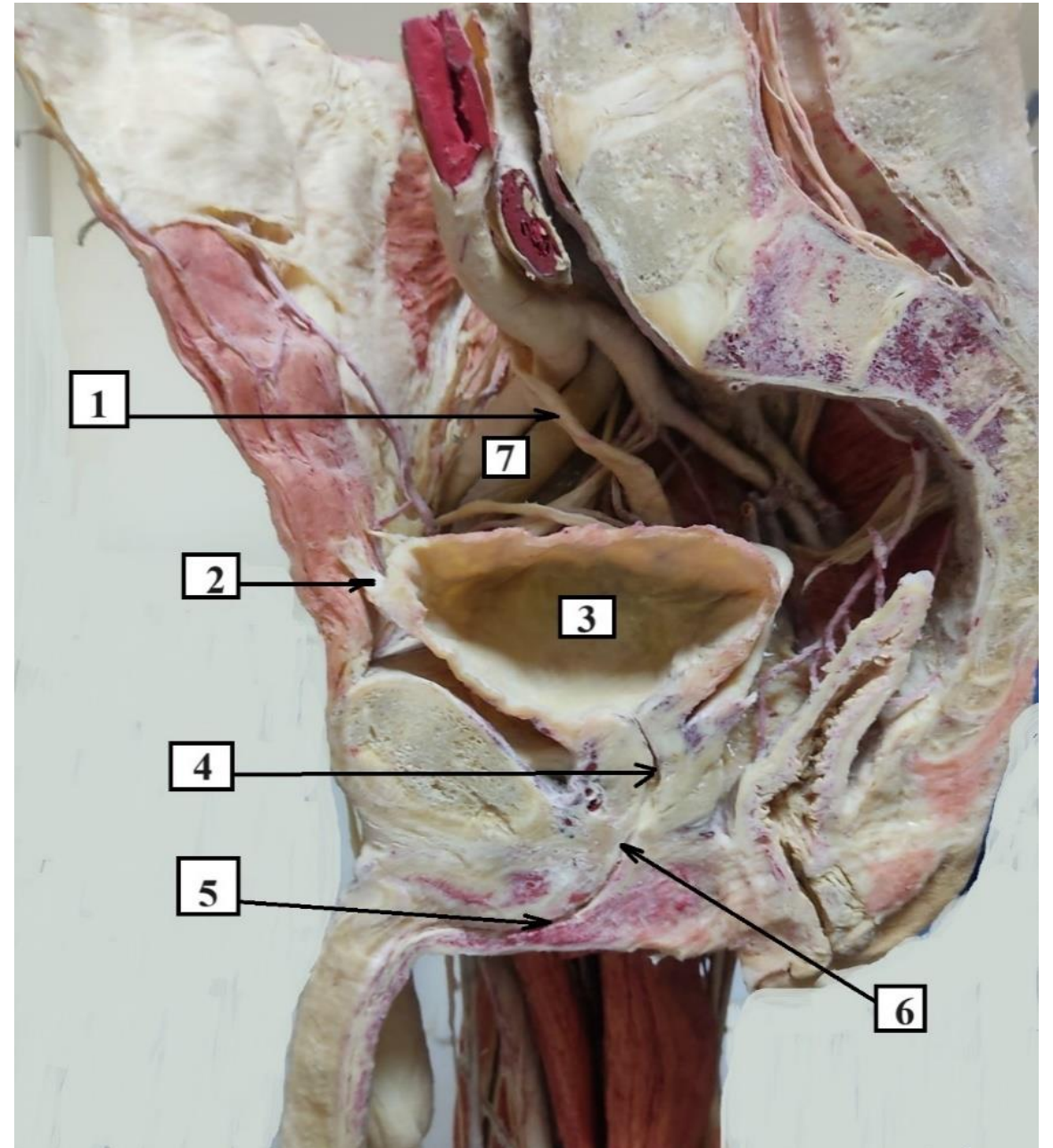
3- Urinary bladder.

4- Prostatic part of urethra.

5- Penile part of urethra.

6- Membranous part of urethra.

7- Right external iliac vessels.



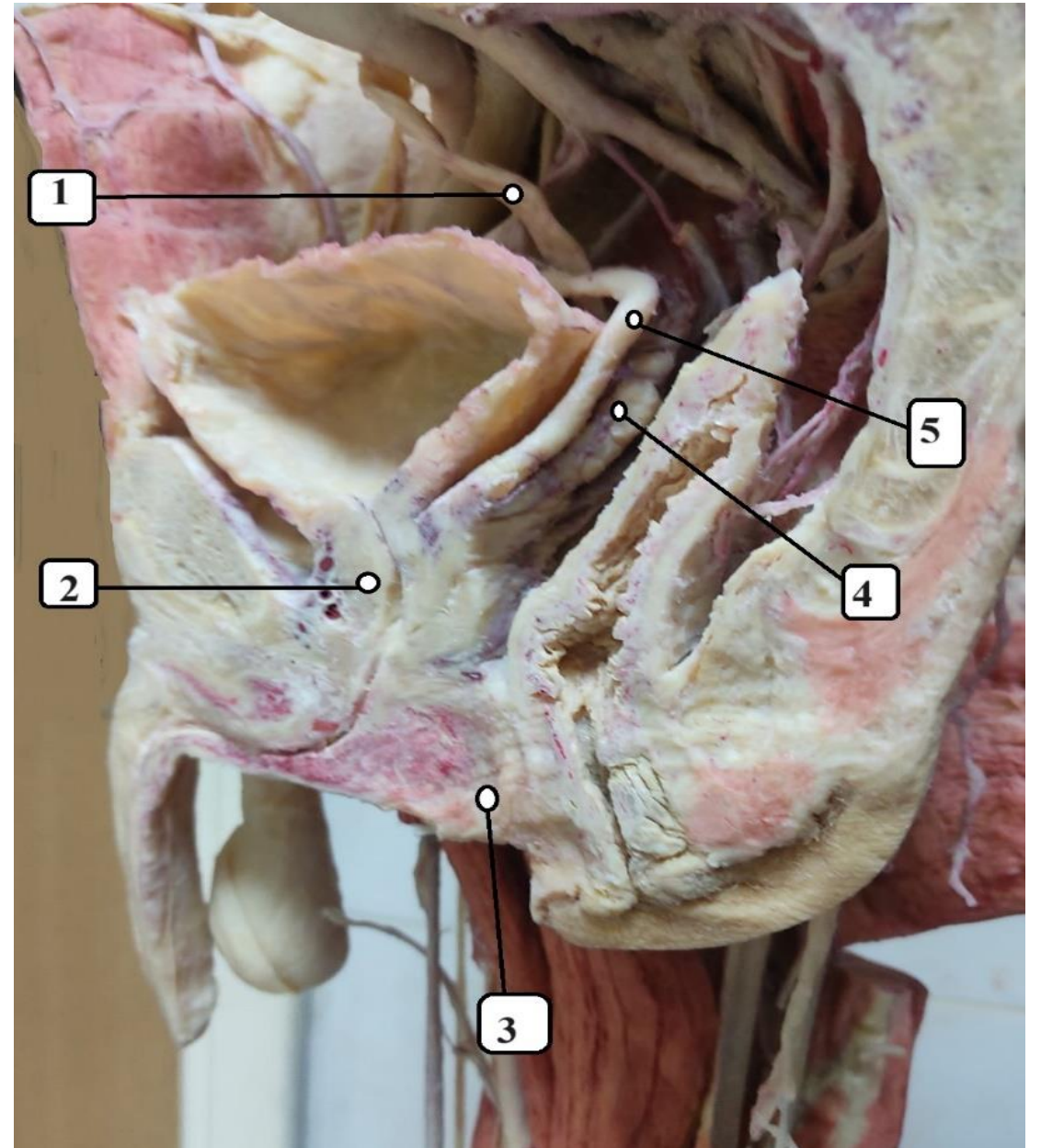
1- Right ureter.

2- Prostate.

3-Perineal body.

4- Right seminal vesicle.

5- Right ductus (vas) deferens.



1- Urinary bladder.

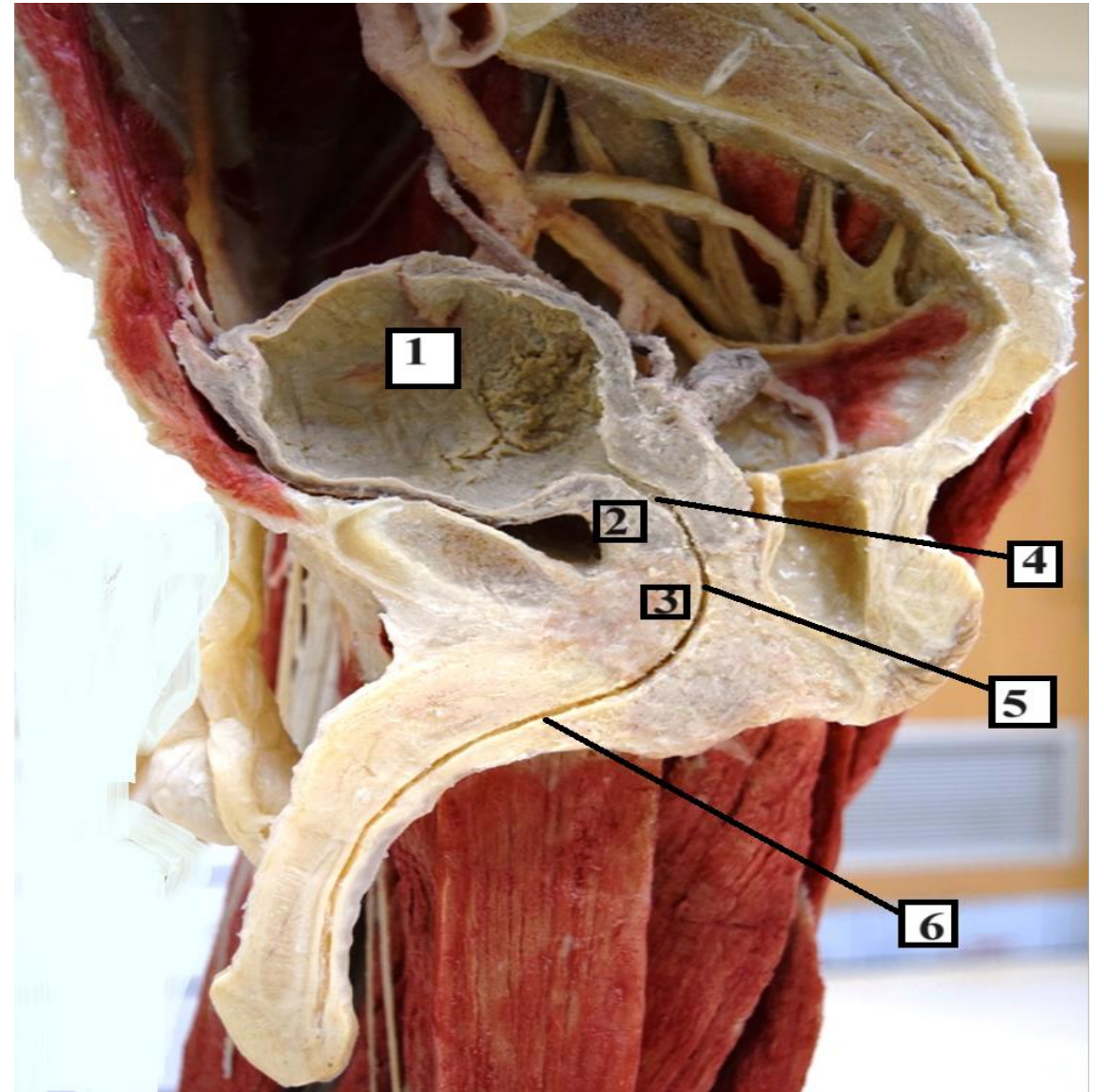
2- Prostate.

3- External urethral sphincter.

4- Prostatic part of urethra.

5- Membranous part of urethra.

6- Penile part of urethra.



1- Peritoneum.

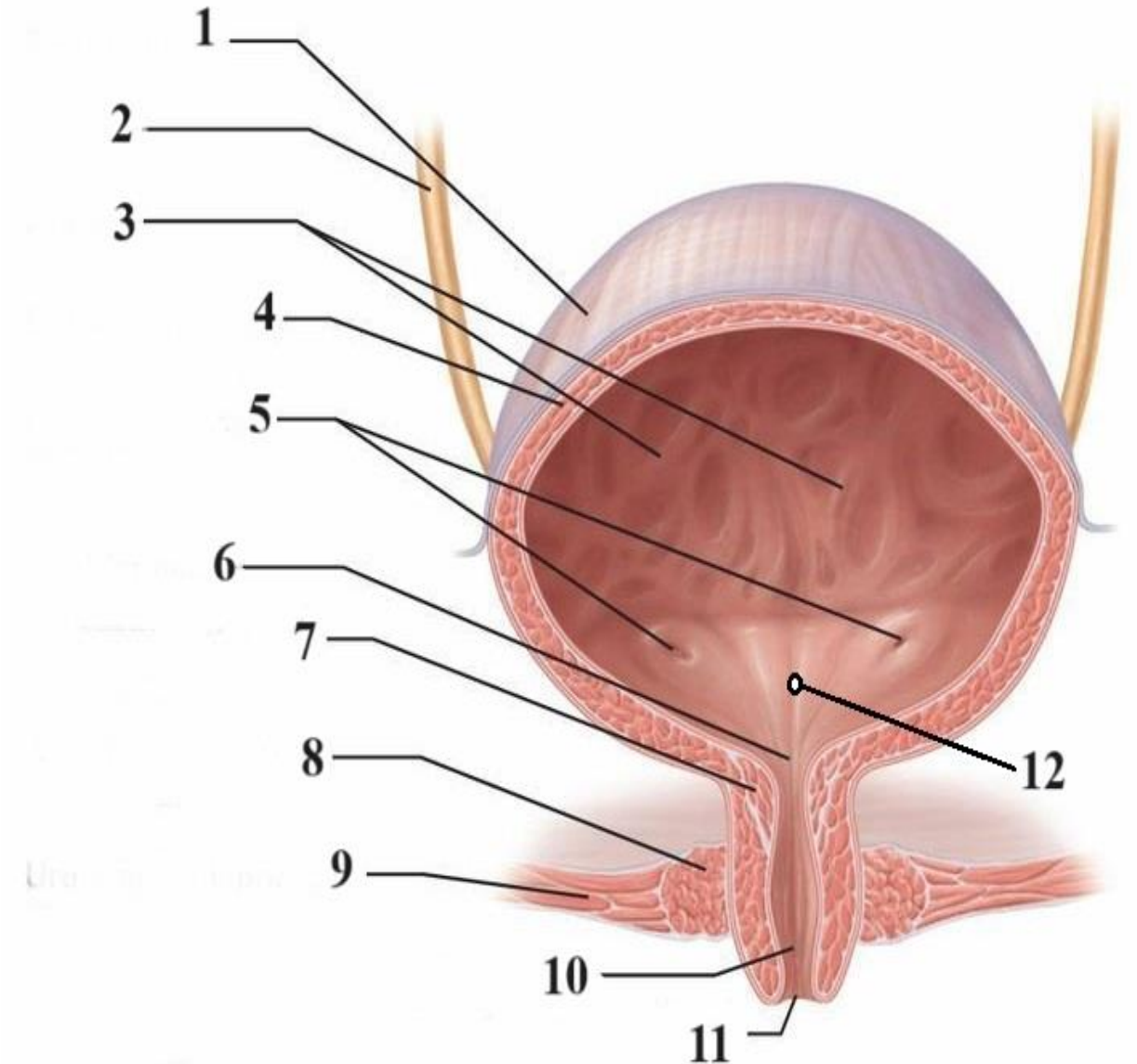
2- Right ureter.

3- Rugae. *Mucosal holdings*

4- Detrusor muscle.

5- Ureteric orifices.

6- Bladder neck (internal urethral orifice).



7- Internal urethral sphincter.

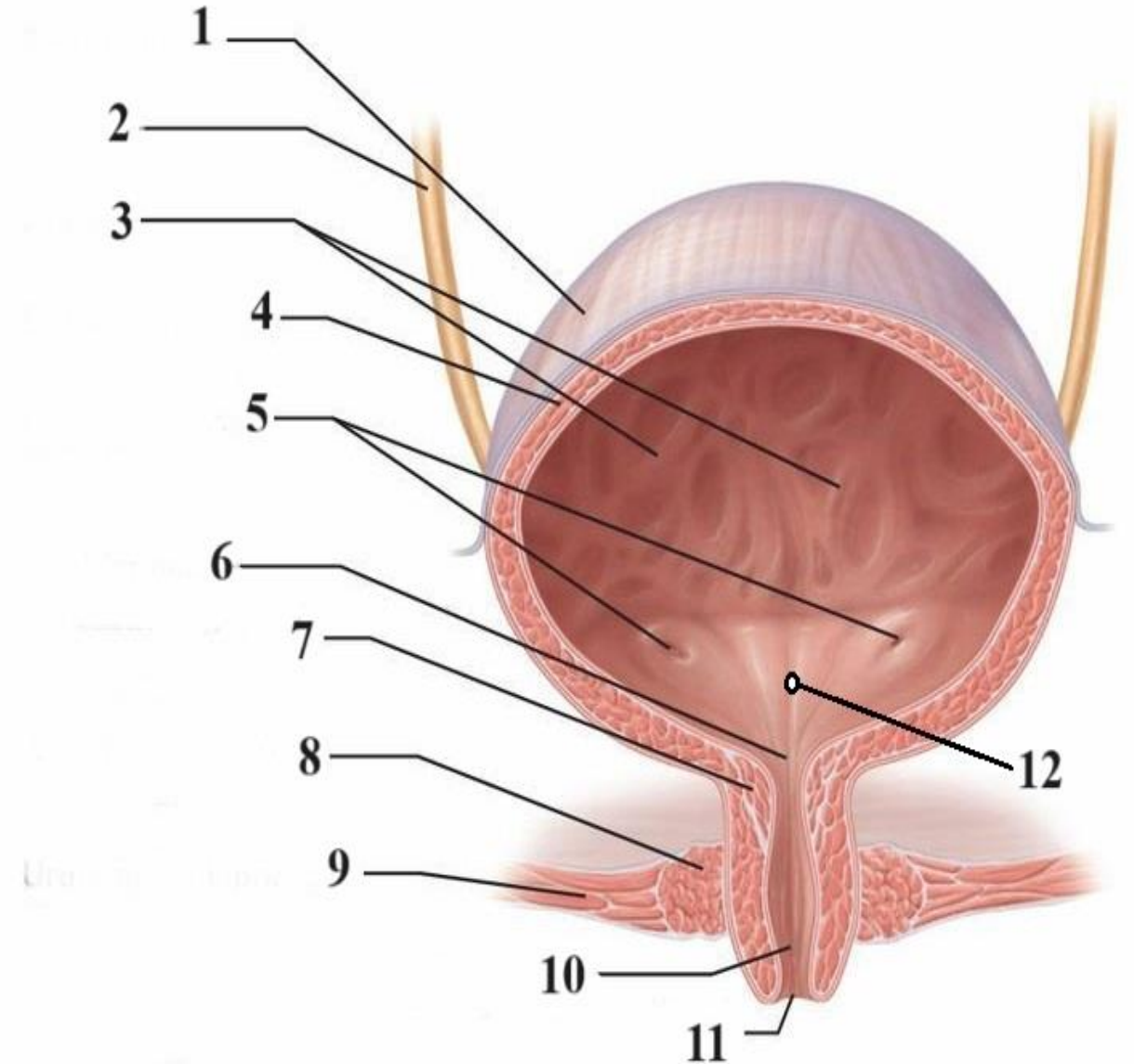
8- External urethral sphincter.

9- Urogenital diaphragm.

10- Urethra.

11- External urethral orifice.

12- Trigone.



a- Left ureter.

b- Rugae.

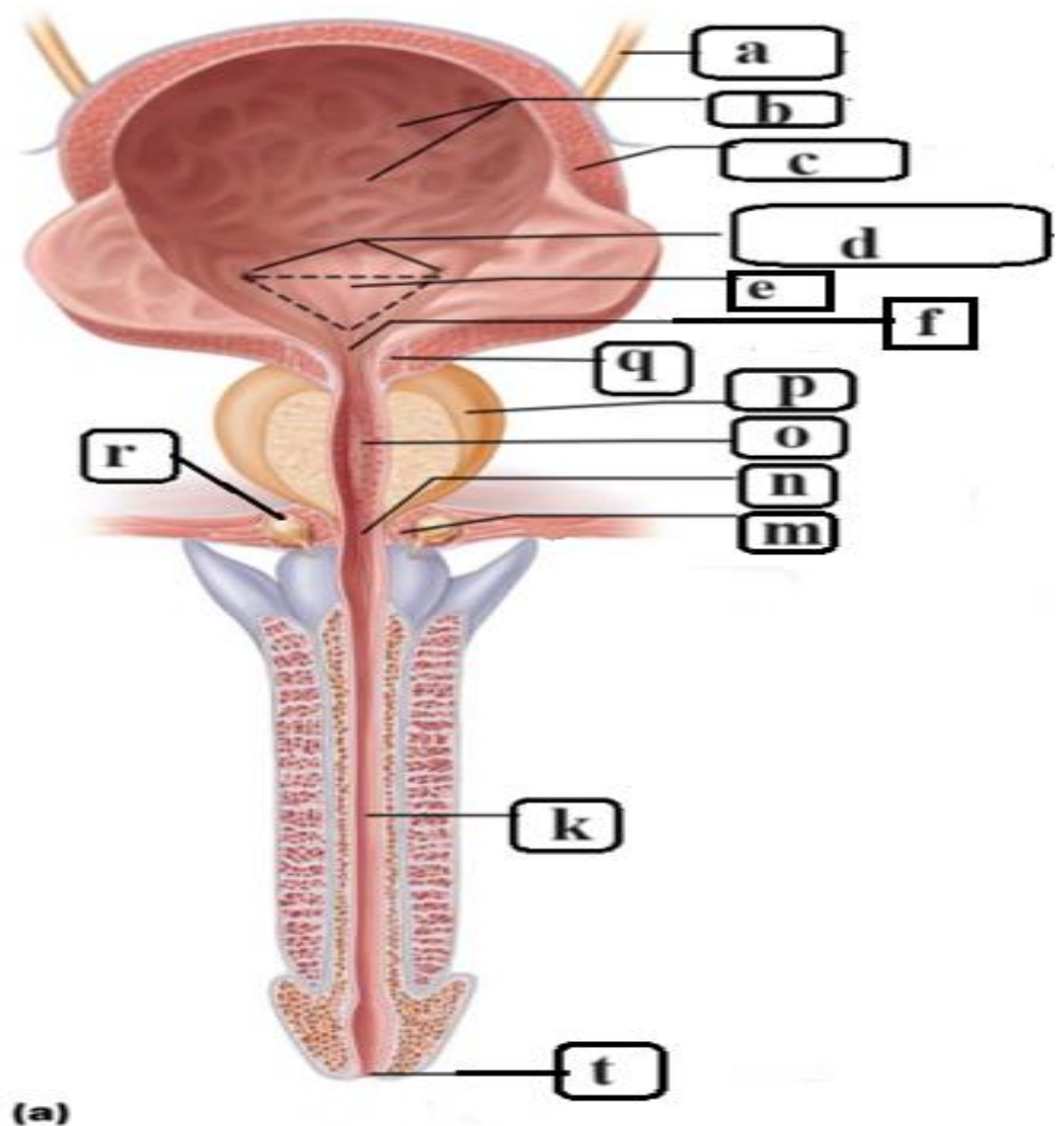
c- Detrusor muscle.

d- Ureteric orifices.

e- Trigone.

f- Bladder neck (internal urethral orifice).

q- Internal urethral sphincter.



p- Prostate gland.

o- Prostatic part of urethra.

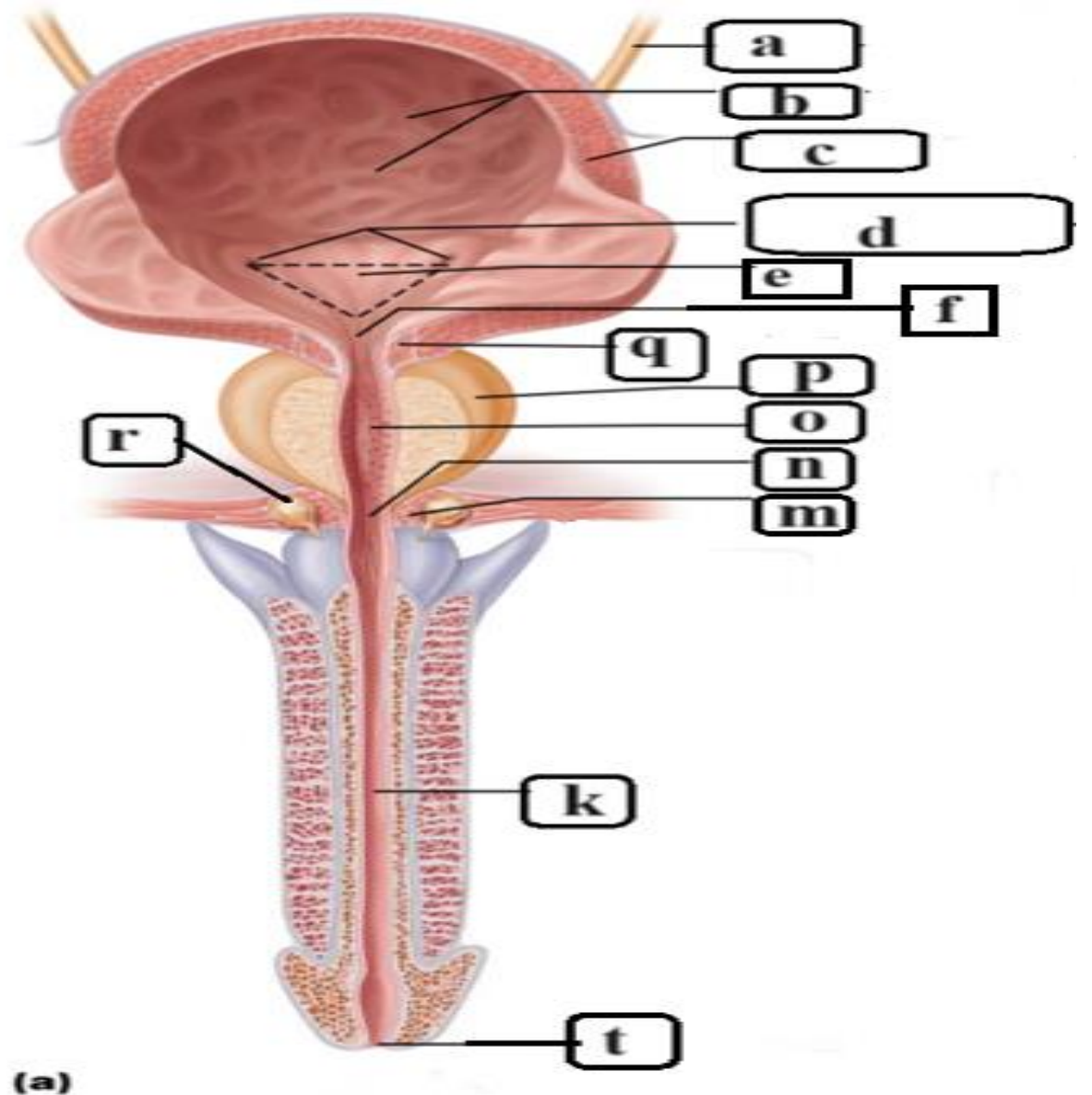
n- Membranous part of urethra.

r- Bulbourethral gland.

K- Penile part of urethra.

m- External urethral sphincter.

t- External urethral orifice.



1- Peritoneum.

2- Urinary bladder.

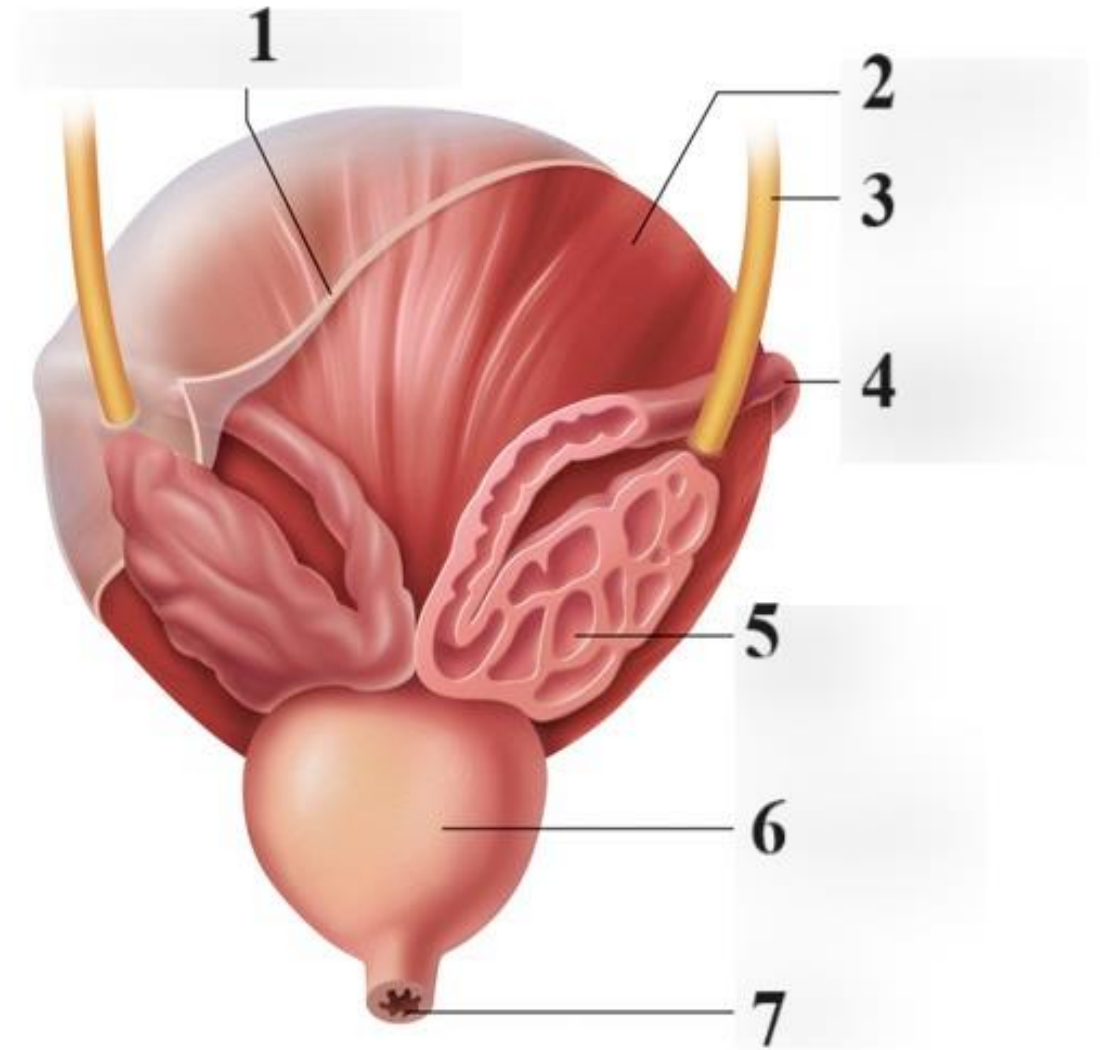
3- Right ureter.

4- Right ductus deferens.

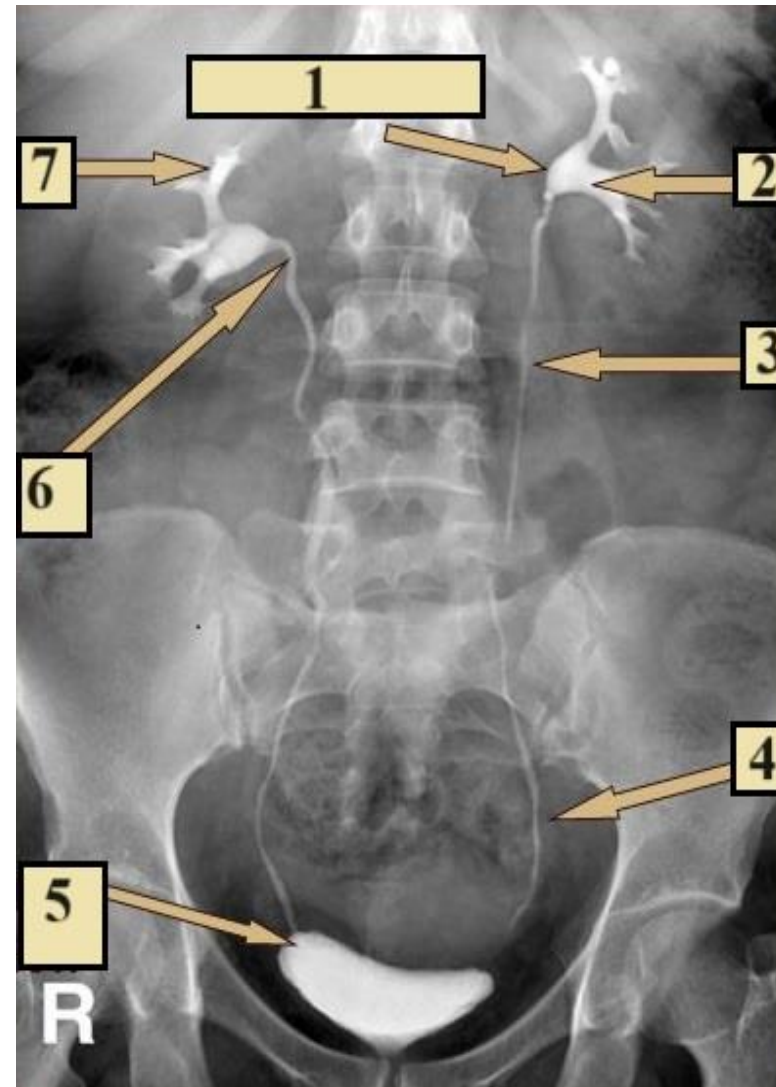
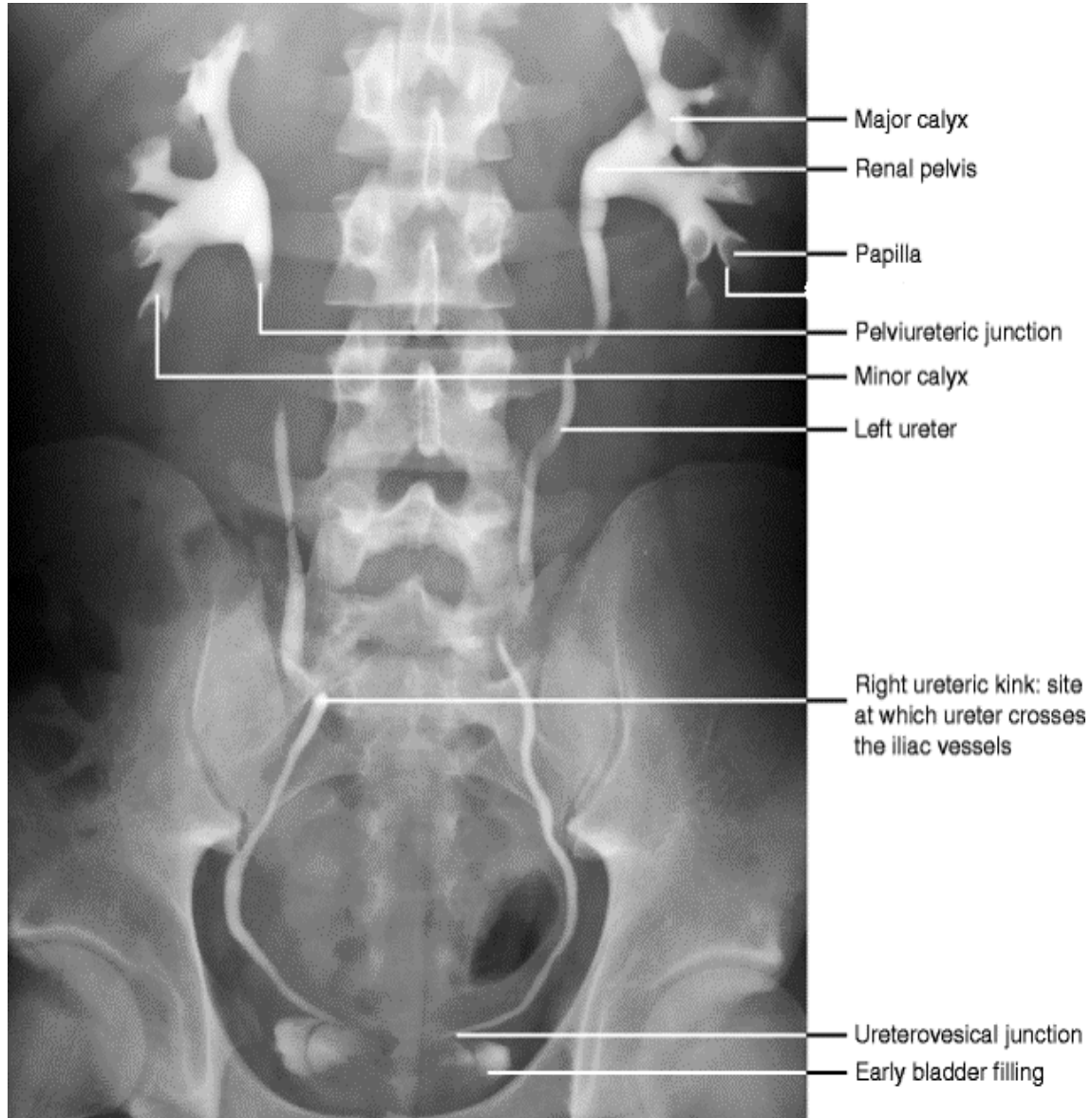
5- Right seminal vesicle.

6- Prostate.

7- Membranous urethra.



Intravenous Pyelography (IVP)



- 1- Renal pelvis.
- 2- Major calyx.
- 3- Abdominal part of ureter.
- 4- Pelvic part of ureter.
- 5- Uterovesical junction.
- 6- Pelvi-ureteric junction.
- 7- Minor calyx.

A: Minor Calyx.

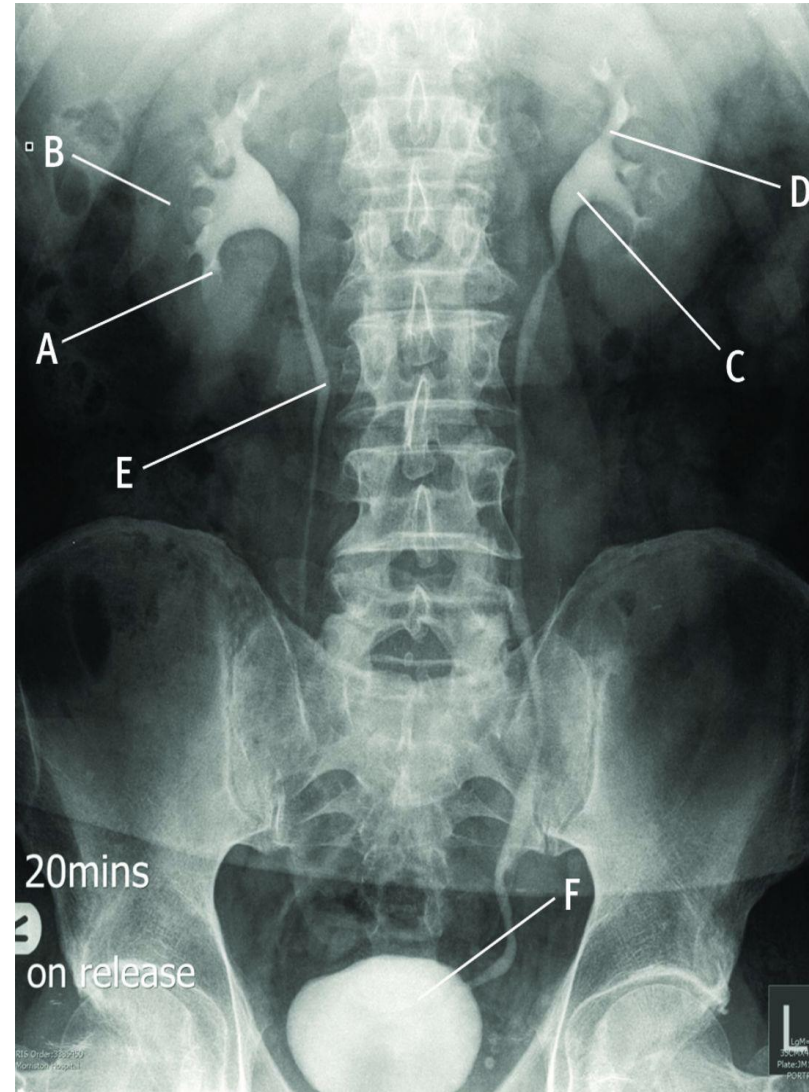
B: Right kidney

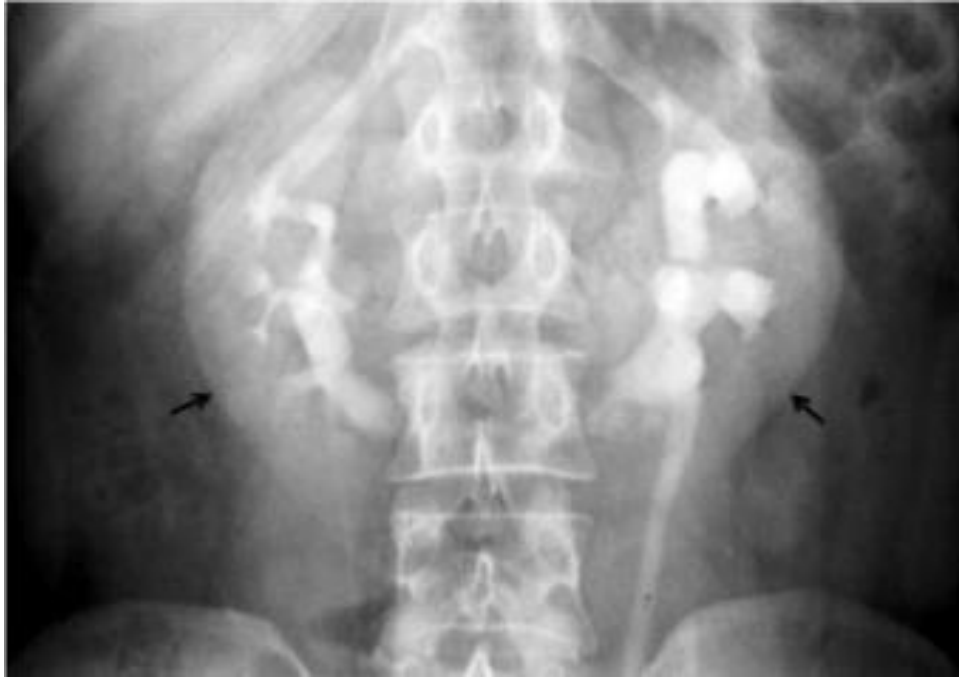C: Left renal pelvis

D: Major calyx.

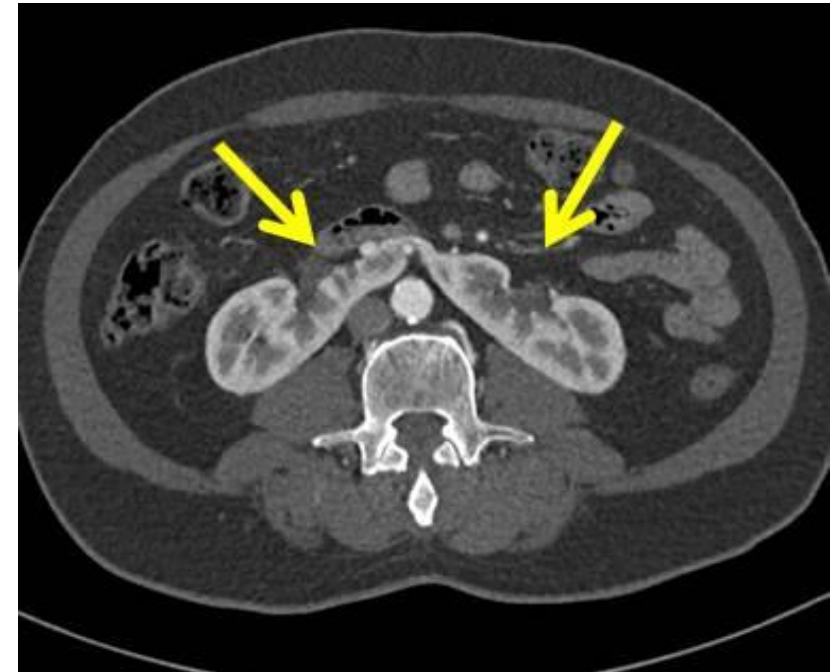
E: Right ureter

F: Urinary bladder

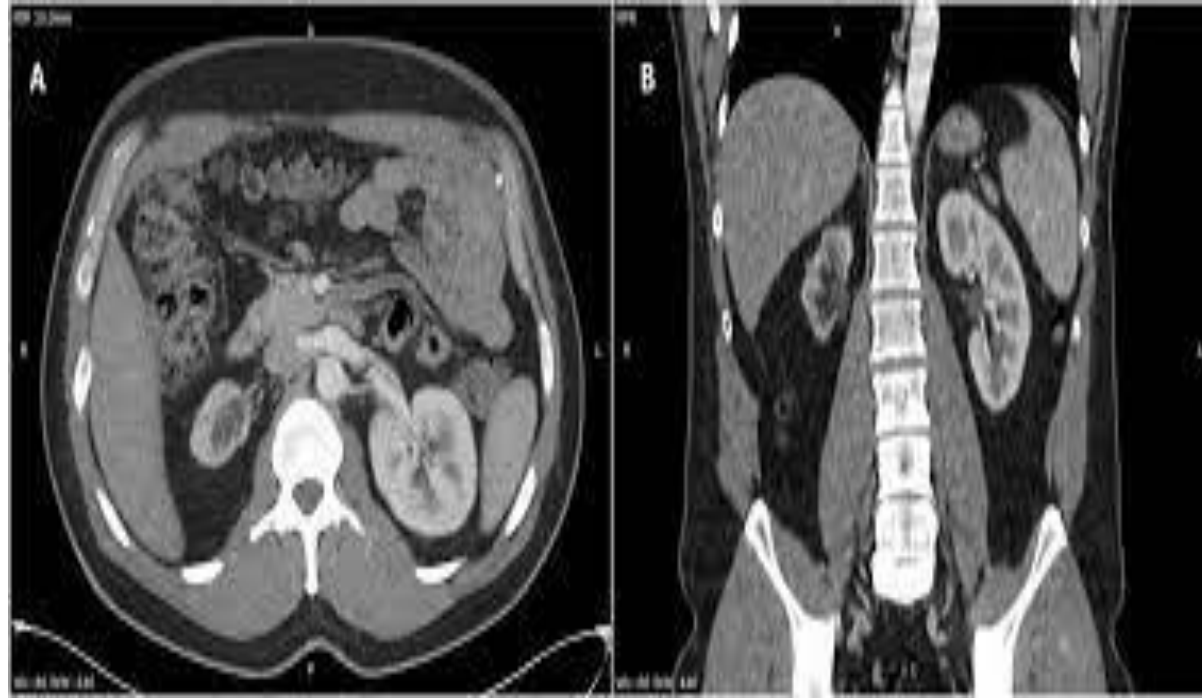




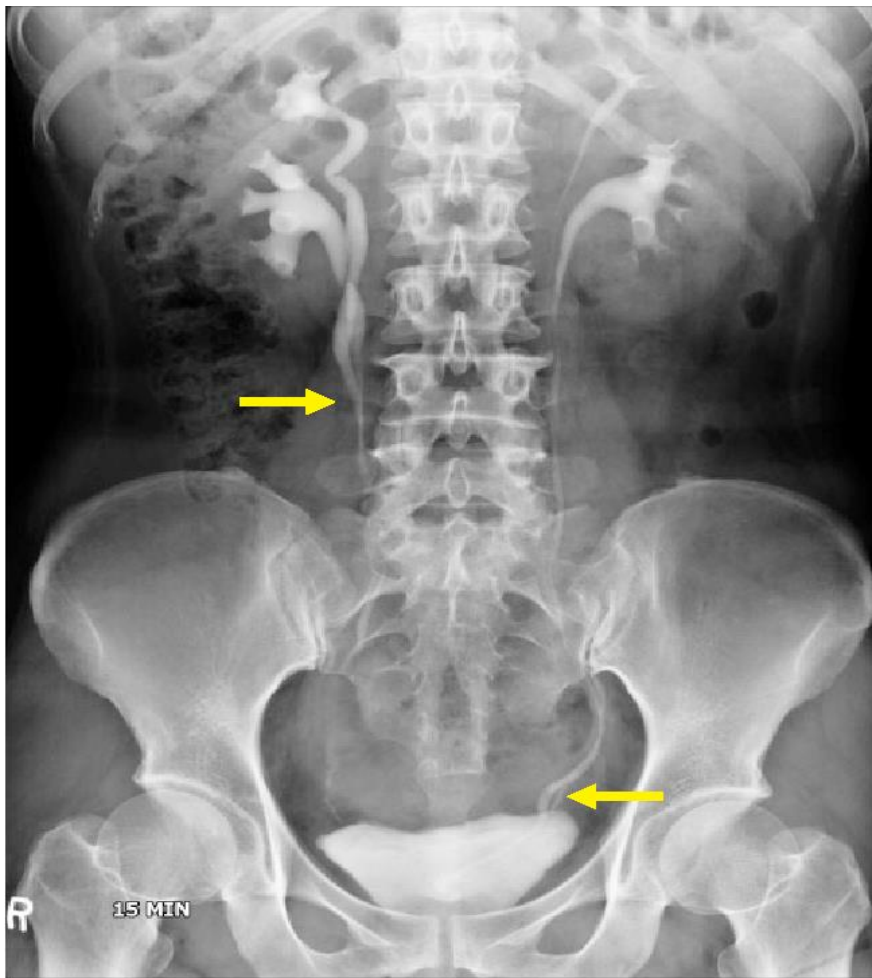
Intravenous pyelography film in a case of horseshoe kidney (arrows) showing lower poles closer to the spine.



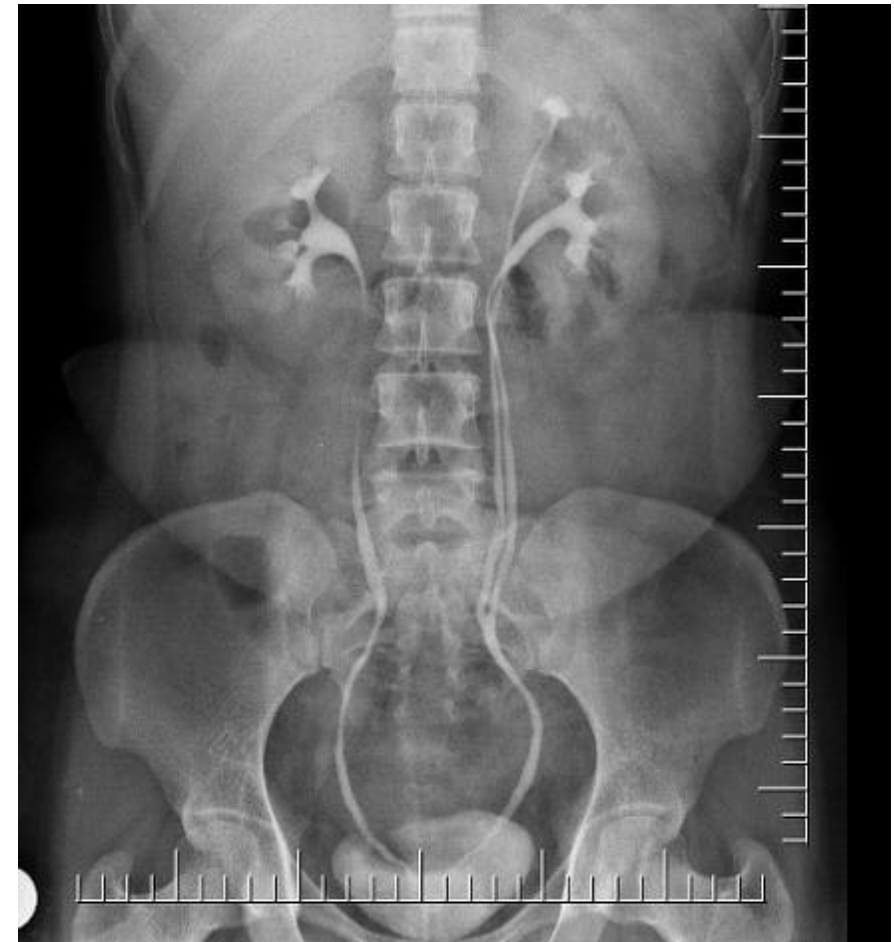CT scan abdomen, showing a case of horseshoe kidney.



CT scan abdomen, A case of unilateral renal hypoplasia.



Intravenous urography shows bilateral ureteral duplications. Although right side is shown as incomplete form, left side is complete form by showing entire course of double ureters



Intravenous urography of a left sided double ureter. The double ureters in this case is of the incomplete/partial variety.

**Thank
you**