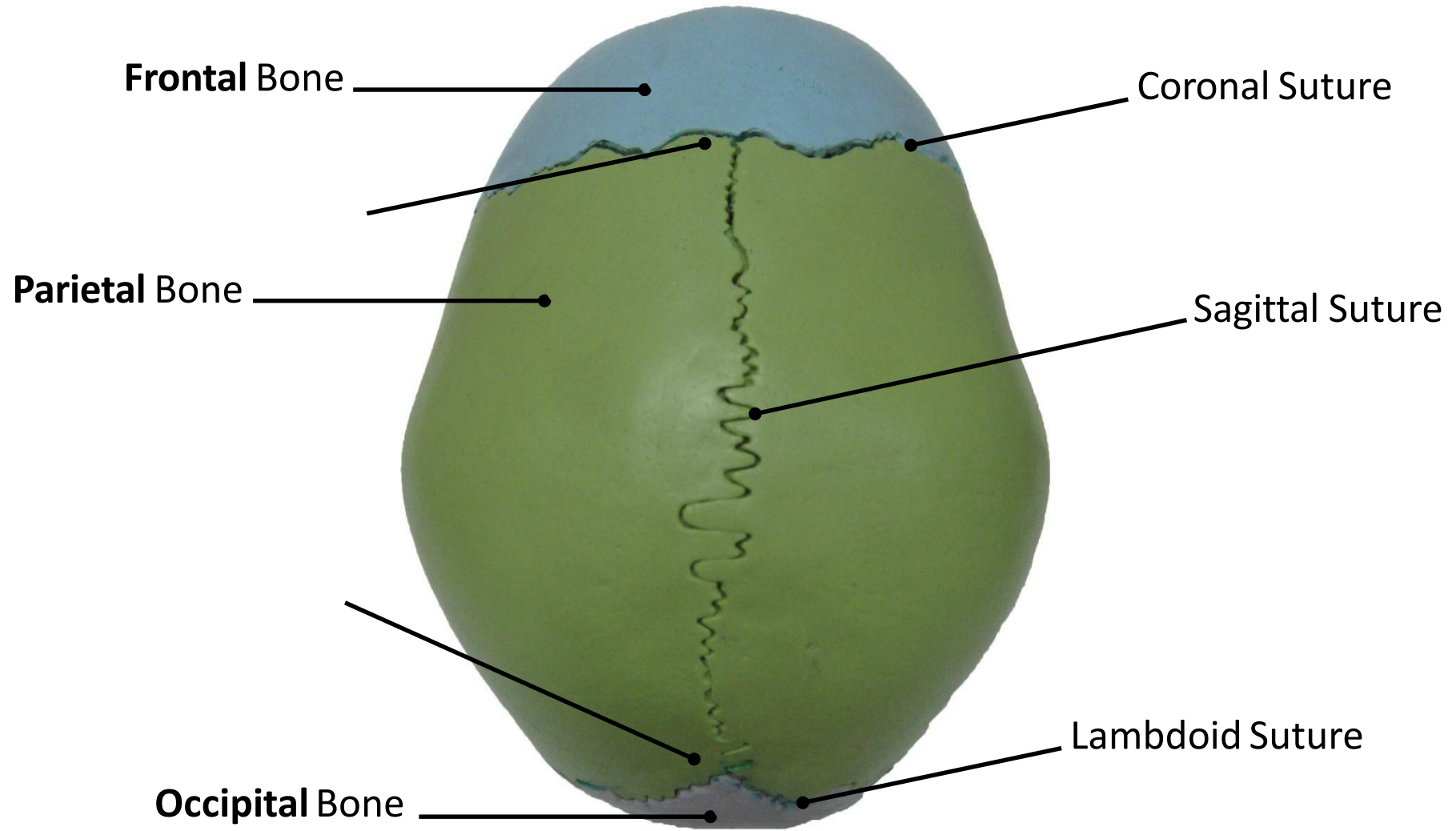
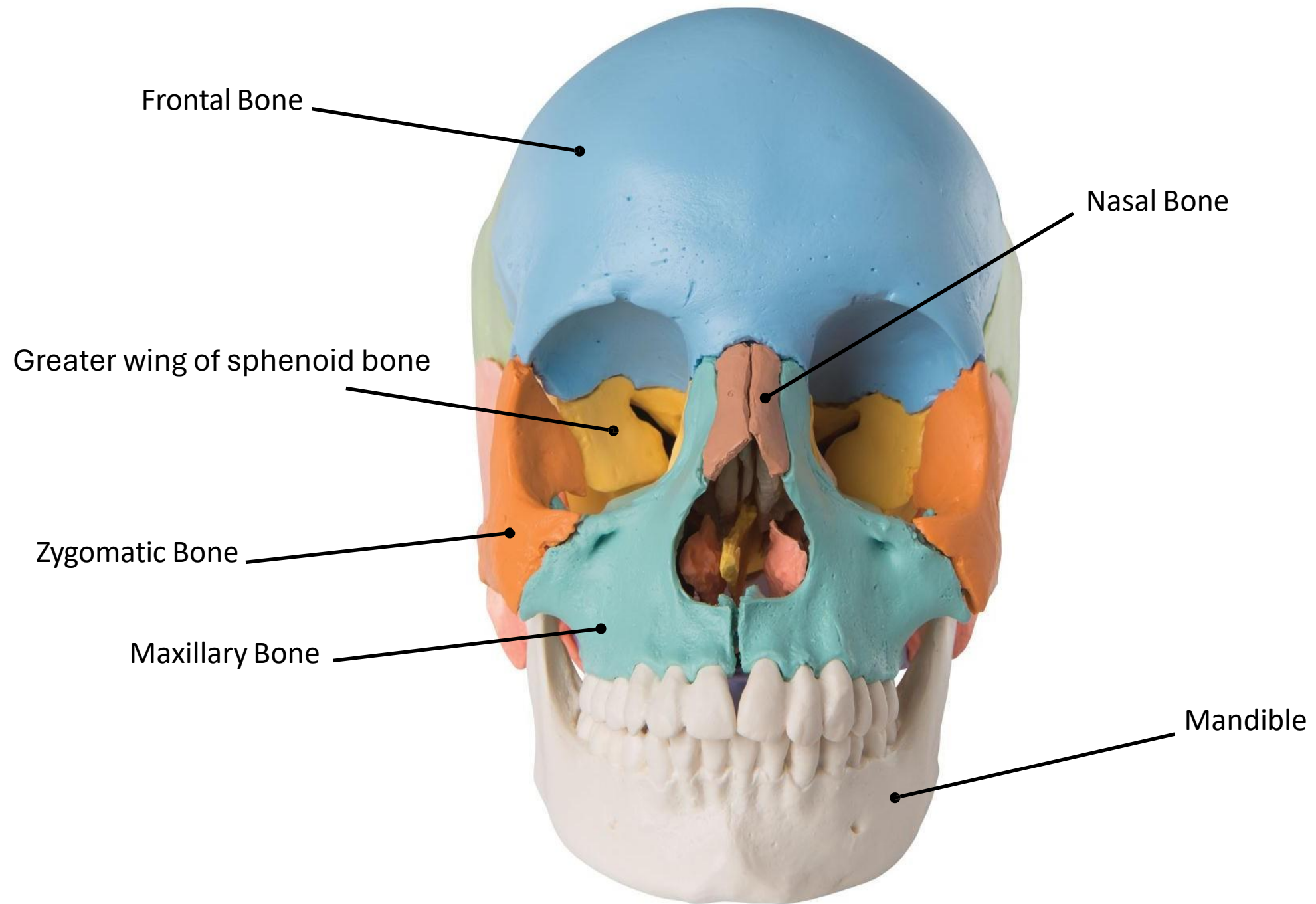


# Lab 1

## Axial Skeleton



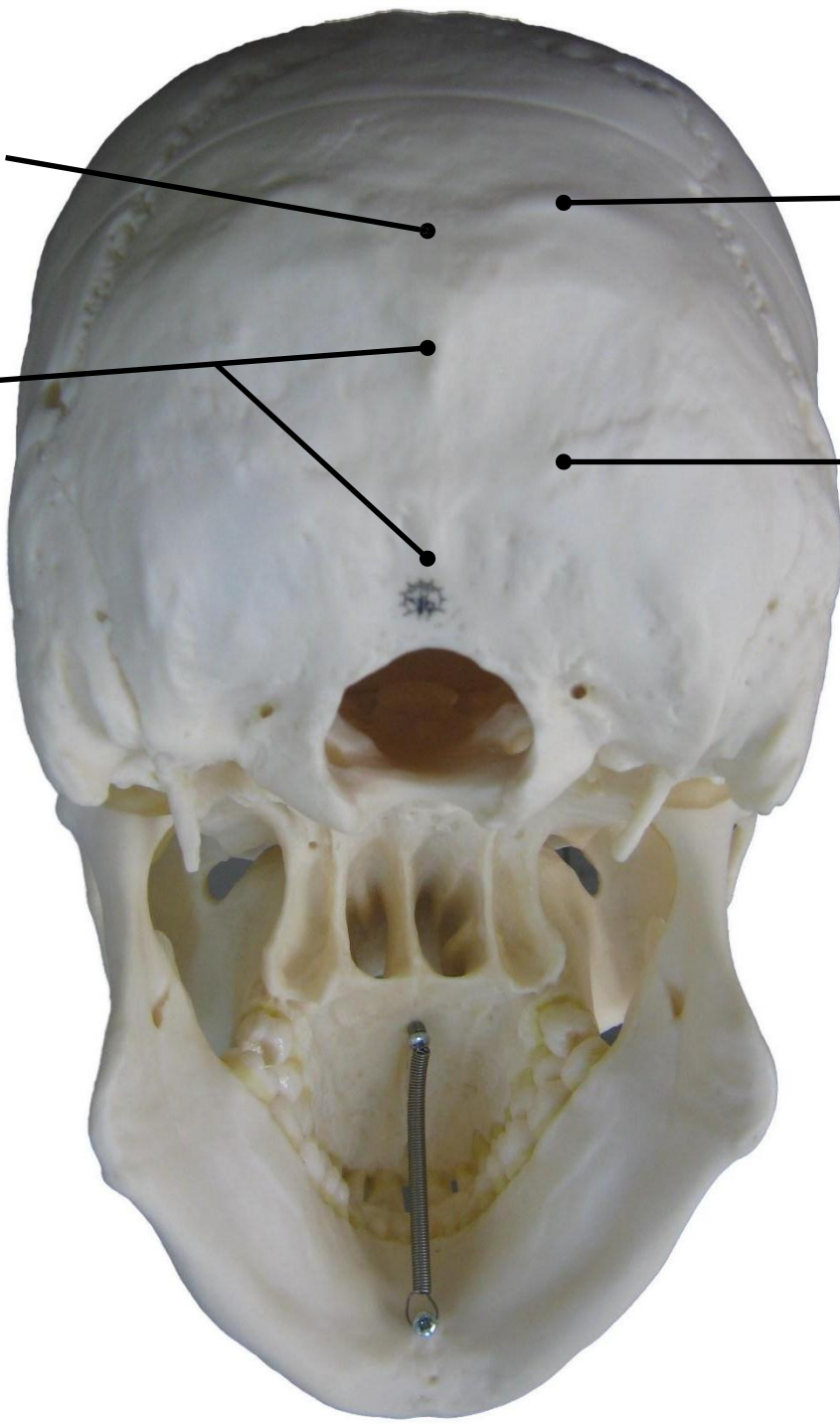


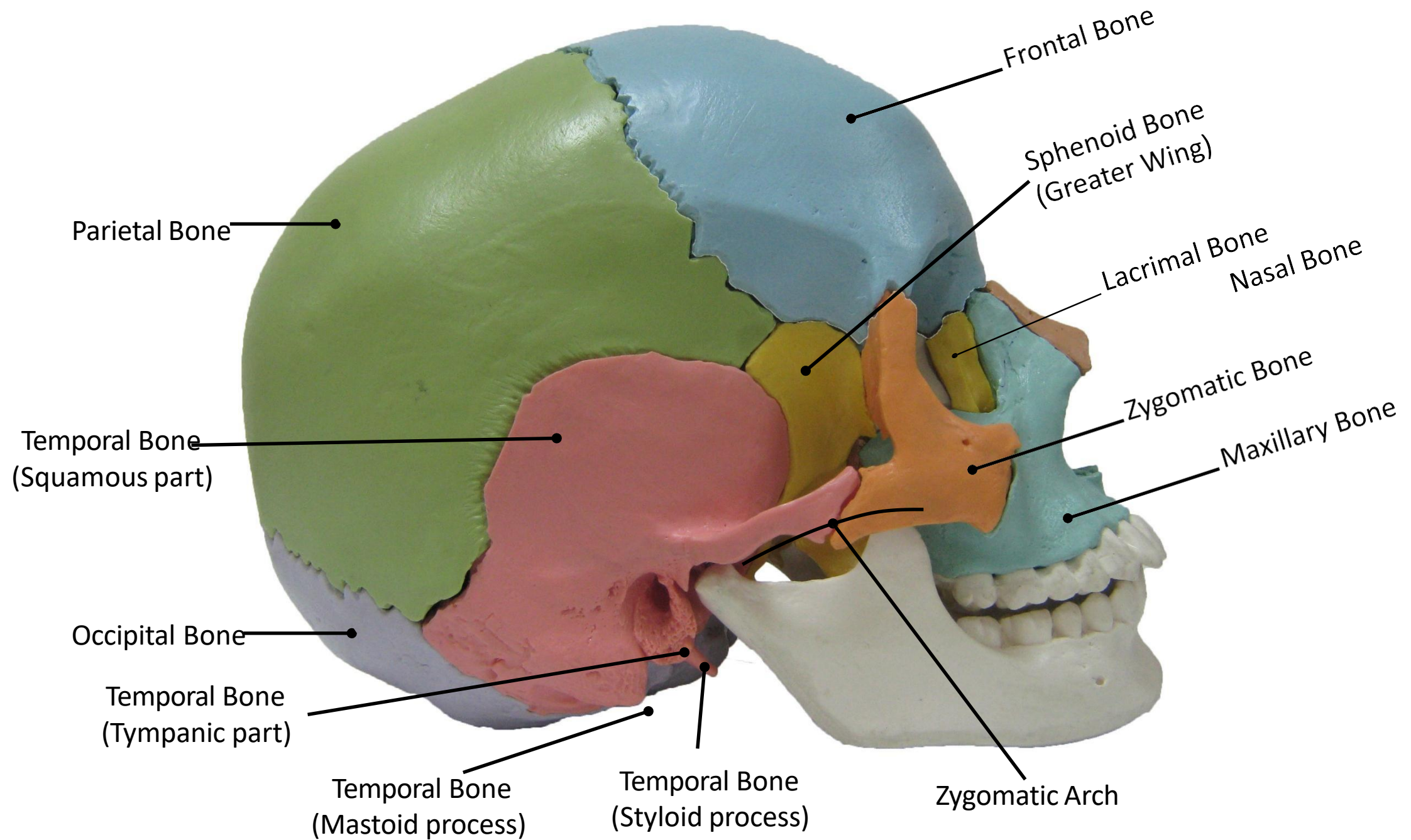
External Occipital Protuberance

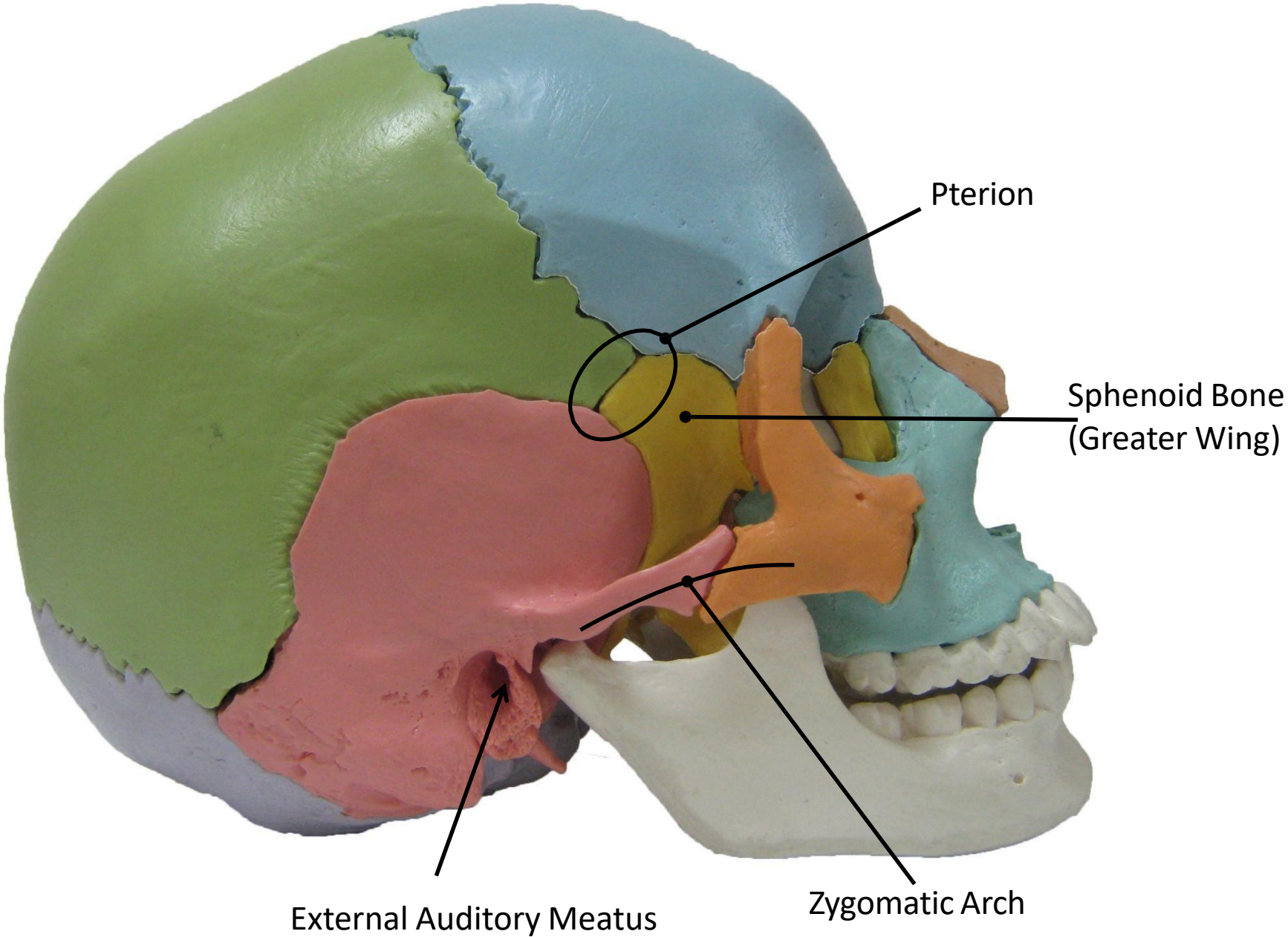
Superior Nuchal Line

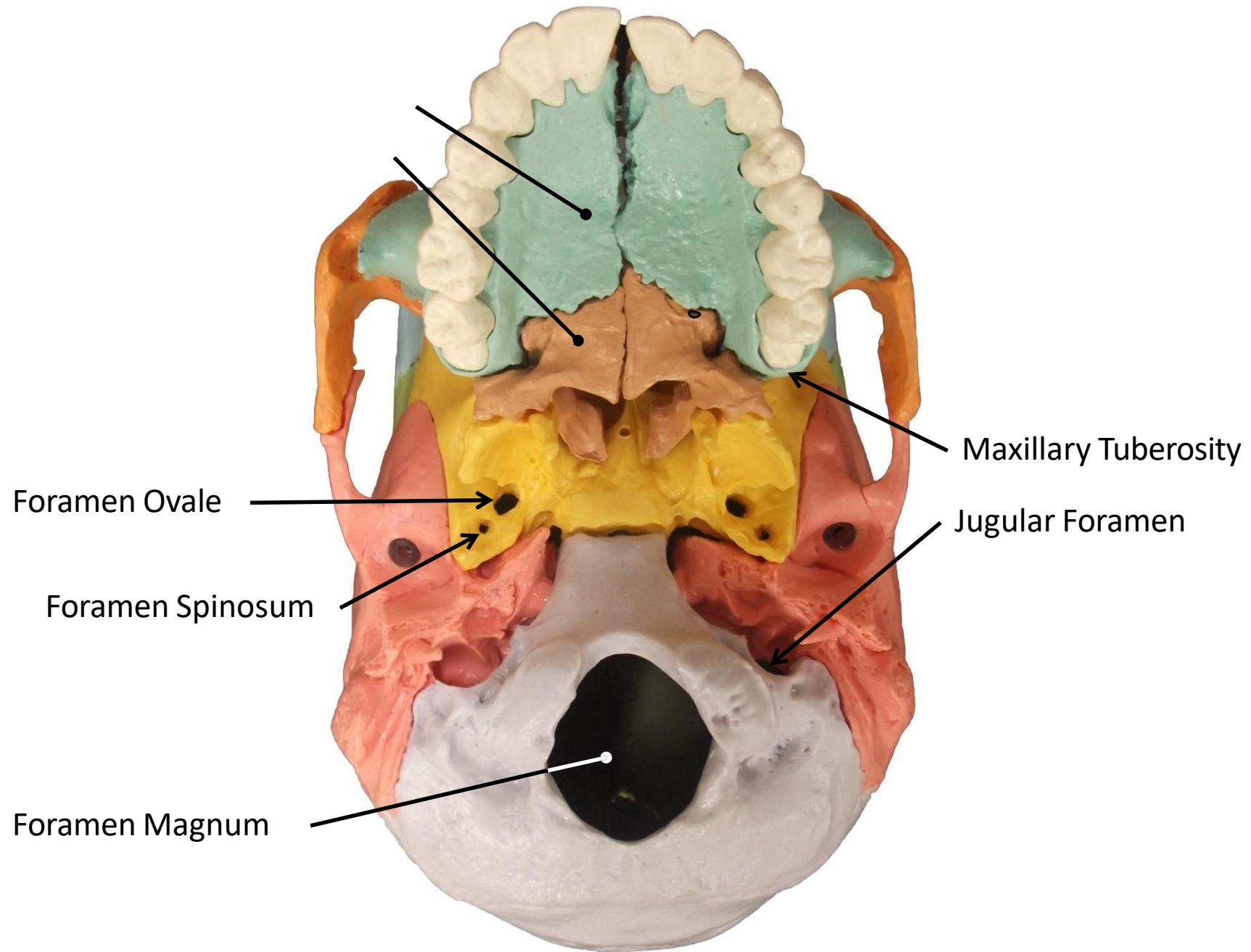
External Occipital Crest

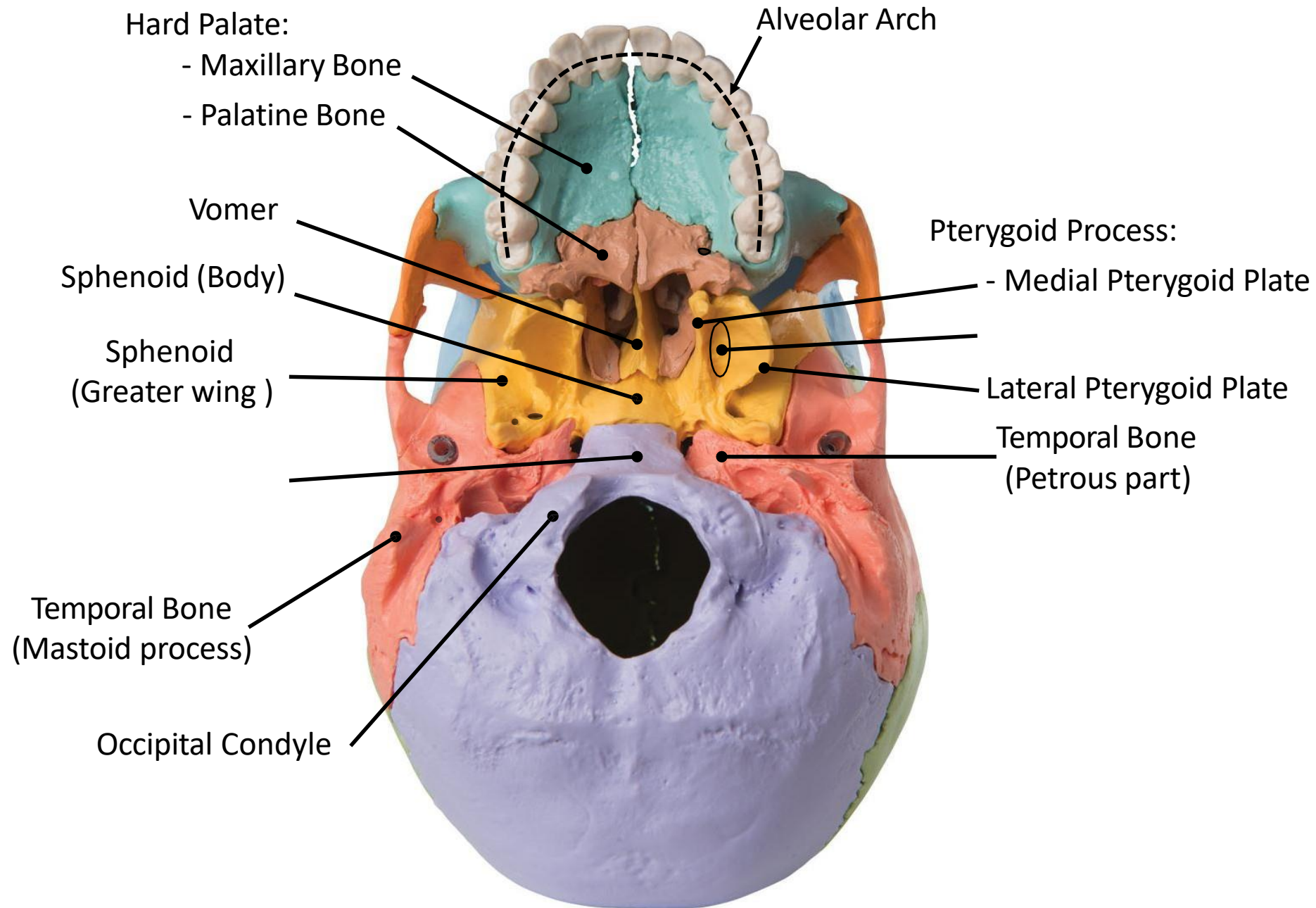
Inferior Nuchal Line



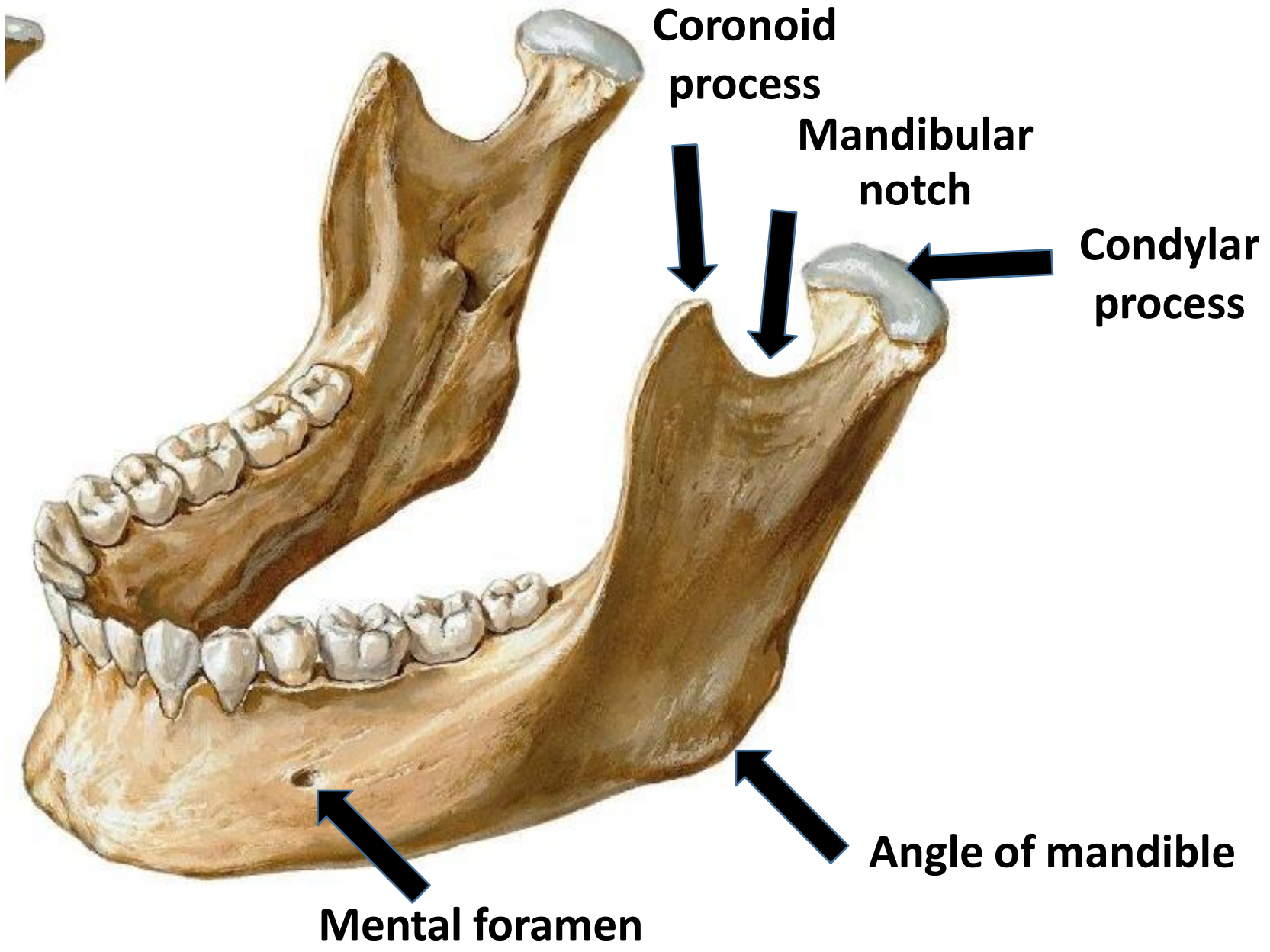












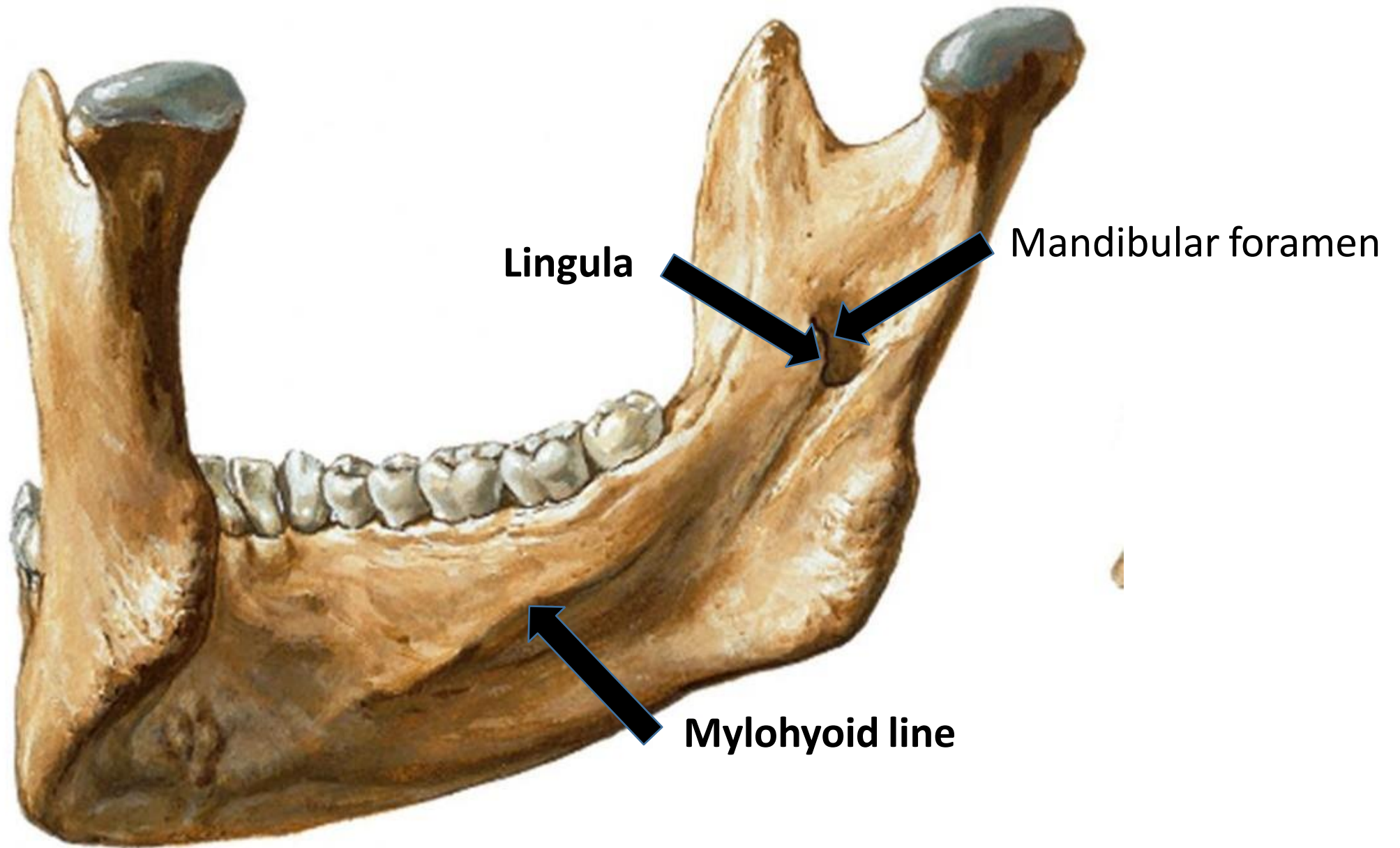
**Coronoid  
process**

**Mandibular  
notch**

**Condylar  
process**

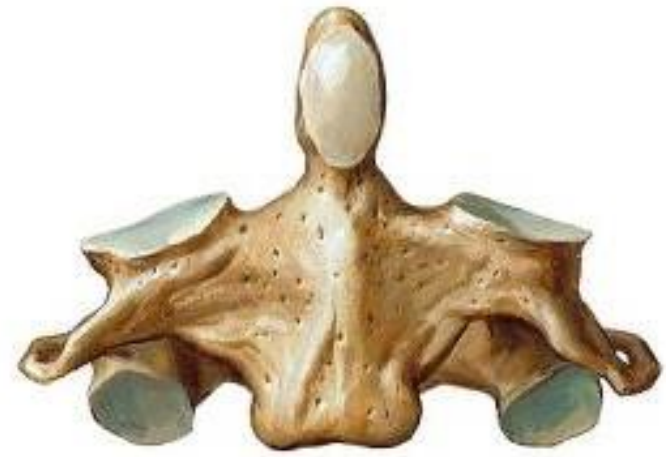**Angle of mandible**

**Mental foramen**

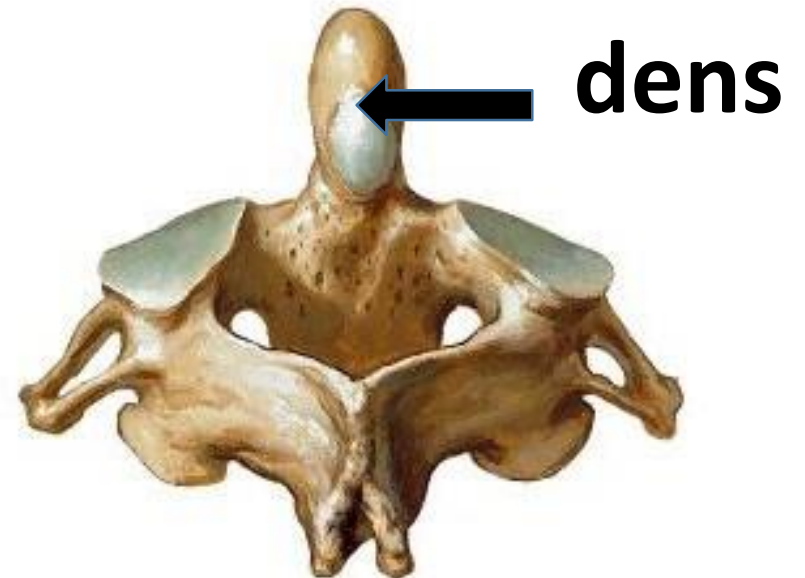
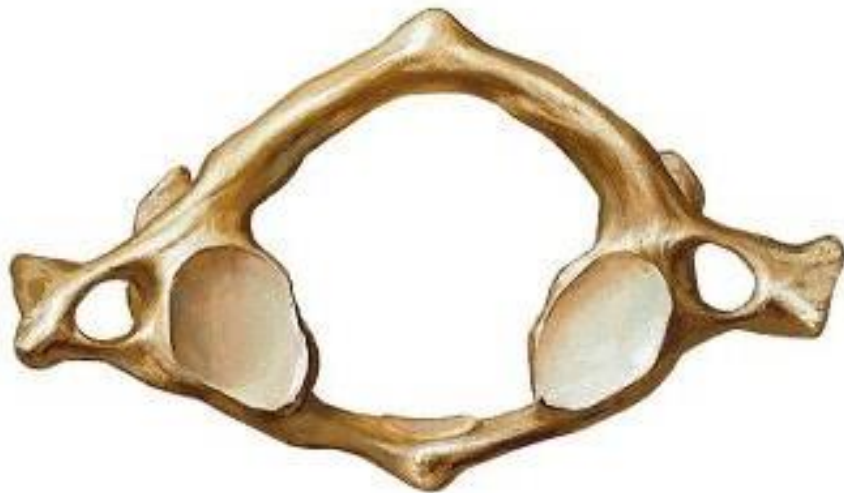


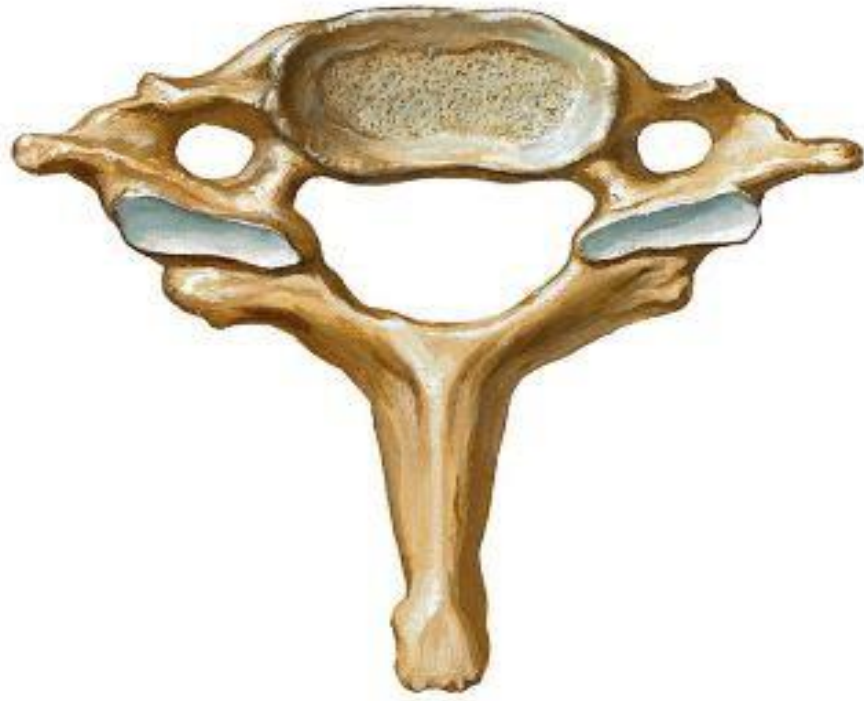
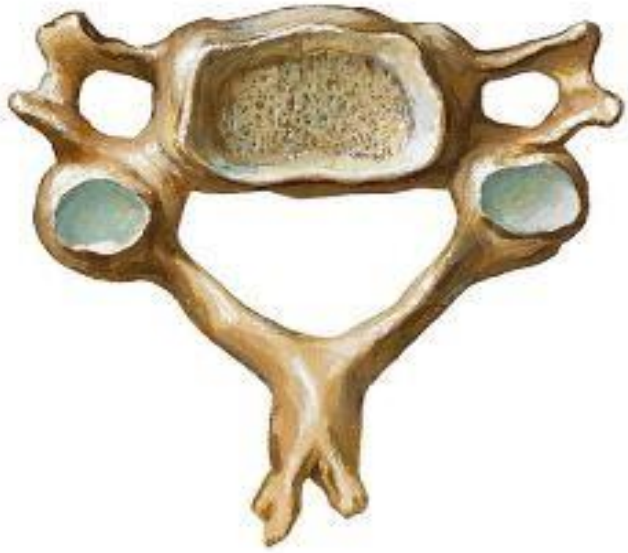**Atlas**



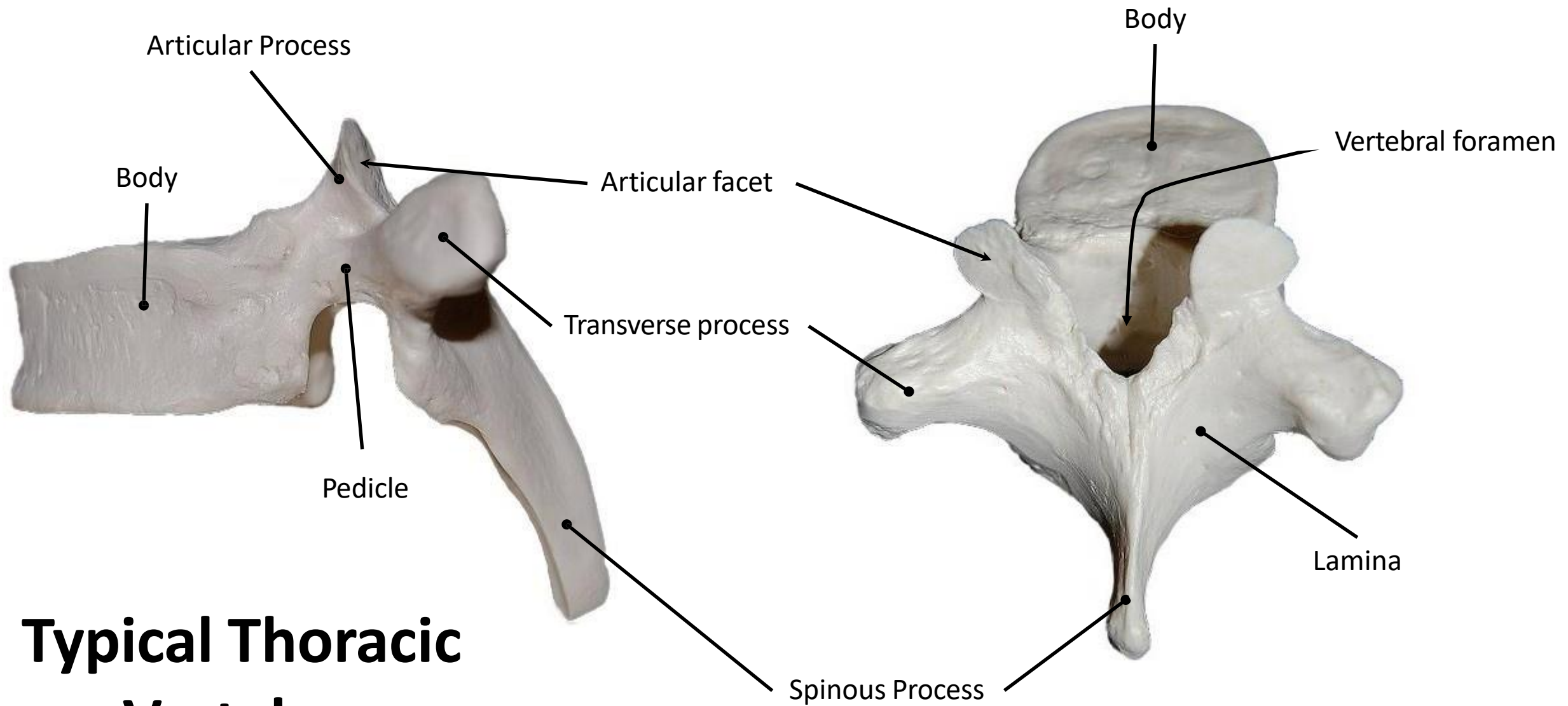
**Axis**



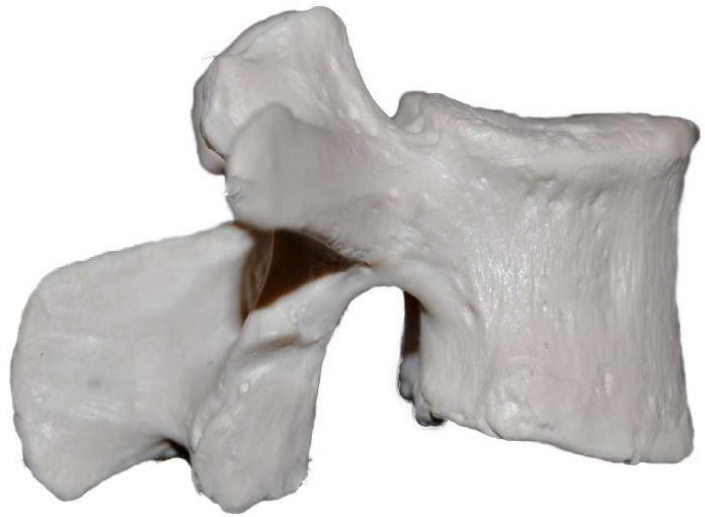

**7th cervical vertebra**

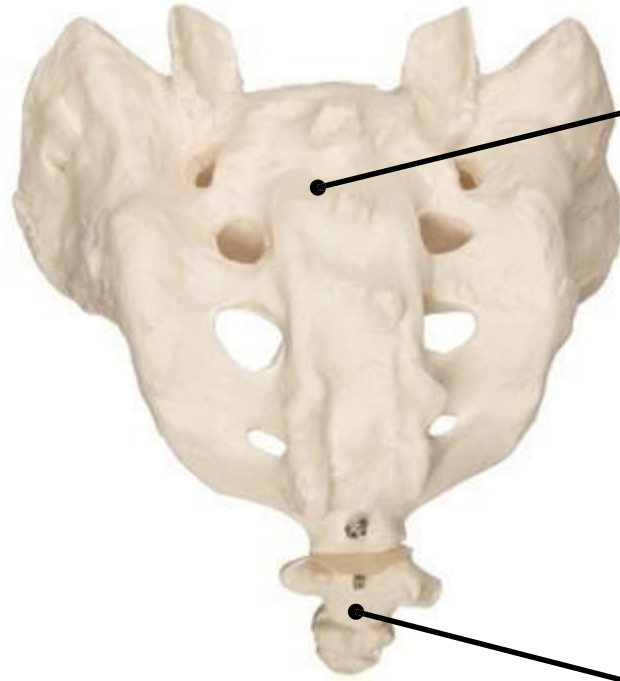
**Typical cervical vertebra**



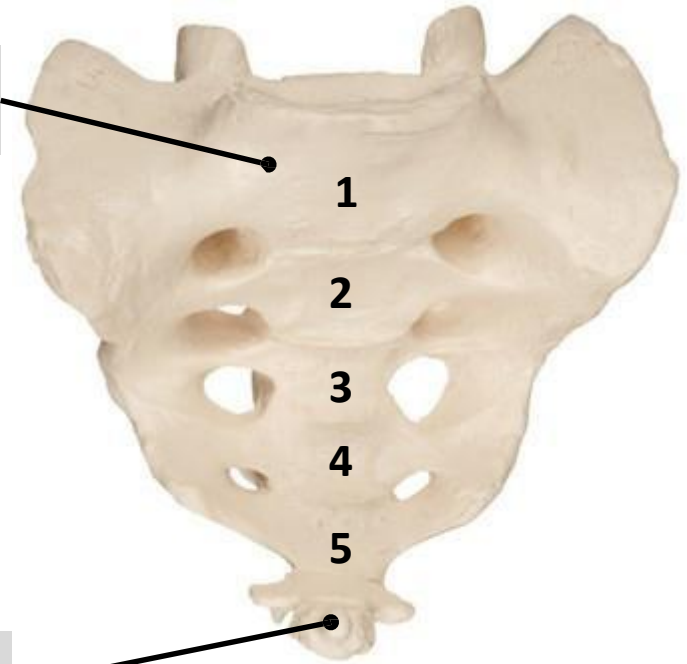
# Typical Thoracic Vertebra



**Lumbar Vertebra**

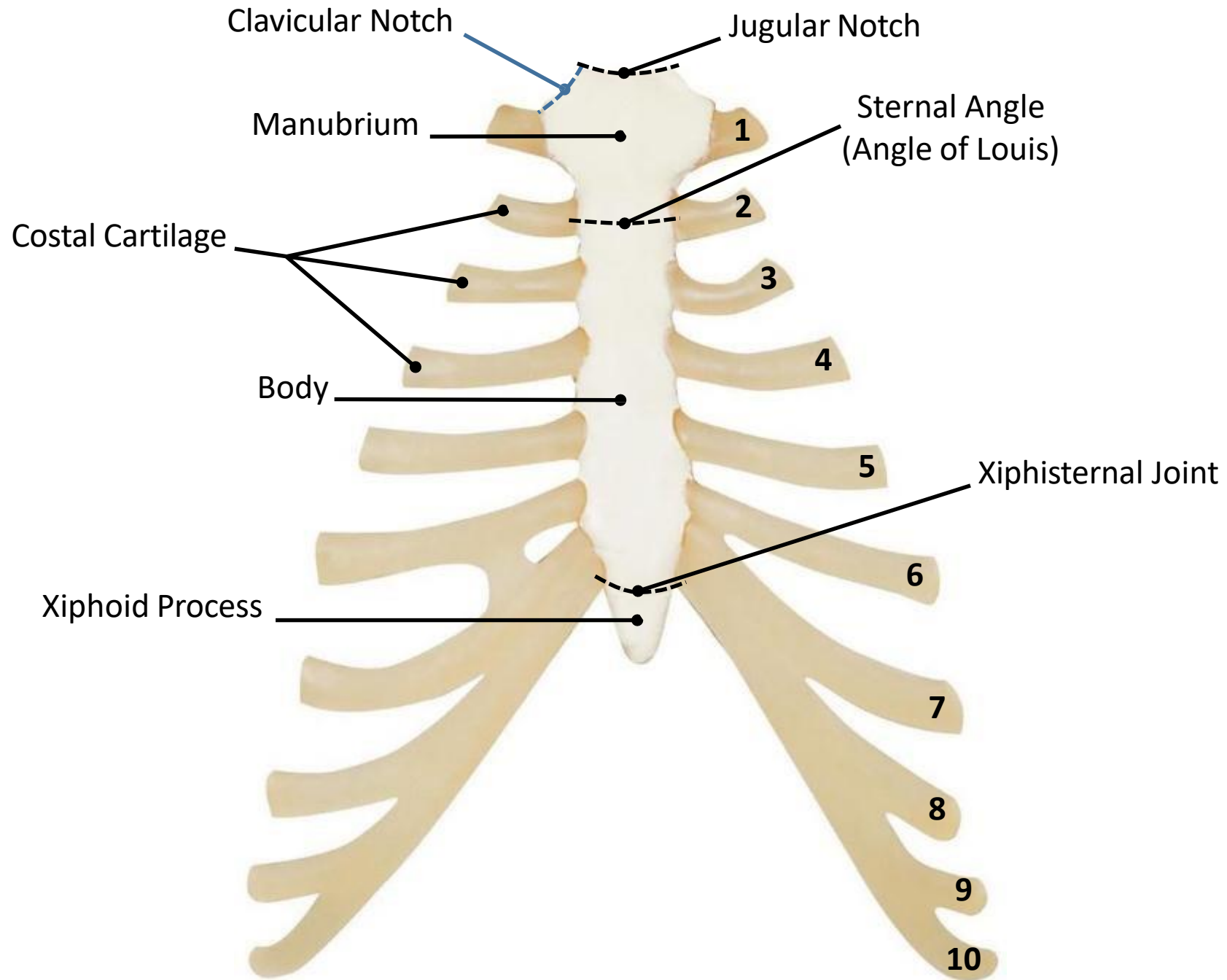


**Sacrum**



**Coccyx**

- 1
- 2
- 3
- 4
- 5



# Typical Rib

