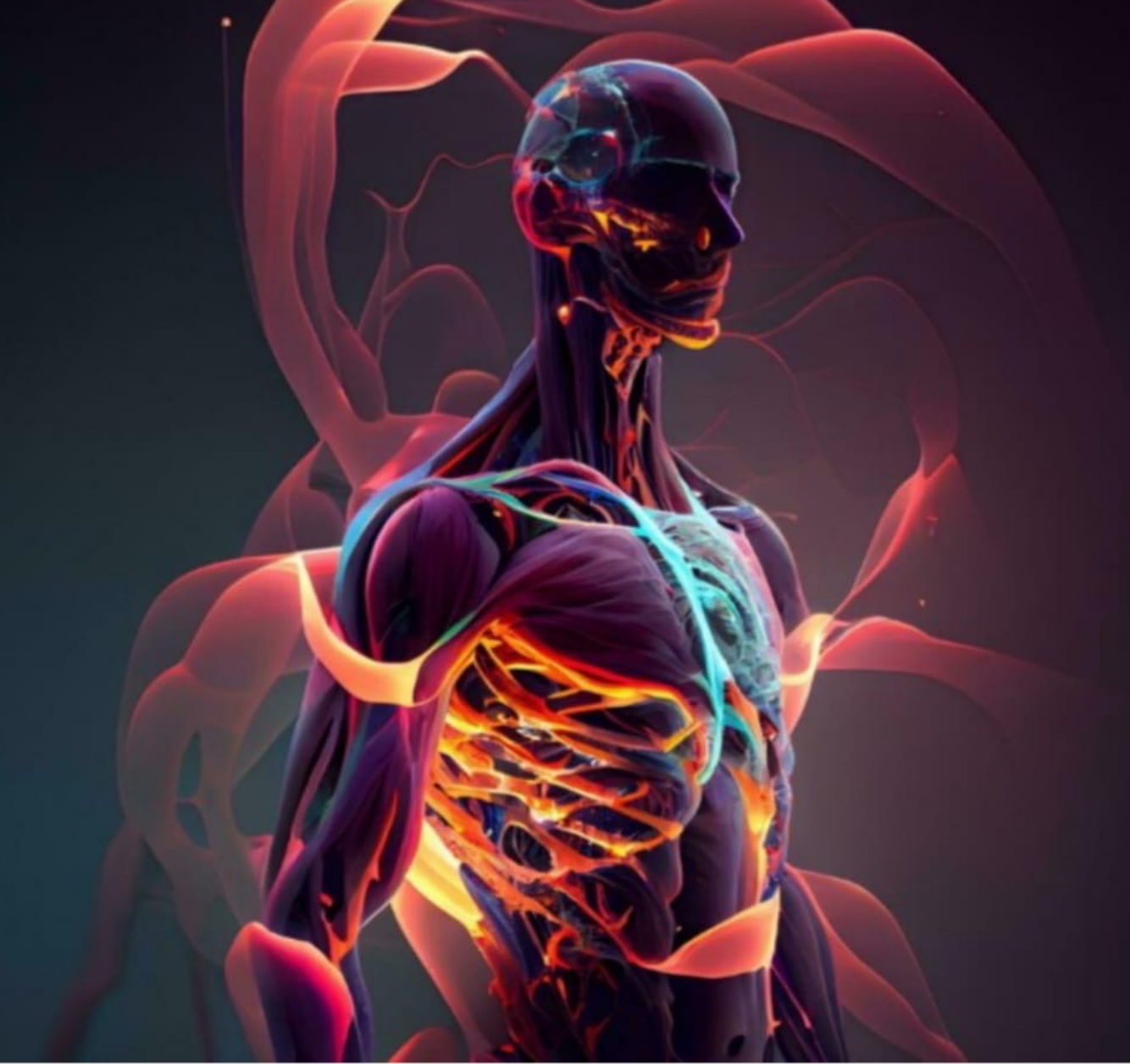



Lecture: Lab 6

Done By: Wafaa Alkarabshah

Lab 6

Muscles of Lower Limb

ASIS

Iliopsoas
↳ insertion: lesser trochanter

Sartorius

Quadriceps Femoris: → رابعة مكونة من أربع عضلات

Rectus Femoris

Vastus Intermedius → Deep to Rectus Femoris.

Vastus Medialis

Vastus Lateralis

→ Sartorius + Adductor longus + inguinal ligament → form a triangle [Femoral triangle] → contains femoral N. + A. + V.

Thigh

4 regions

Anterior

medial

< posterior >

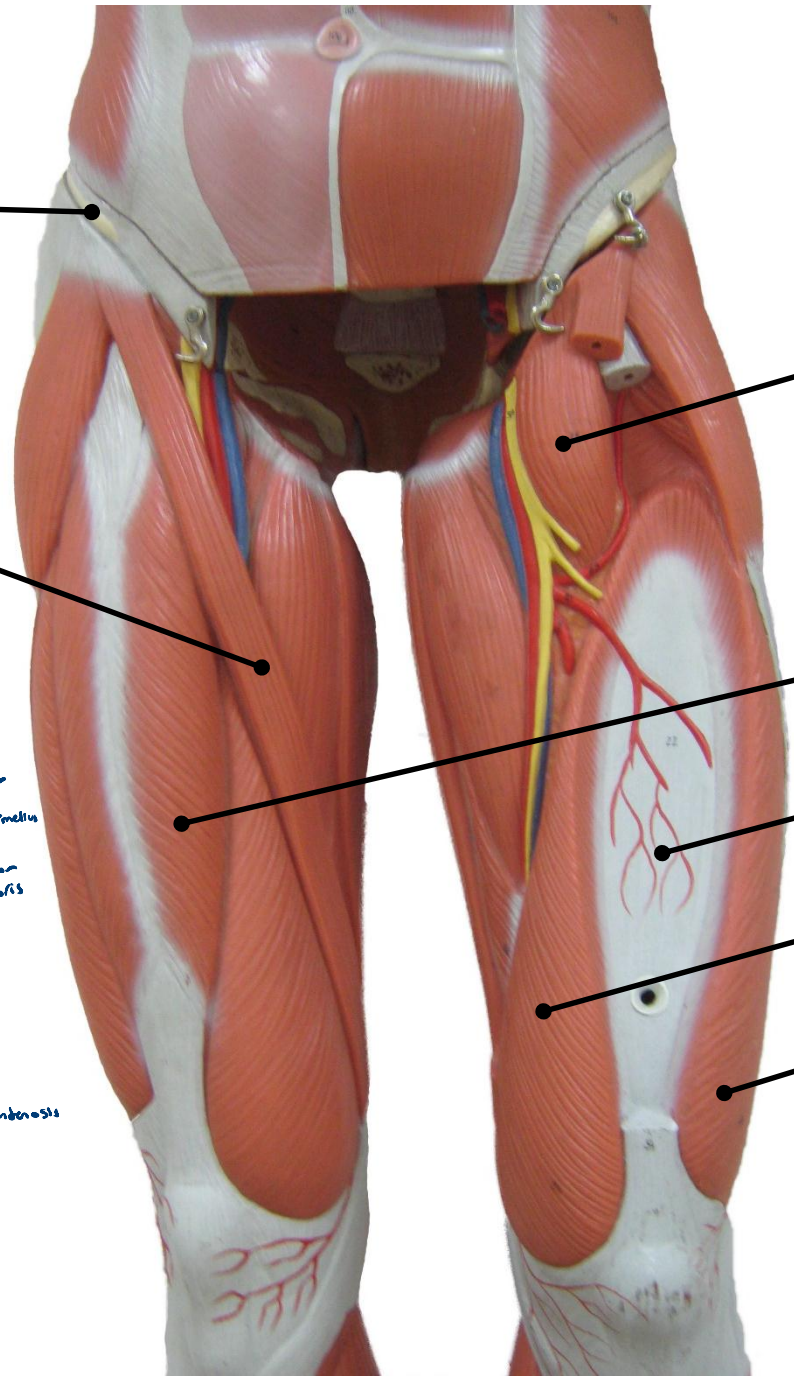
Callus hamstring muscles

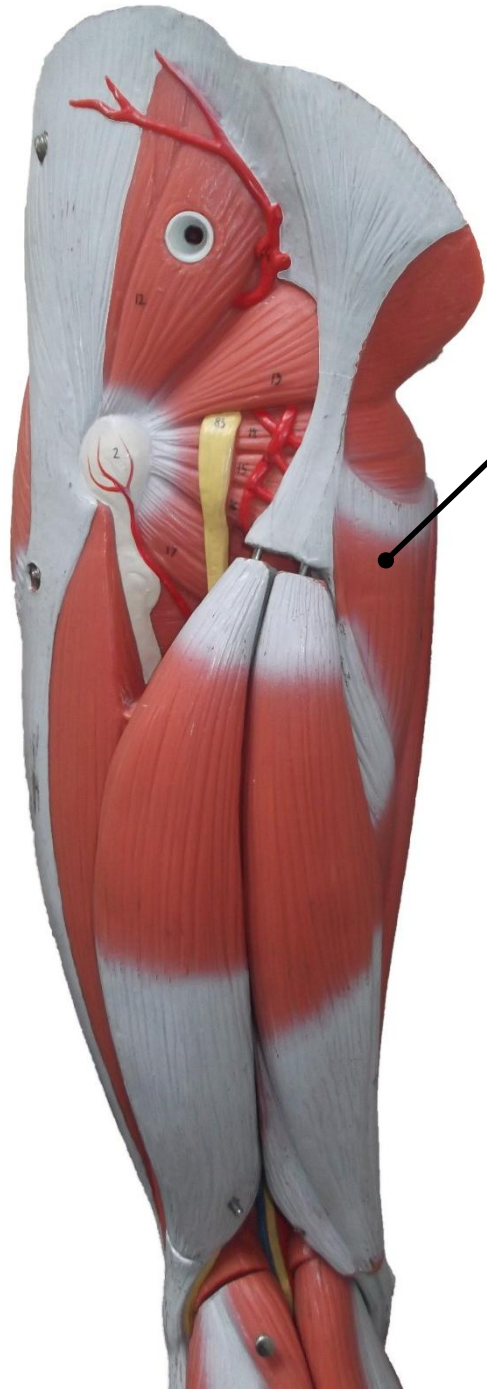
Biceps femoris

gluteal region
gluteus maximus
gluteus medius
gluteus minimus
piriformis
Gemelli superior
orbicular internus
Gemelli inferior
quadratus femoris

gracilis
Adductor longus
Adductor magnus

Quadriceps femoris
Rectus femoris
Vastus



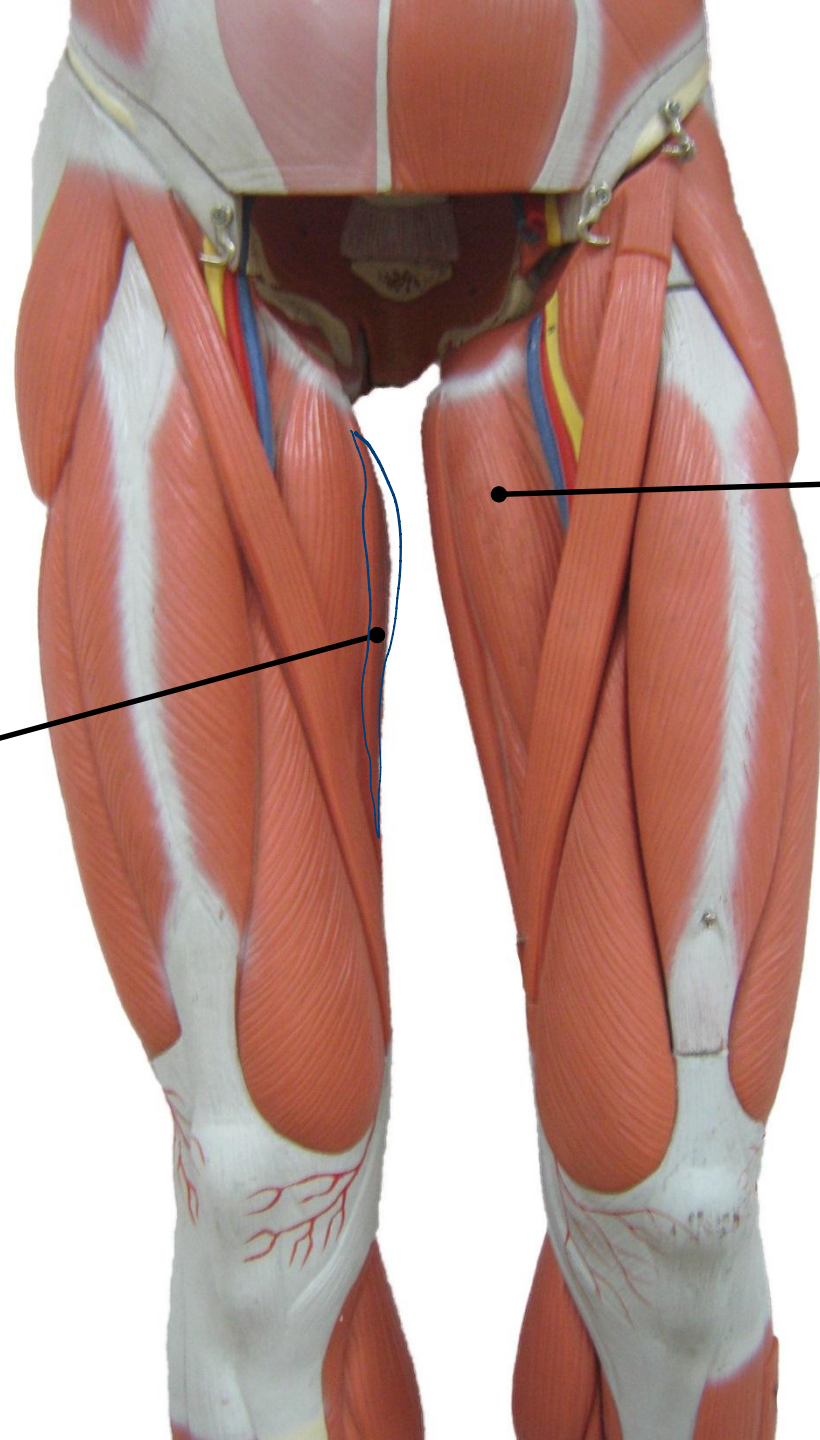


Adductor Magnus

medial towards the
back of the

Gracilis

most medial



Adductor Longus

إلى سالمته جي ار د medial



Gluteus Medius

↳ Deep to gluteus maximus
↳ superficial to gluteus minimus

Piriformis

Superior Gemellus

Greater Trochanter

Obturator Internus

Inferior Gemellus

Quadratus Femoris

Quadriceps femoris
↓
found anteriorly

تنسبه ما نخرب بين الكلي و ال

Sacral N

Gluteus Maximus

↳ located in the back of the pelvis.

Adductor Magnus

Gracilis

Biceps Femoris

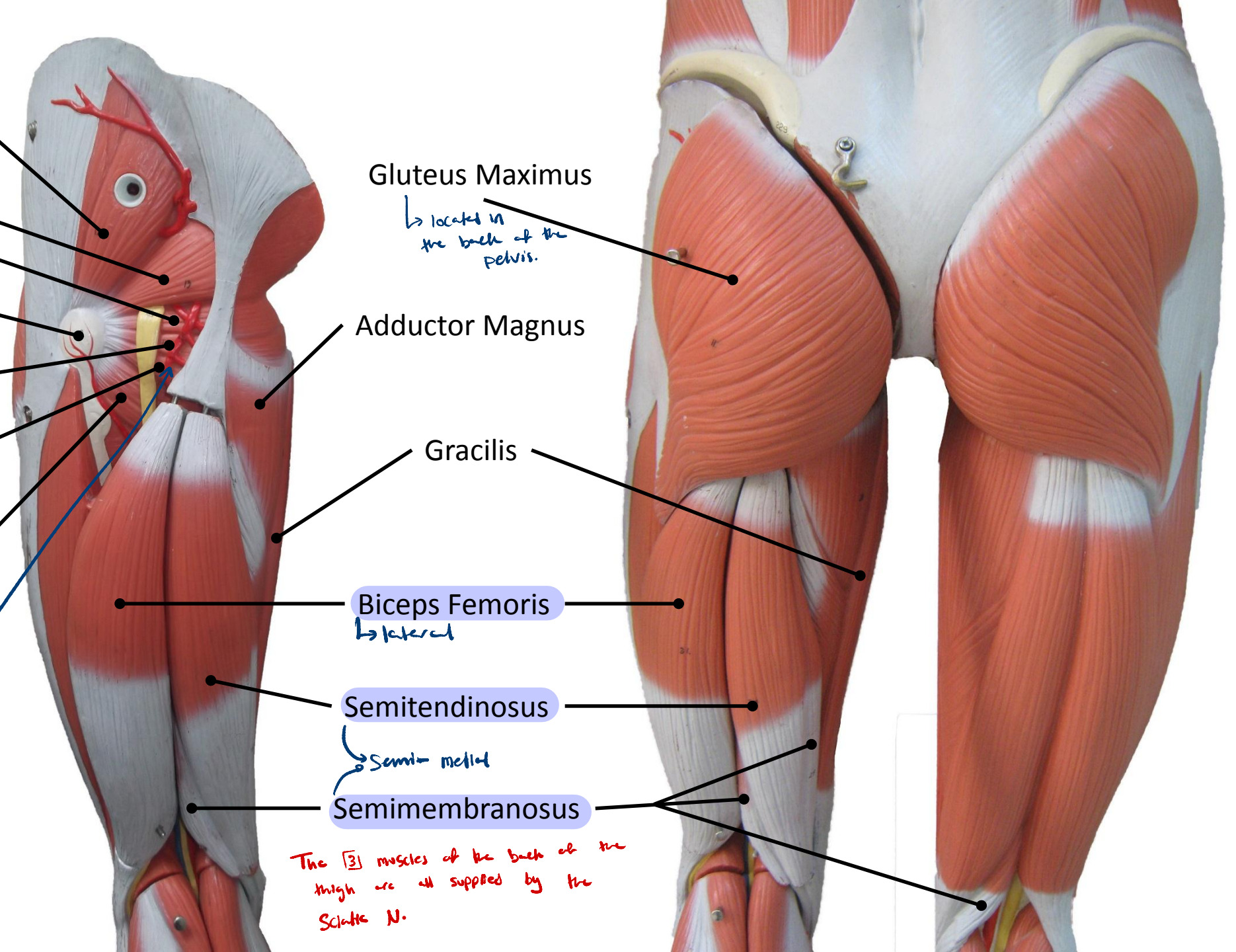
↳ lateral

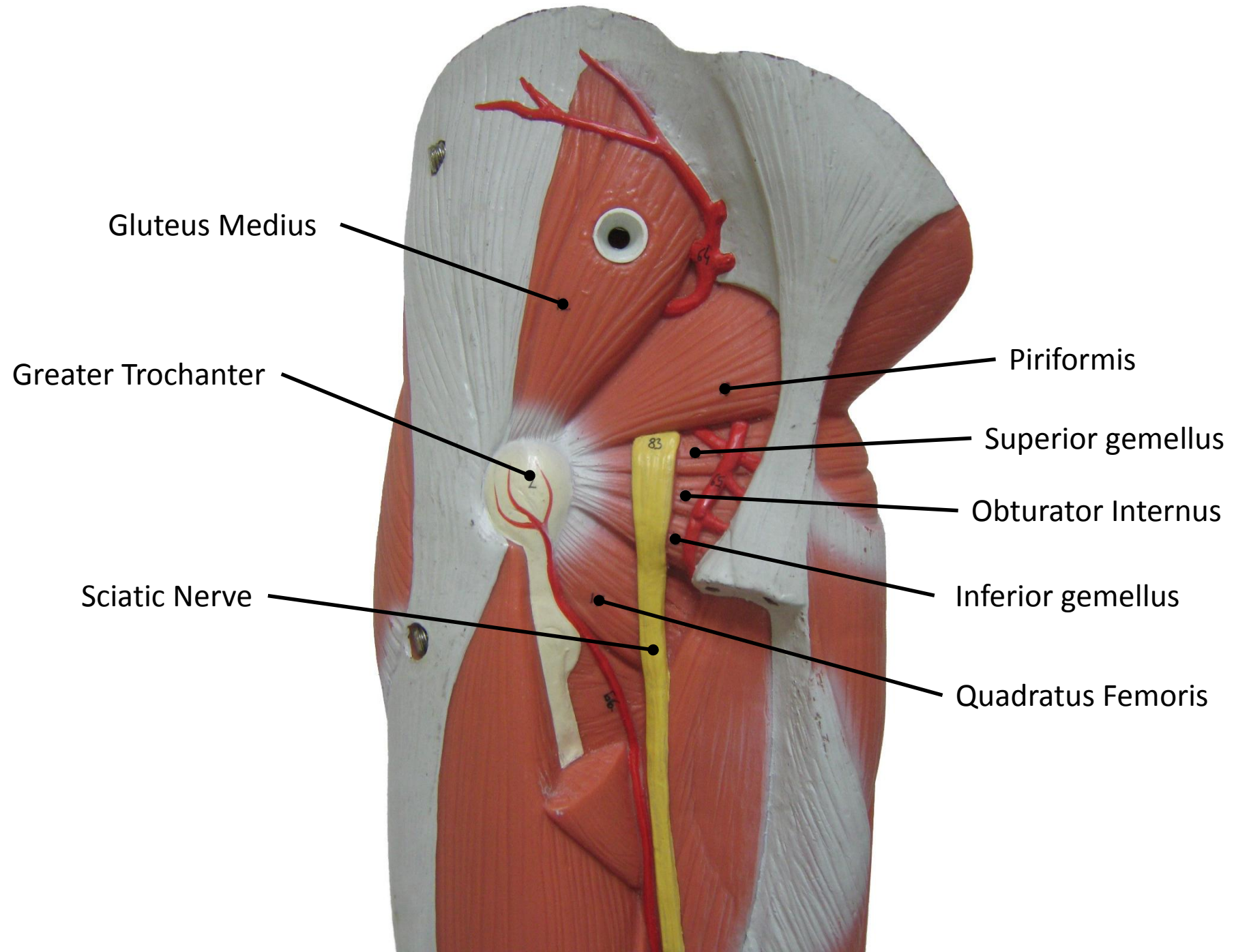
Semitendinosus

↳ Semi-medial

Semimembranosus

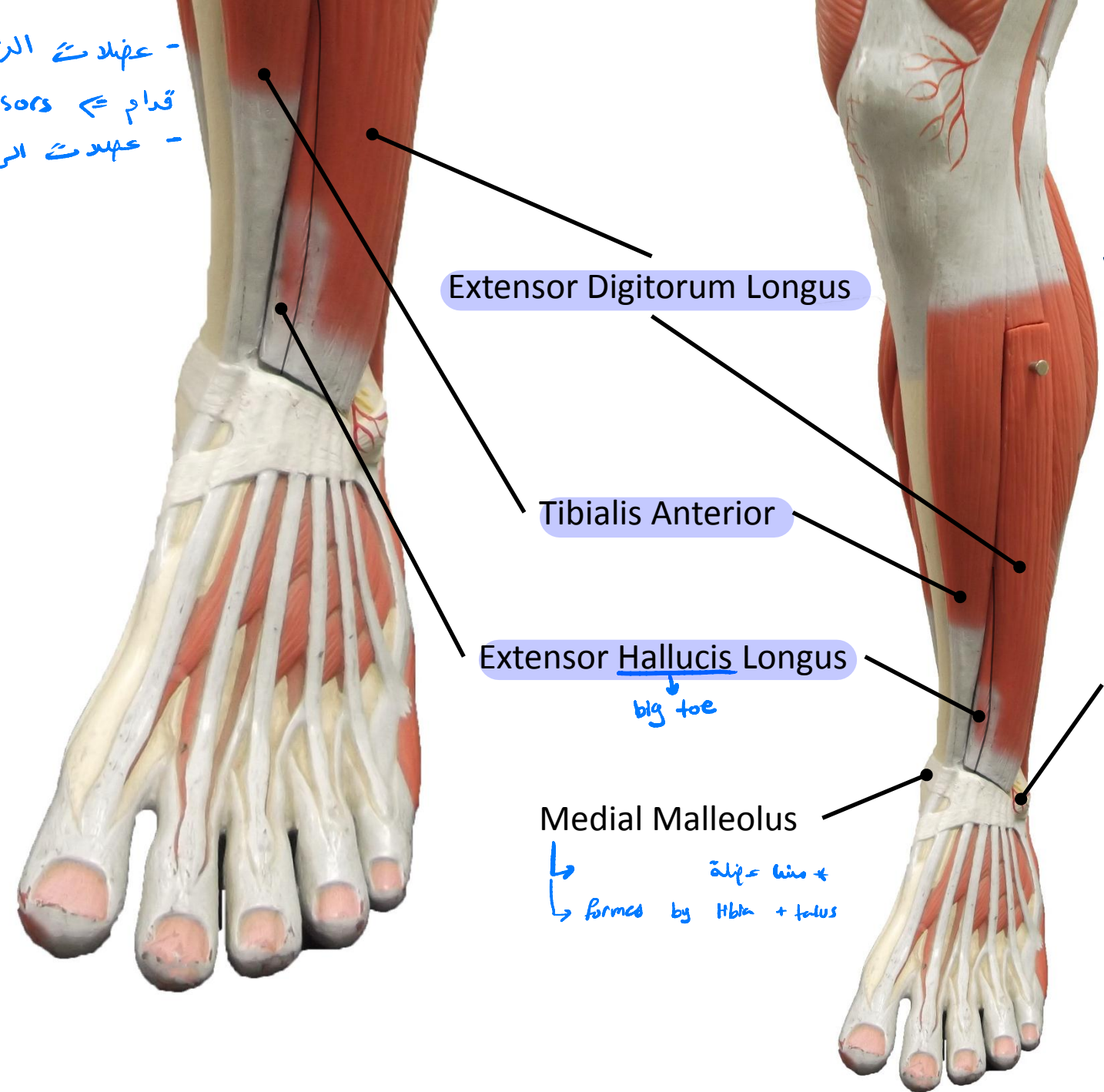
The [3] muscles of the back of the thigh are all supplied by the Sacral N.





* Remember: - عضلات الرجل من
 - قدام ⇨ extensors
 - عهده الرجل من ورا ⇨ flexors

* كل عضلات ال tibia تكون
 مالعة lateral ، لا يوجد عضلات
 tibia موجودة بالمعدية ، فال tibia في هذا
 المكان تكون subcutaneous [وتكون عينة للبر]



Extensor Digitorum Longus

Tibialis Anterior

Extensor Hallucis Longus

big toe

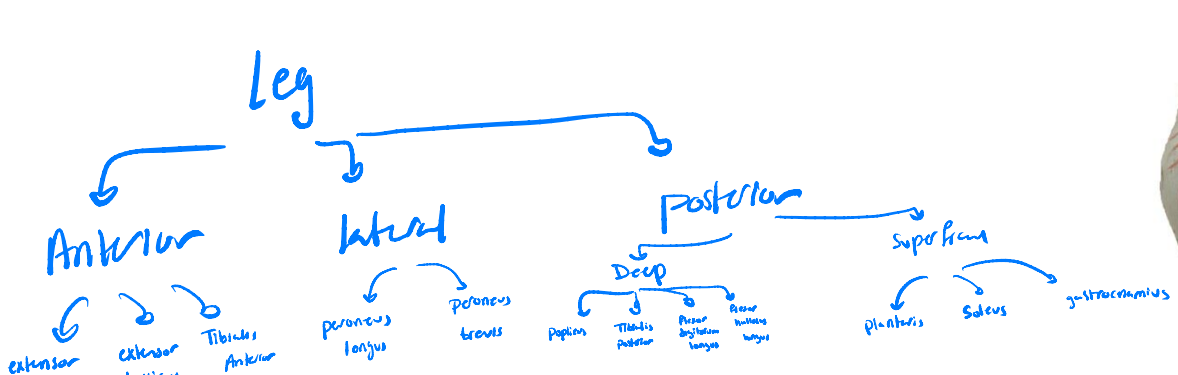
Lateral Malleolus

Medial Malleolus

↳ $\text{أظف} = \text{hio} +$
 ↳ formed by tibia + talus

Anterior :

N. supply : Anterior
 Tibial N.



Lateral :

N. Supply : Superficial Peroneal N.

Tibialis Anterior

Extensor Digitorum Longus

Lateral Malleolus

Gastrocnemius

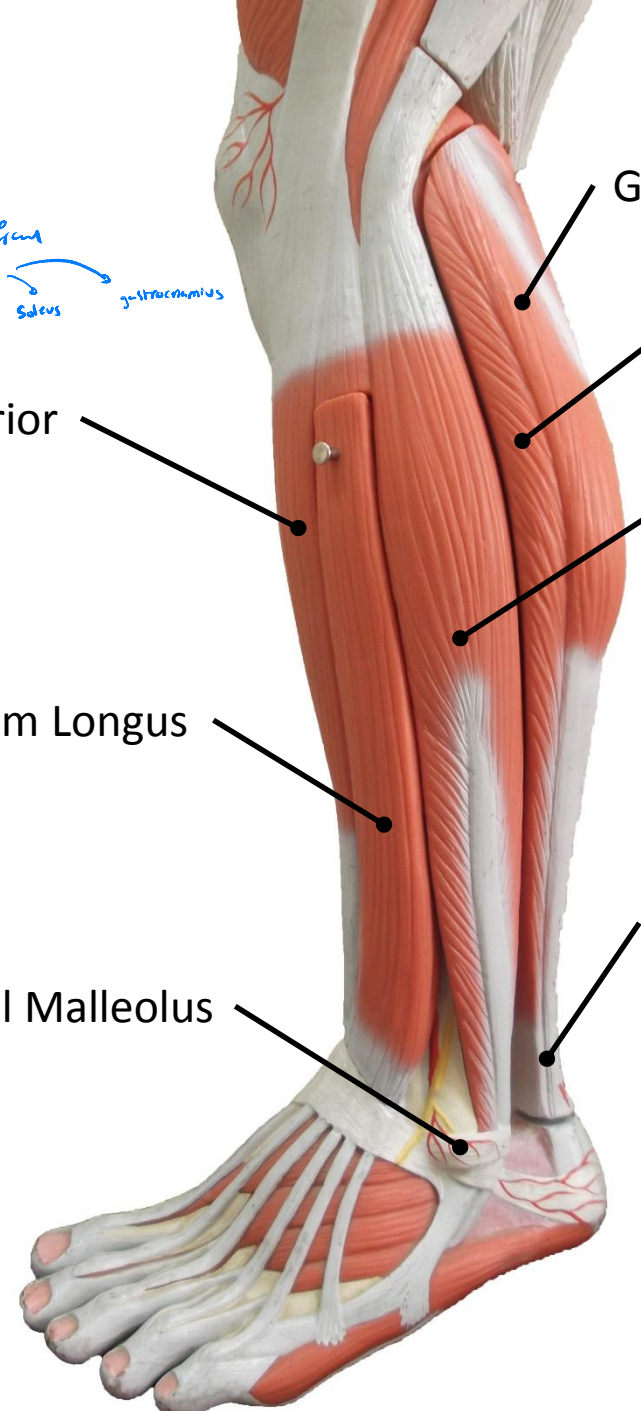
Soleus

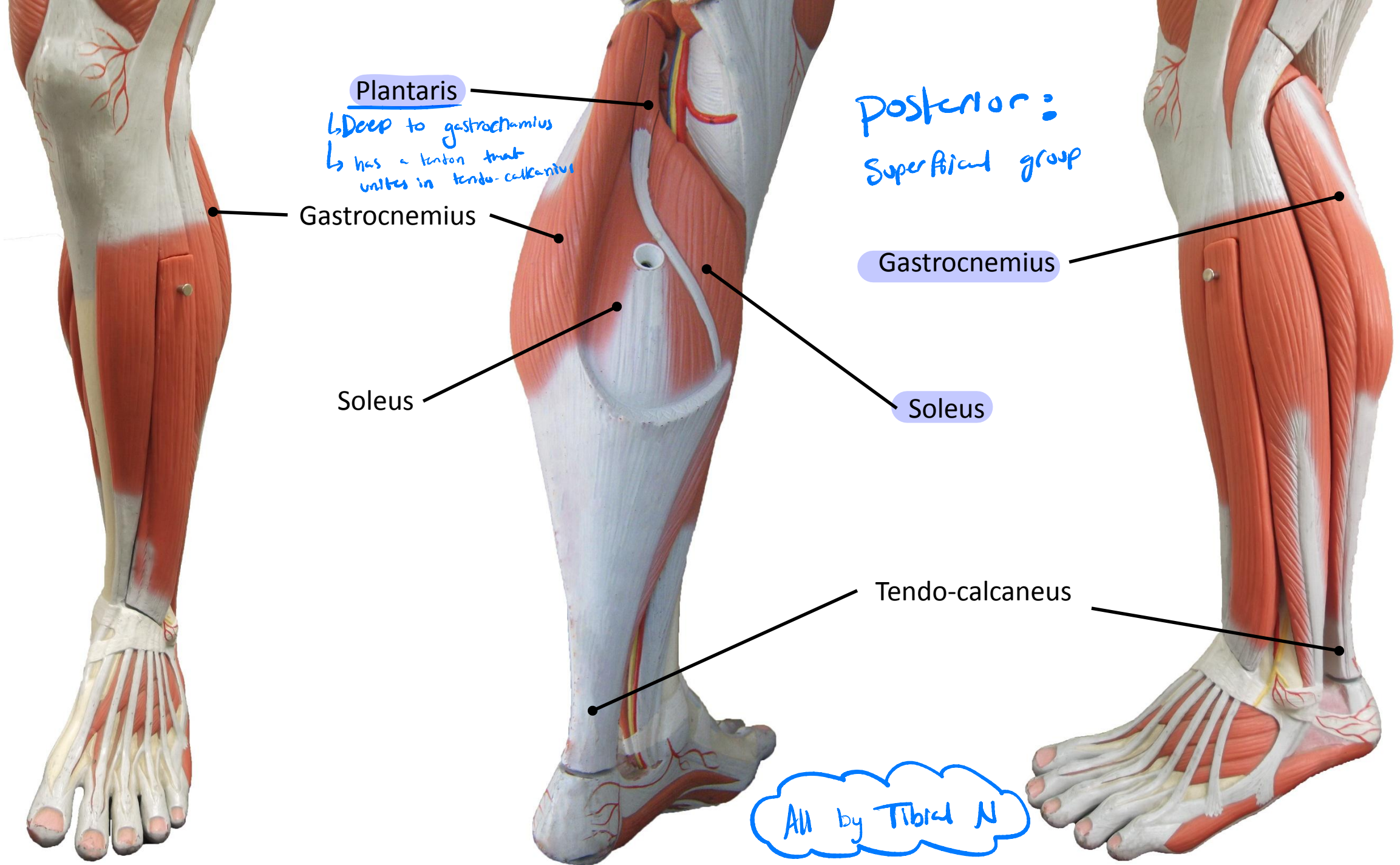
Peroneus Longus

↳ تكتمها موجودة
الـ peroneus brevis

Tendo-calcaneus

* peroneus => fibula





Plantaris

↳ Deep to gastrocnemius
↳ has a tendon that unites in tendo-calcaneus

Posterior:
Superficial group

Gastrocnemius

Gastrocnemius

Soleus

Soleus

Tendo-calcaneus

All by Tibial N

Gastrocnemius
(Lateral Head)

Gastrocnemius
(Medial Head)

Peroneus Longus

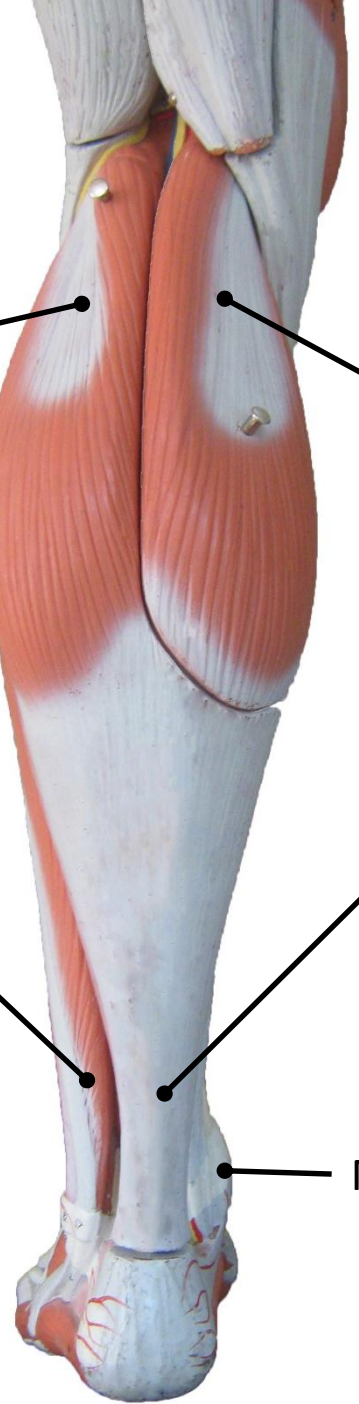Tendo-calcaneus

Medial Malleolus

① Soleus + ② gastrocnemius + ③ plantaris
unite in a tendon called



↳ has another name:
Tendo-achillis



Posterior :
Deep group
muscles

