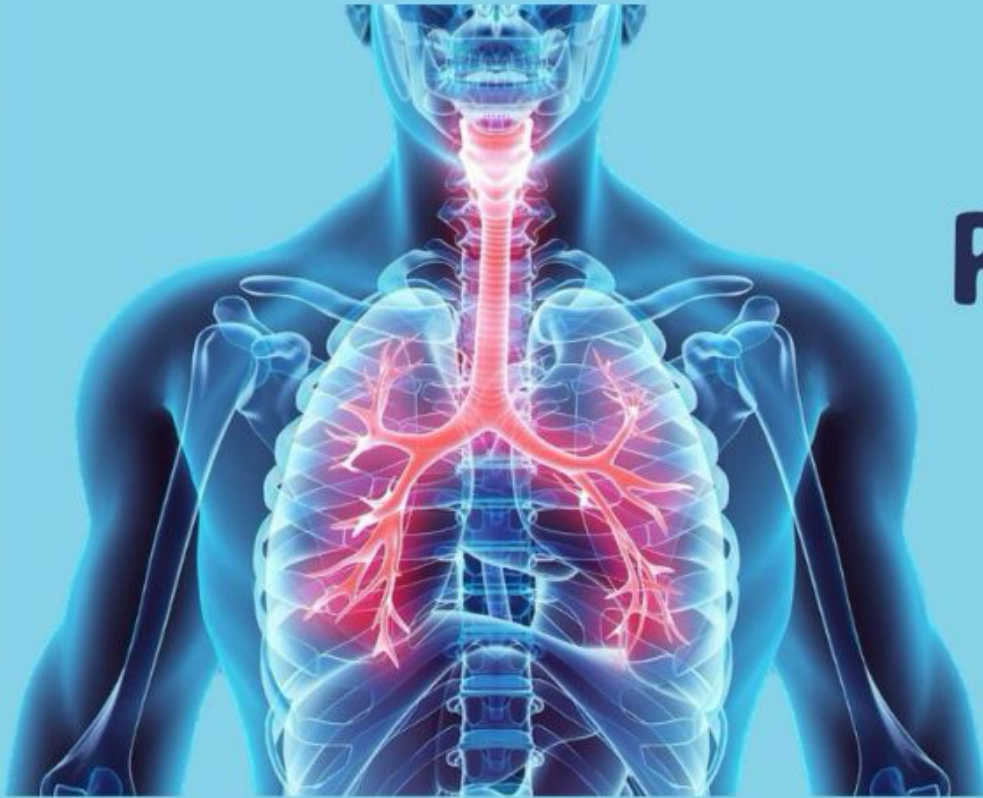

وَقُلْ رَبِّ زِدْنِي عِلْمًا



# RESPIRATORY SYSTEM

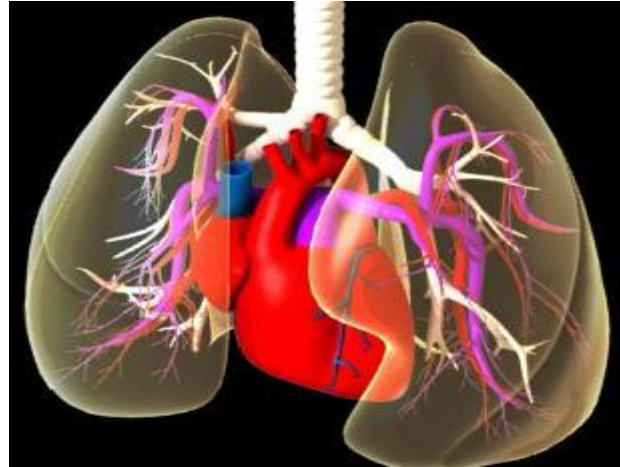HAYAT BATCH

SUBJECT : Anatomy Lab

LEC NO. : 2

DONE BY : Dana Khalaf ❤️

<http://www.medclubhu.weebly.com/>



# Respiratory system practical

By  
**Dr. Mohamed Fathi**  
**Ass. Prof. OF Anatomy**

## **Anatomy Lab 2:**

- \*Thoracic cage**

- \*lung & Pleura**

- \*Mediastinum**

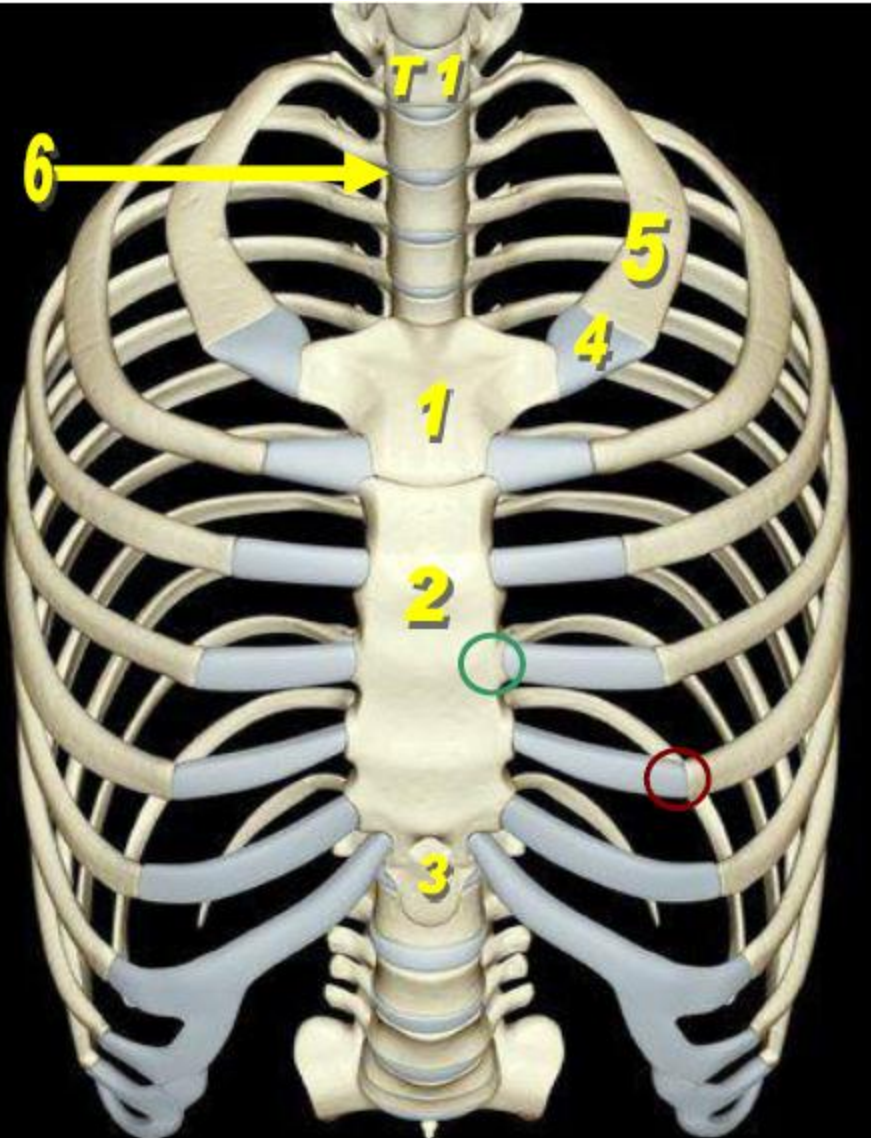
- \*Radiological Anatomy of the Thorax**

- \*Examples of congenital Anomalies**

# Bones of the thorax

posterior :Thoracic vertebrae 1-12

ribs وبينهم



1- Manubrium	} → Sternum
2- Body of sternum	
3- Xiphoid process	
4- 1 <sup>st</sup> costal cartilage	
5- 1 <sup>st</sup> Rib	
6- Intervertebral disc	
○ Sternocostal joint sternum, costal cartilage	بين
○ Costochondral joint costal cartilage, rib	بين

neck من ناحية neck *مدخل من ناحية* diaphragm *مخرج من ناحية*

Boundries	Thoracic inlet	Thoracic outlet
posterior	T1 vertebra	T12 vertebra
lateral	1 <sup>st</sup> rib	11 <sup>th</sup> and 12 <sup>th</sup> rib
Anterior	Manbrium sterni	Costal margin and xiphoid process



# STERNUM

ال clavicle بتقرب من manubrium عند clavicular

**\*Type:** flat bone.

**\*Site:** Anterior chest wall

1. Jugular notch. } On the upper surface of  
2. Clavicular notch. }

**\*Parts:** Manubrium sterni, body and Xiphoid process

**\*Joints formed by this bone:**

1- Sternoclavicular joint .

(saddle synovial J) ← بشبه سرج الحصان

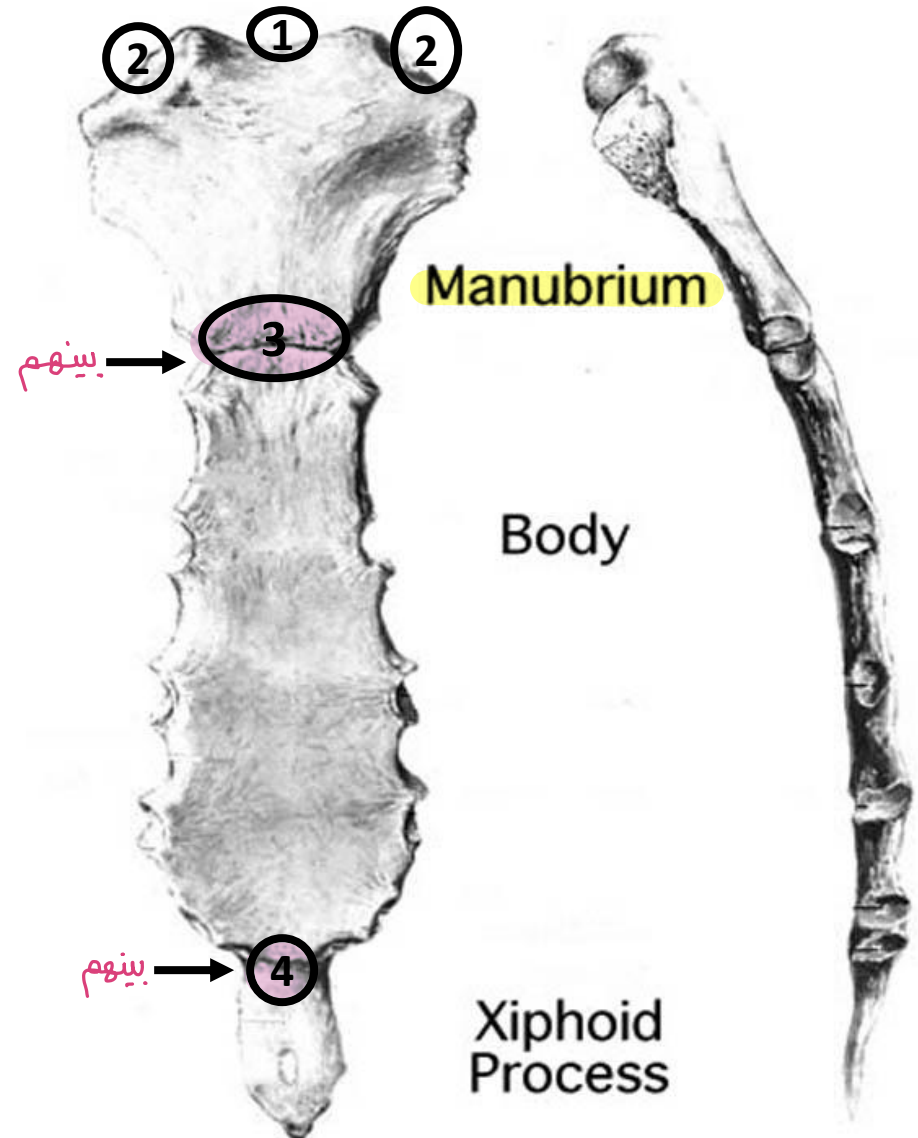
2- sternocostal joints.

3. Manubrio-sternal joint (sternal angle)

(2ry cartilagenous J).

4. Xiphi-sternal joint

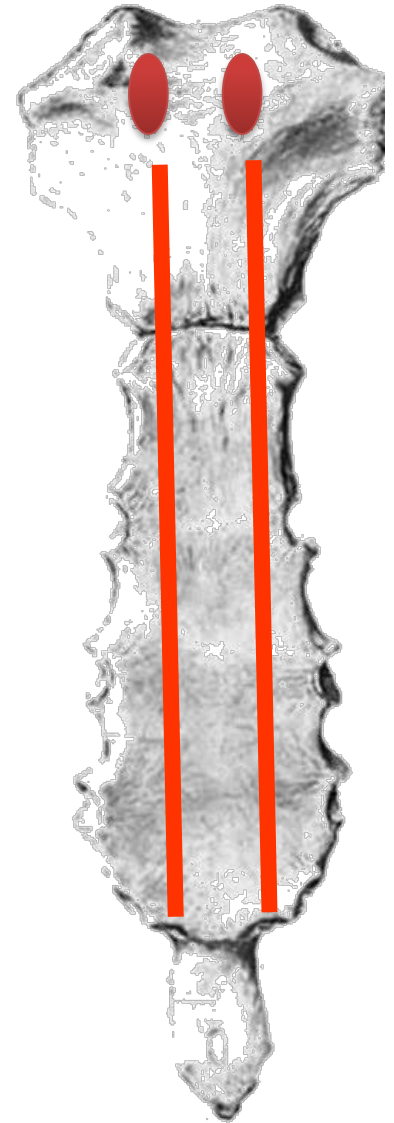
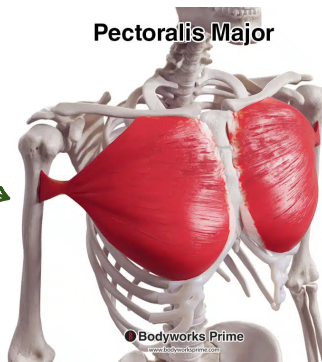
(2ry cartilagenous J)



## Anterior surface

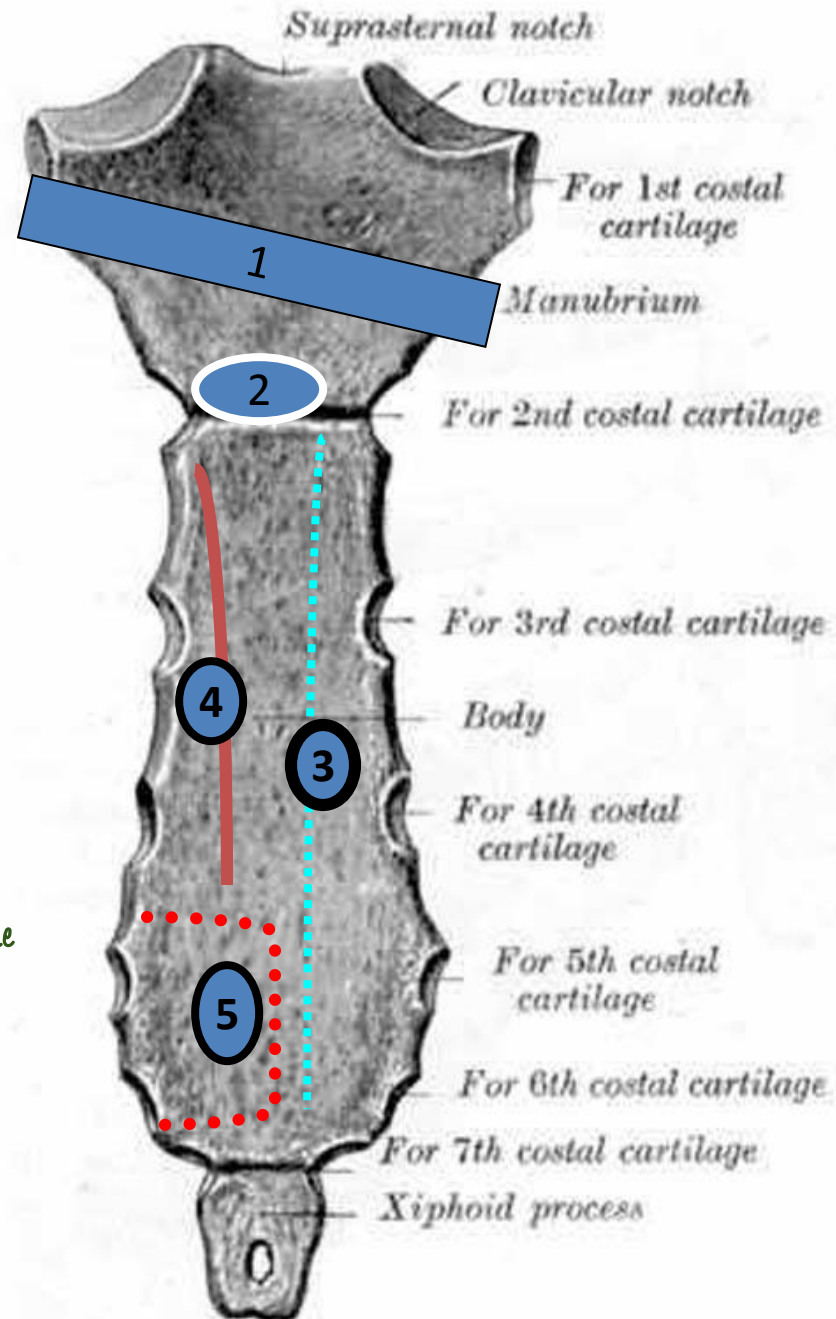
the structure attached  
to the marked area:

**Pectoralis major muscle**



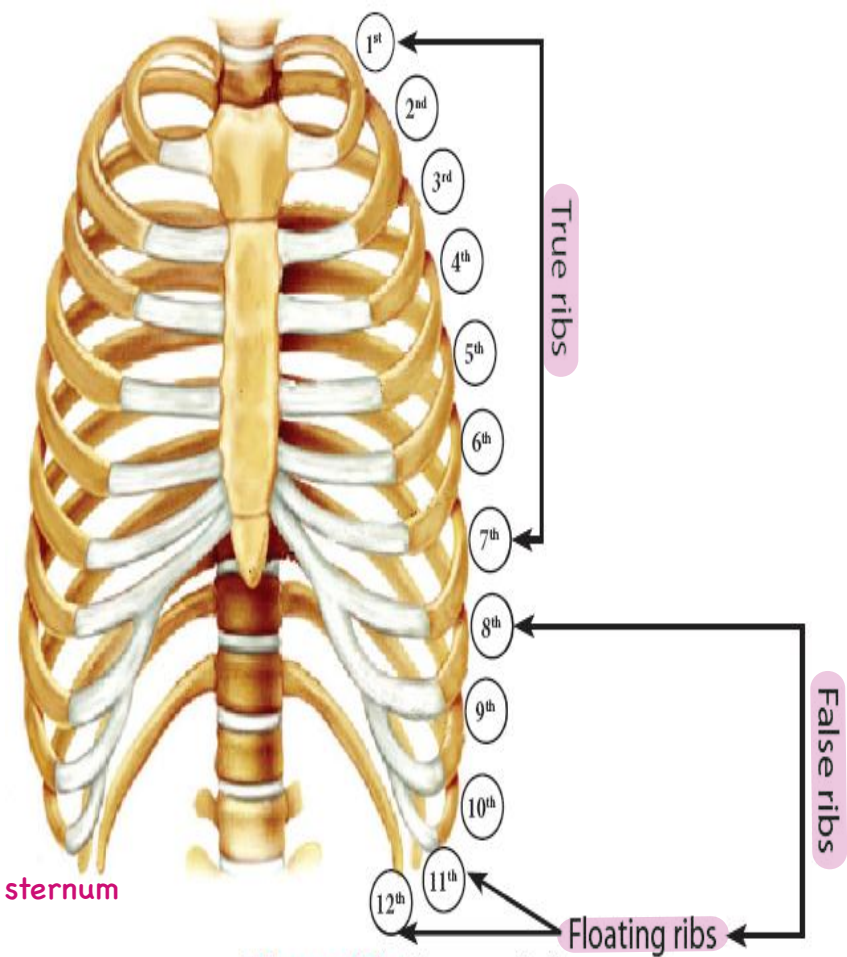
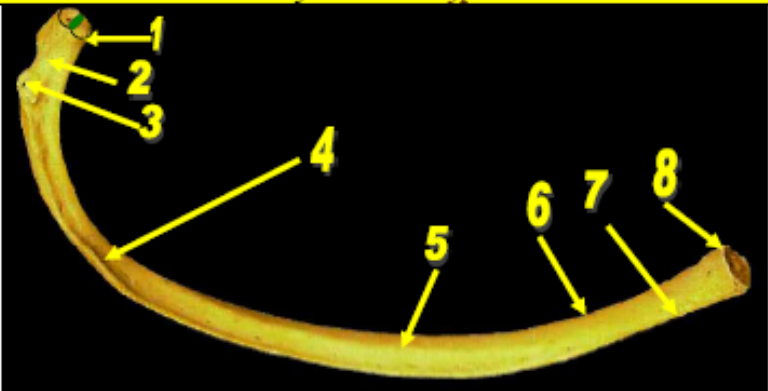
the structure related to  
the back of sternum  
(the marked area)

1. **Lt. brachio-cephalic V.** upper part
2. **Arch of aorta.** Lower part
3. **Right lung & Rt. Pleura.** Body
4. **Left lung & Lt. pleura.** Lower part of the left side
5. **Heart & pericardium.**



**Typical rib**  
!! Not Atypical

# 12 RIBS



Ribs من بتقرب من sternum

Figure (8): Types of ribs.

بتقرب لل  
vertebrae  
من ورا

**Joints formed by the rib:**  
**1-costovertebral joint: plane synovial joint.**  
**2-costotransverse joint: plane synovial joint.**

- 1-Head Sternocostal joint sternum,costal cartilage بين
- 2-Neck Costochondral joint costal cartilage, rib بين
- 3-Tubercle in posterior end
- 4-Costal groove intercostal van ناحية ناحية ويكون بمشي فيه
- 5-Inner surface
- 6-Upper border rounded
- 7-Lower border Sharp
- 8-Anterior end (concave)
- 9-Rib angle
- Two articular demifacets separated by a crest



# How to identify a rib?

Look to the **head** of the rib

Has **2** facets

Look to the shaft

*upper + lower border ✓*

Has **outer surface** & **inner surface** |

**Typical rib**

*upper + lower surface ✓*

Has **supero-lateral** & **infero-medial** surfaces  
**(rests on table)** \

**Second rib**  
*Atypical*

Has **1** facet

Look to the shaft

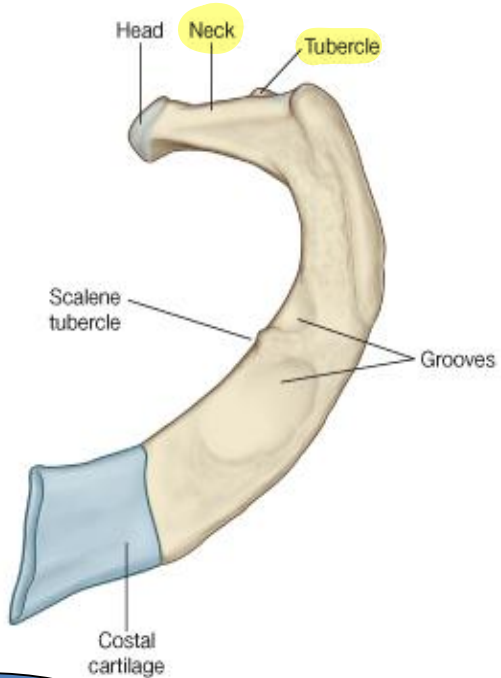
*neck + tubercle ✓*  
Has **superior** & **inferior** surfaces  
**(flat & short)** —

**First rib**

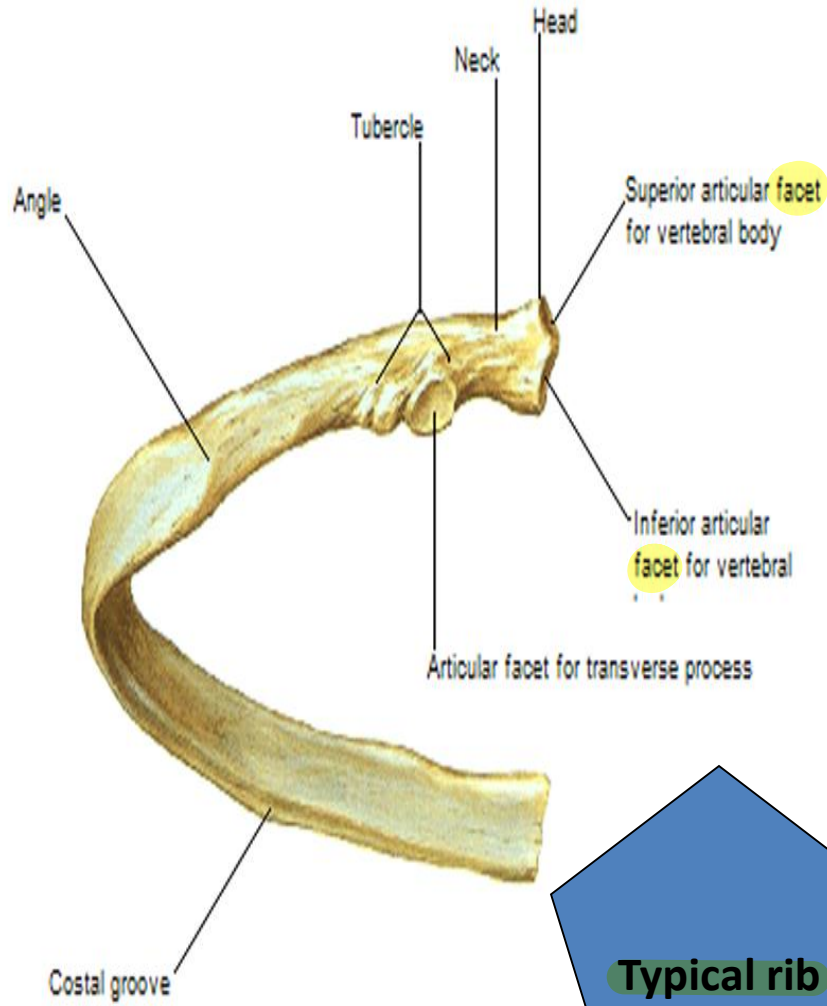
Has **no neck,**  
**no tubercle**

**Floating ribs,**  
**11 & 12**

Rib I



**First rib**



**Typical rib**

Rib XII



**Floating rib**

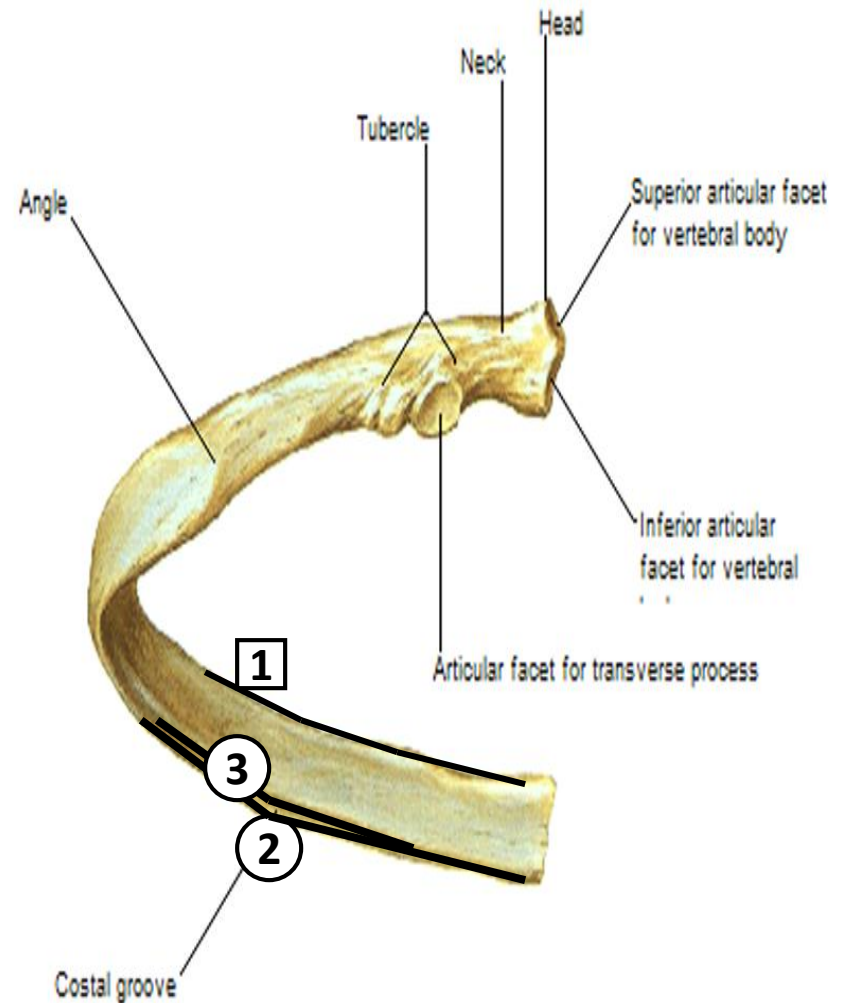
The structure attached to:

1. External, internal & inner most intercostal muscles. *Upper Border*
2. External intercostal muscle. *Lower Border*

The structure related :

Costal groove:

3. Posterior intercostal vein & artery and intercostal nerve. → VAN



# First Rib:

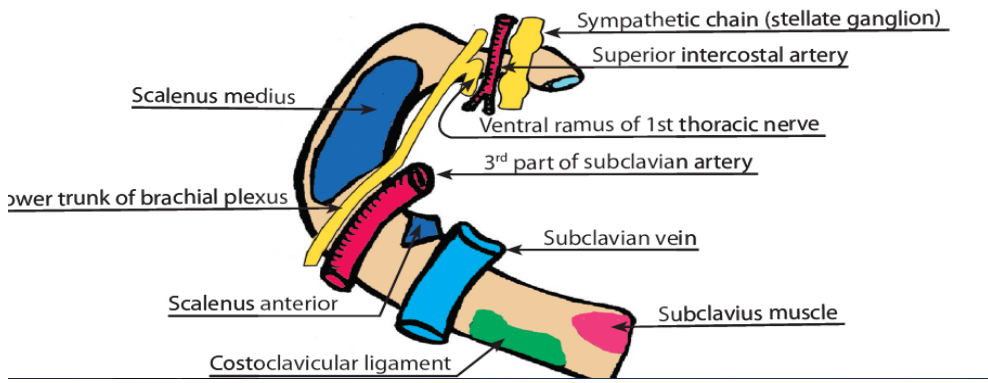
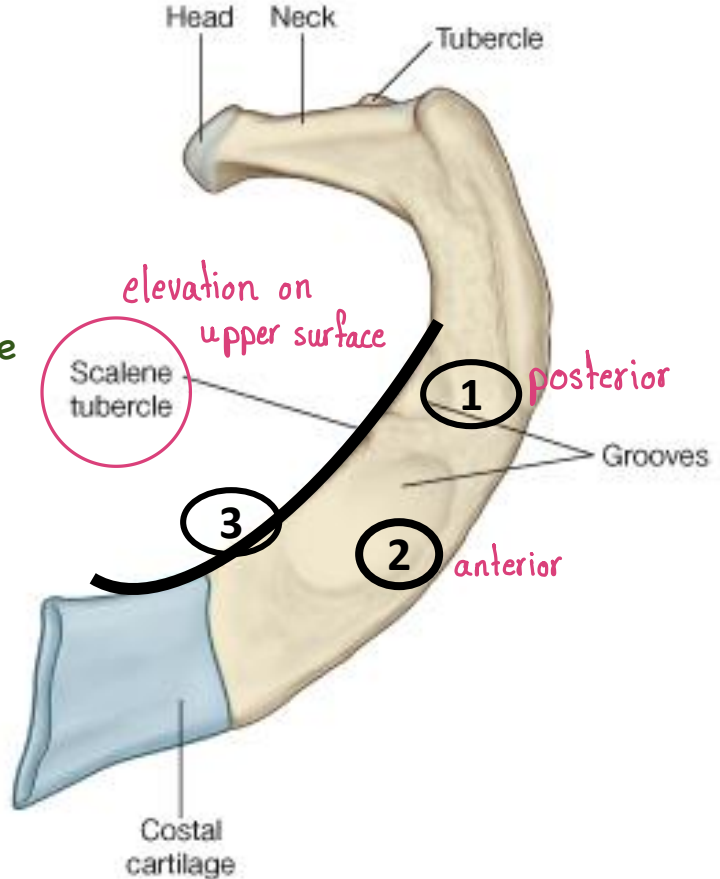
The structure related to the marked area.

- 1. Subclavian artery.
  - 2. Subclavian vein.
- } Related to upper surface

\*The structure attached to the marked area.

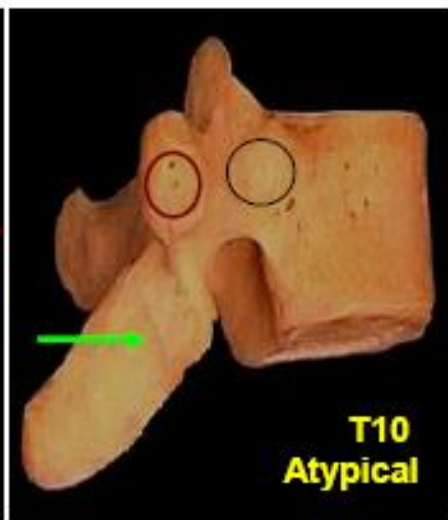
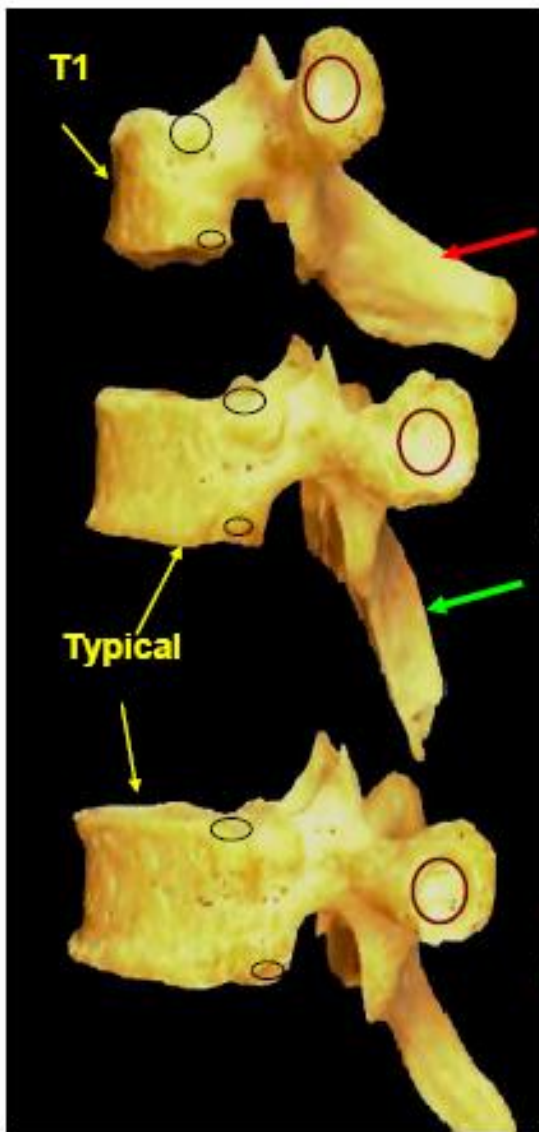
- 3. **Suprapleural membrane** inner Border

Rib I





# THORACIC VERTEBRAE



<i>Typical Thoracic vertebrae-</i> Upper and lower demifacet ◯
<i>Atypical Thoracic vertebrae-</i> one complete facet ○
<i>T1-</i> Upper complete facet and lower demifacet ◯
→ <i>T1-</i> Horizontal spine
→ Oblique spine
○ Articular facet on transverse process

12 thoracic vertebra  
 2-9 typical  
 1,10,11,12 Atypical

low, directed downward, pointed, short spine يكون ال

+ complete facet on transverse process

- 1 complete facet on body
- Demifacet on lower border
- Complete facet on transverse process
- atypical ( first )
- complete facet on body
- Complete facet on transverse process
- atypical (10)
- complete facet on body
- ✗ on transverse process
- (11/12)

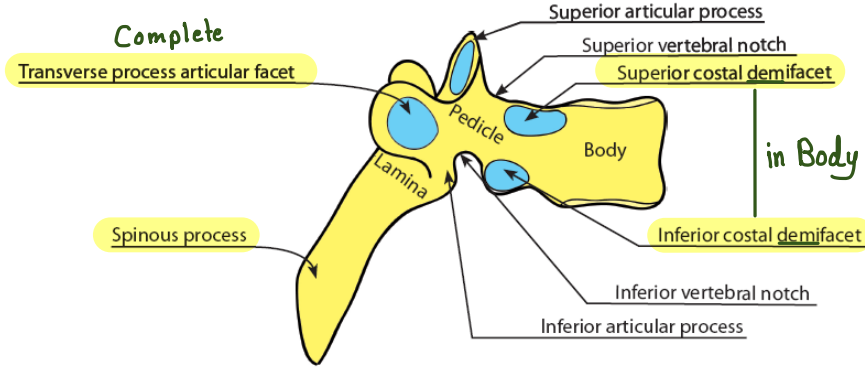


Figure (3): Typical thoracic vertebra, lateral view.

Complete circular costal facet for head of 1<sup>st</sup> rib

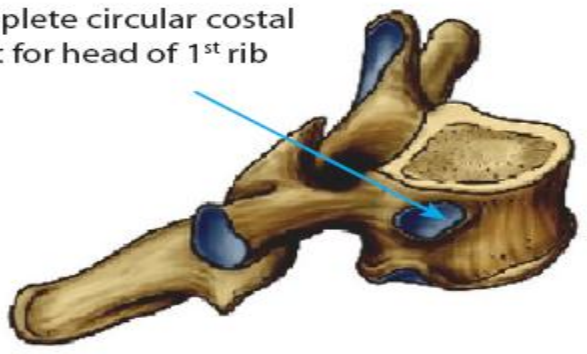


Figure (4): First thoracic vertebra.

Single complete costal facet for head of 10<sup>th</sup> rib

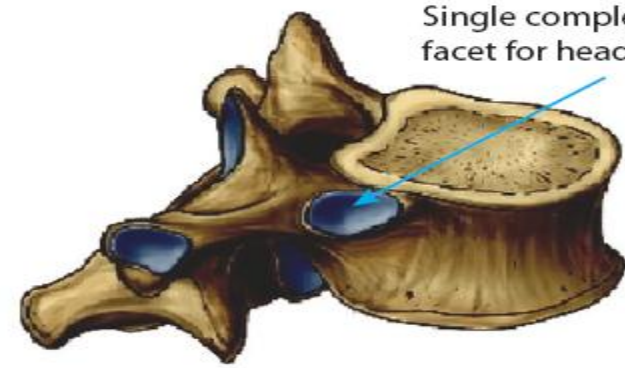
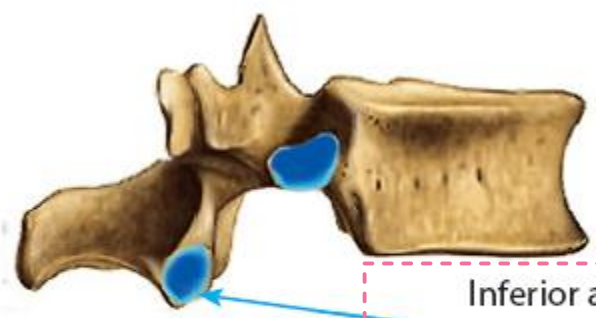
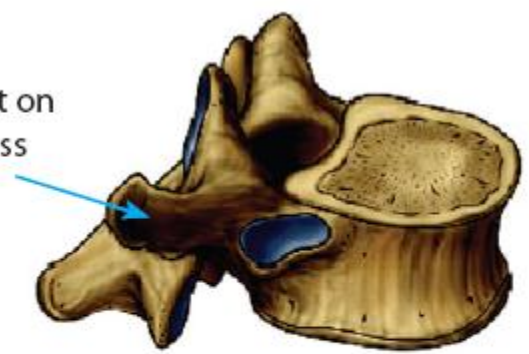

Figure (5): Tenth thoracic vertebra.

No articular facet on transverse process



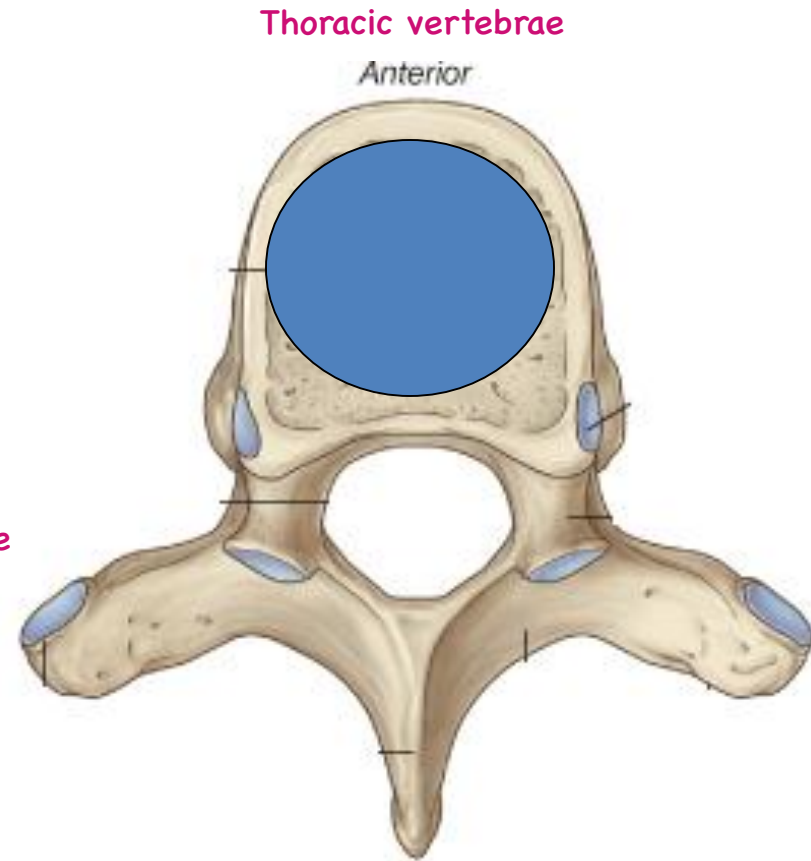
Inferior articular process is directed forward and laterally

12 11

Figure (6): Eleventh and twelfth thoracic vertebrae.

***The structure related to the marked area:***

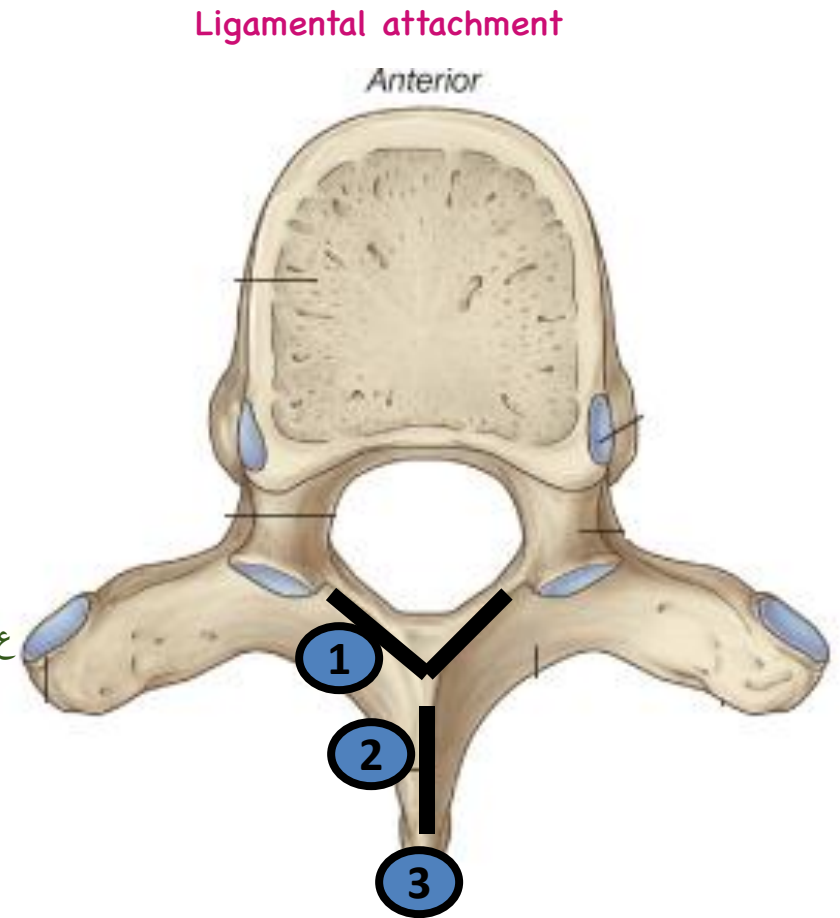
**Inter - vertebral disc.** Cartilage joint بين vertebrae  
(Secondary cartilaginous J).



Important

***The structure attached to the marked area.***

- 1) **Ligamentum flavum.** lamina جوا
- 2) **Inter - spinous ligament.** Spine جوا
- 3) **Supra-spinous ligament.** spine ع ال تبع Tip



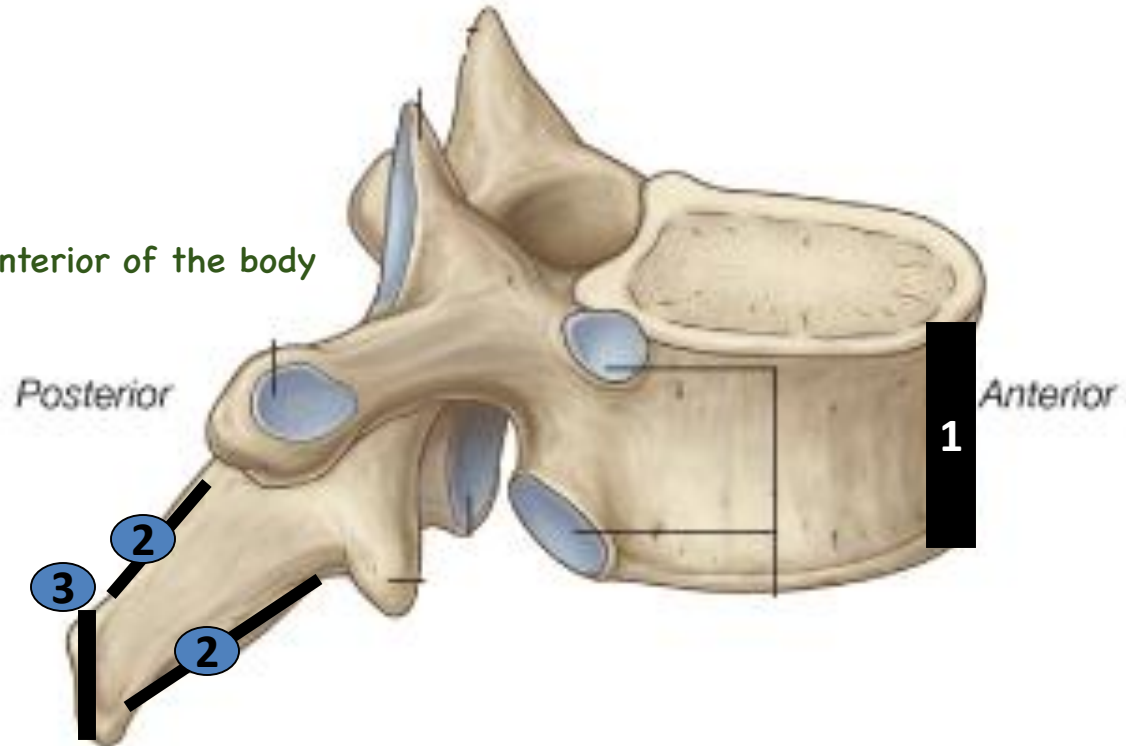


the structure attached to the marked area:

1) Anterior longitudinal ligament. *Anterior of the body*

2) Interspinous ligament.

3) Supra spinous ligament.



## Identification of the side of the lung

- The **apex** → Is directed **up**.
  - The **Hilum** → Is directed **Medially**.
  - The **anterior border** → Is **thin & sharp**.
- ☀
- The **right lung** has **3 lobes** → Superior, middle & inferior & **2 fissures** → Oblique & transverse (horizontal)
    - The left lung has only **2 lobes** → Superior & inferior & **1 fissure** → Oblique.
  - The **anterior border of the left lung** presents **cardiac notch & lingula**.

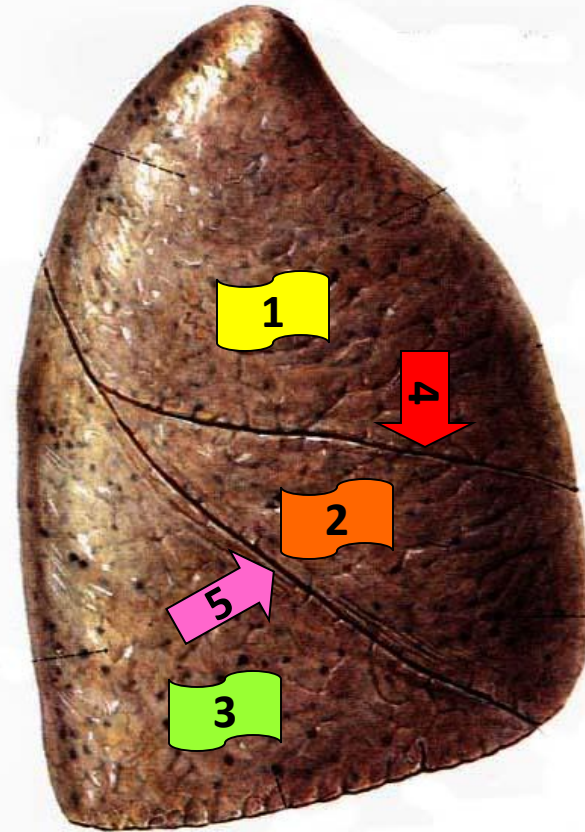
# Right lung

## Costal surface

1. Superior lobe.
2. Middle lobe.
3. Inferior lobe.
4. Transverse (horizontal) fissure
5. Oblique fissure.

\* **Costal surface is related to:**

1. Costal pleura.
2. Thoracic wall.

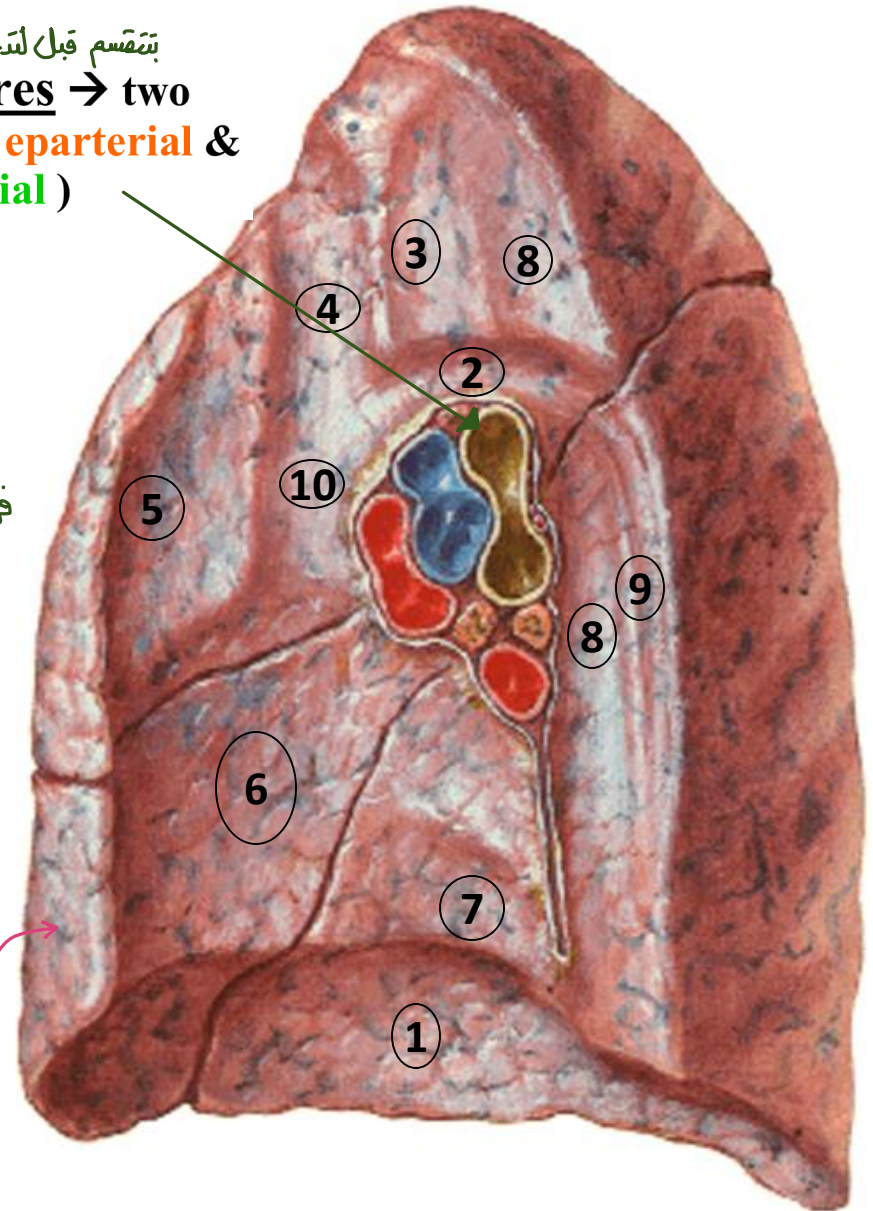


## Medial surface

بنتقسم قبل لتدخل Lung  
structures → two  
bronchi( **eparterial** &  
**hyparterial** )

1. **Base** → Related to **right cupola of diaphragm.**
2. **Arch of azygos vein.** Hilum فوف
3. **Trachea & rt. vagus nerve.**
- \* 4. **Rt. Brachiocephalic vein**
5. **Ascending aorta & thymus gland.**
6. **Rt. Atrium.**
7. **I.V.C.**
8. **Esophagus.**
9. **Azygos vein.**
10. **SVC**

Sharp anterior border

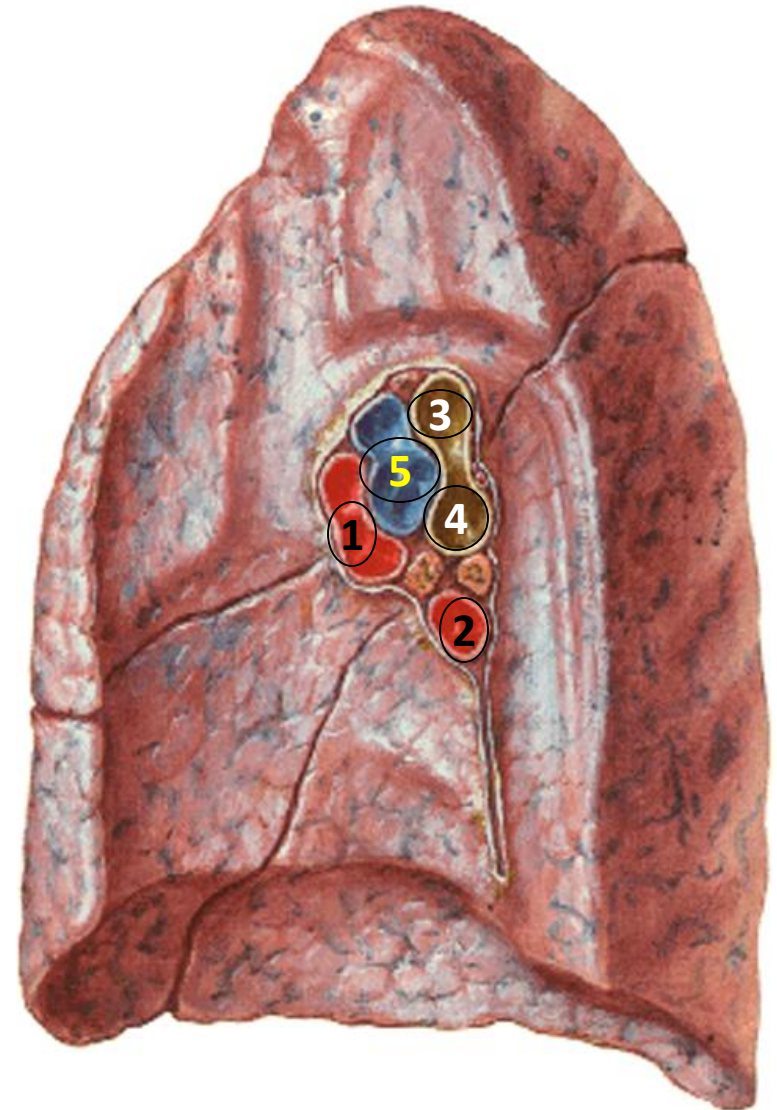




# Hilum

- 💡 The most anterior structure is : veins
- 💡 The most posterior structure is : bronchus

- 1. Superior pulmonary vein** → Most anterior structure.
- 2. Inferior pulmonary vein** → Most inferior structure.
- 3. Ep-Arterial bronchus** → Most posterior structure, have rigid wall & above the pulmonary artery .
- 4. Hyp-Arterial bronchus** → Most posterior structure, have rigid wall & below the pulmonary artery .
- 5. Right pulmonary artery** → Anterior to & in between the 2 bronchi.



# Left lung

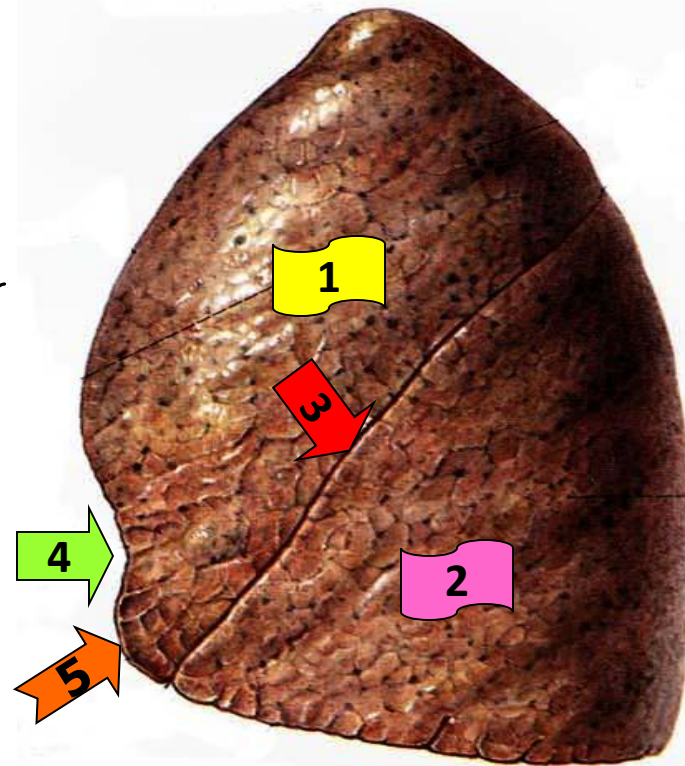
## Costal surface

1. Superior lobe.
2. Inferior lobe.
3. Oblique fissure.
4. Cardiac notch.
5. Lingula.

*in Anterior Border*

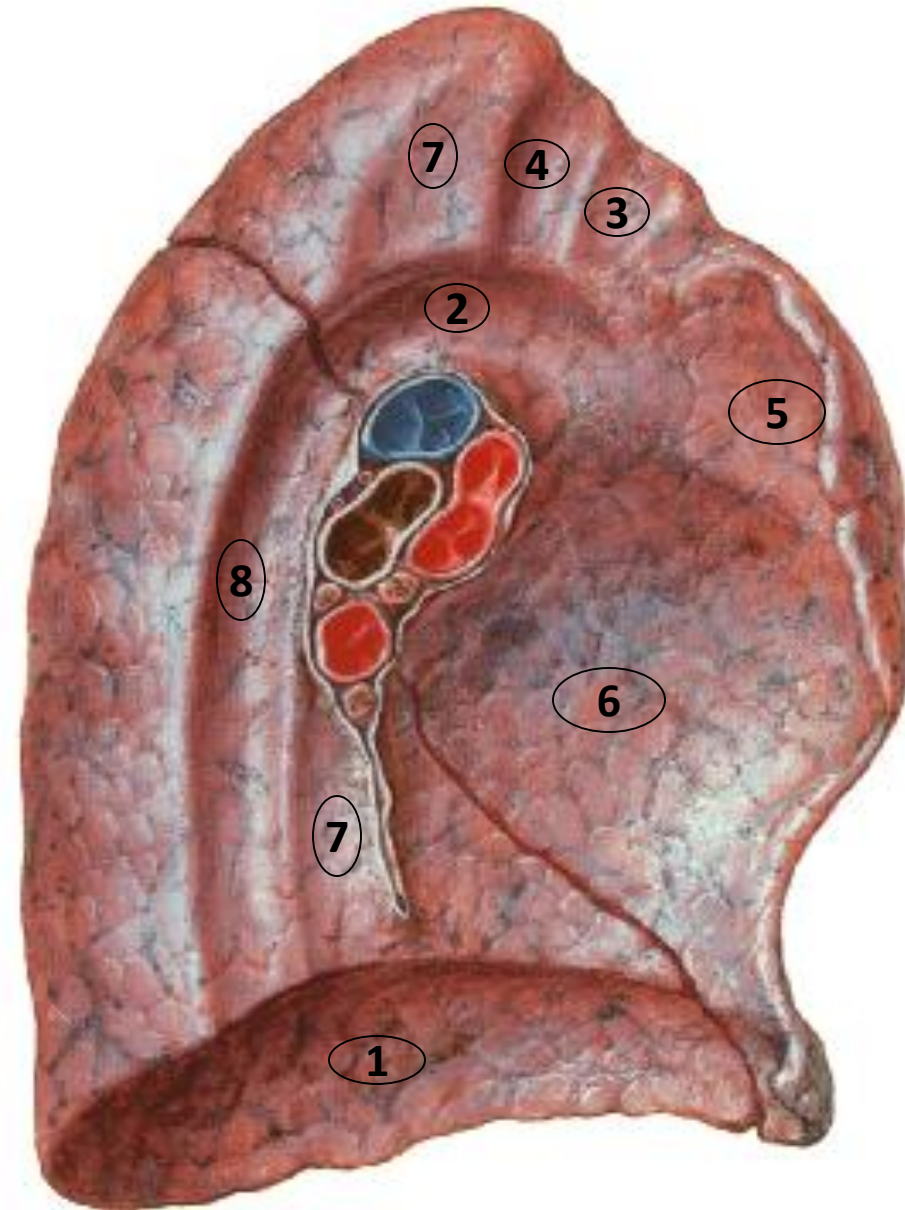
\* **Costal surface is related to:**

1. Costal pleura.
2. Thoracic wall.



## Medial surface

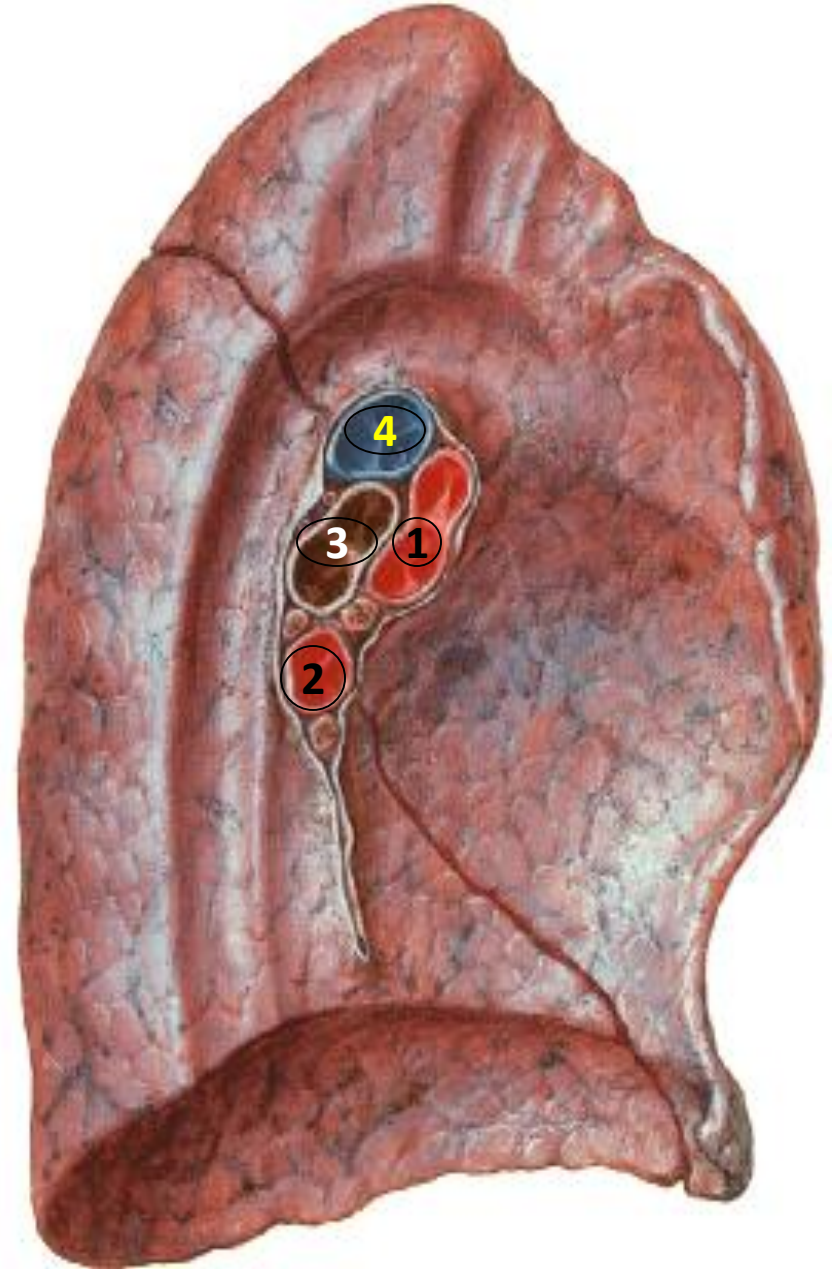
1. **Base** → Related to **Left cupola of diaphragm.**
2. **Arch of aorta.**
3. **Left common carotid artery.**
4. **Left subclavian artery.**
5. **Pulmonary trunk & Thymus.**
6. **Left ventricle.**
7. **Esophagus.**
8. **Descending thoracic aorta.**





## Hilum

- 1. Superior pulmonary vein** → Most anterior structure.
- 2. Inferior pulmonary vein** → Most inferior structure.  
*Not Divided (main)*
- 3. Left bronchus** → Most posterior structure & have rigid wall.
- 4. Left pulmonary artery** → اعلى واحد  
Anterosuperior to the left bronchus.



# ***Identify:***

1-Rt. Brachioceph

V.

2-Lt. Brachioceph

V.

3-Rt. Lung

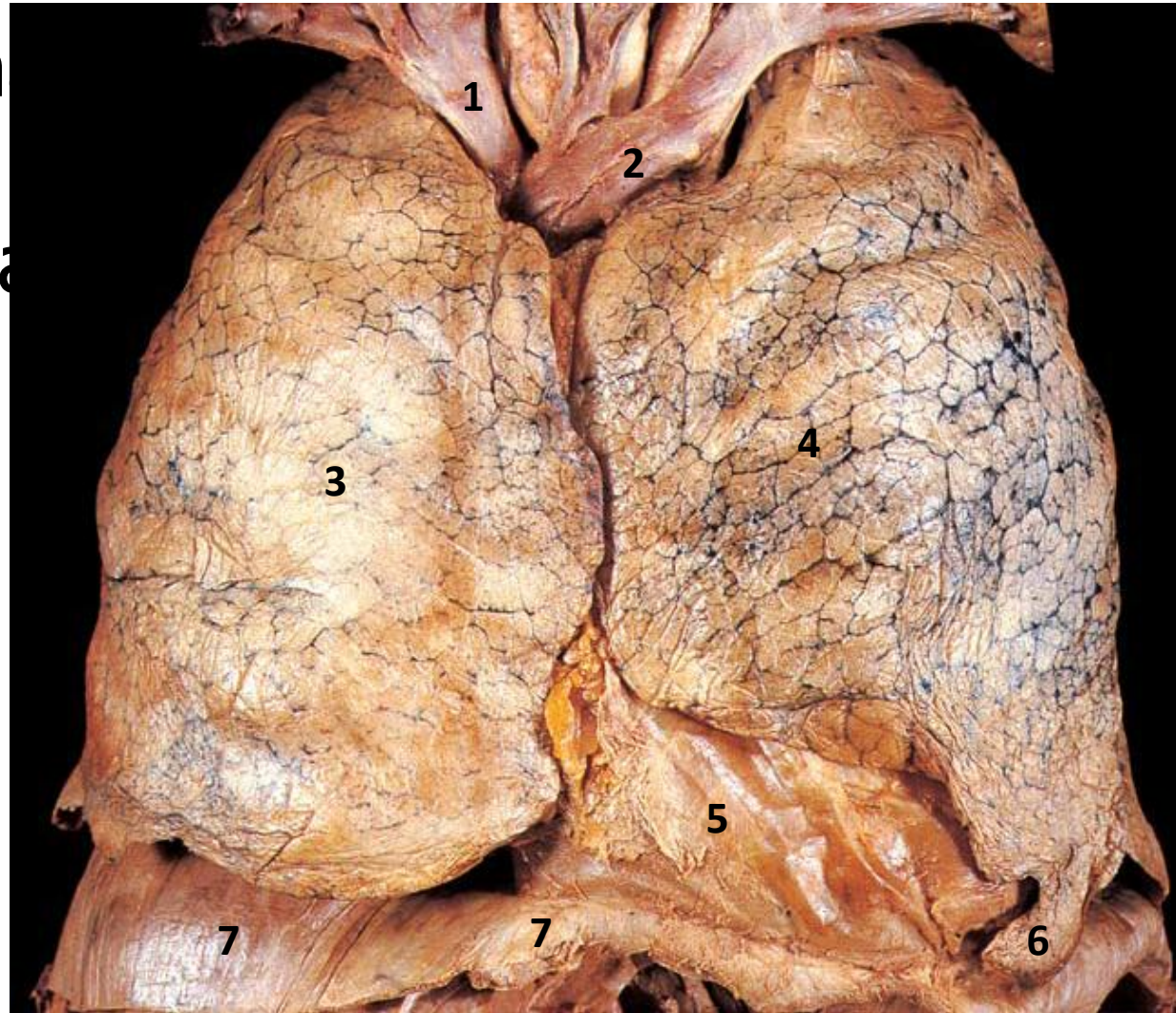
4-Lt. Lung

5-Fibrous  
Pericardium

بينهم

6-Lingula

7-Diaphragm





# ***Identify:***

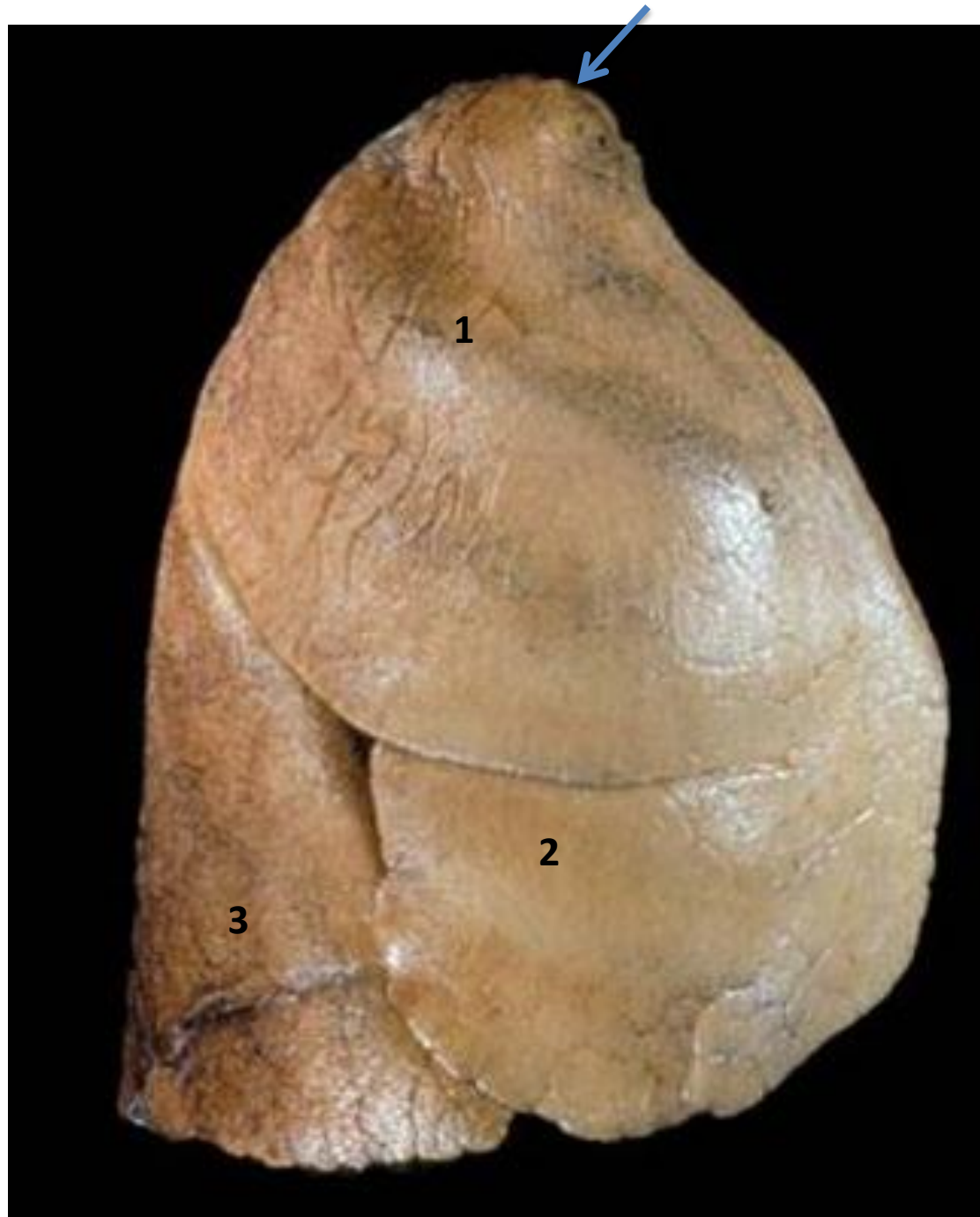**-Apex of the lung  
(blue Arrow)**

**1-Upper lobe**

**2-Middle lobe**

**3-Lower lobe**

*Right lung*



## *Identify:*

- **Apex of the right lung (red Arrow)**

**1-Upper lobe**

**2-Middle lobe**

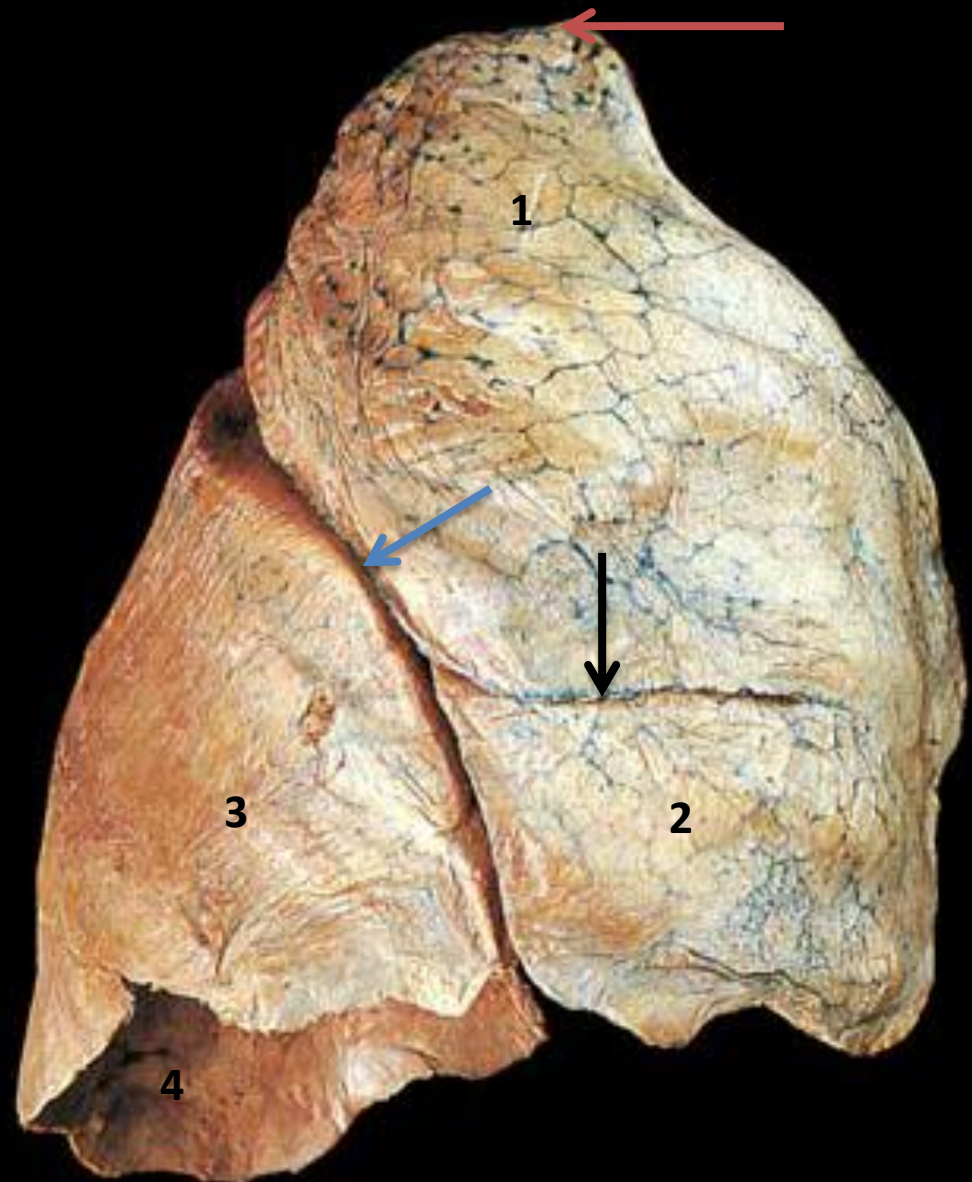
**3-Lower lobe**

- **Horizontal fissure (black Arrow)**

- **Oblique fissure (blue Arrow)**

**4-Base of the lung (Diaphragmatic surface).**

Right lung, costal surface



# ***Identify:***

- **Apex** of the left lung  
(**red Arrow**)

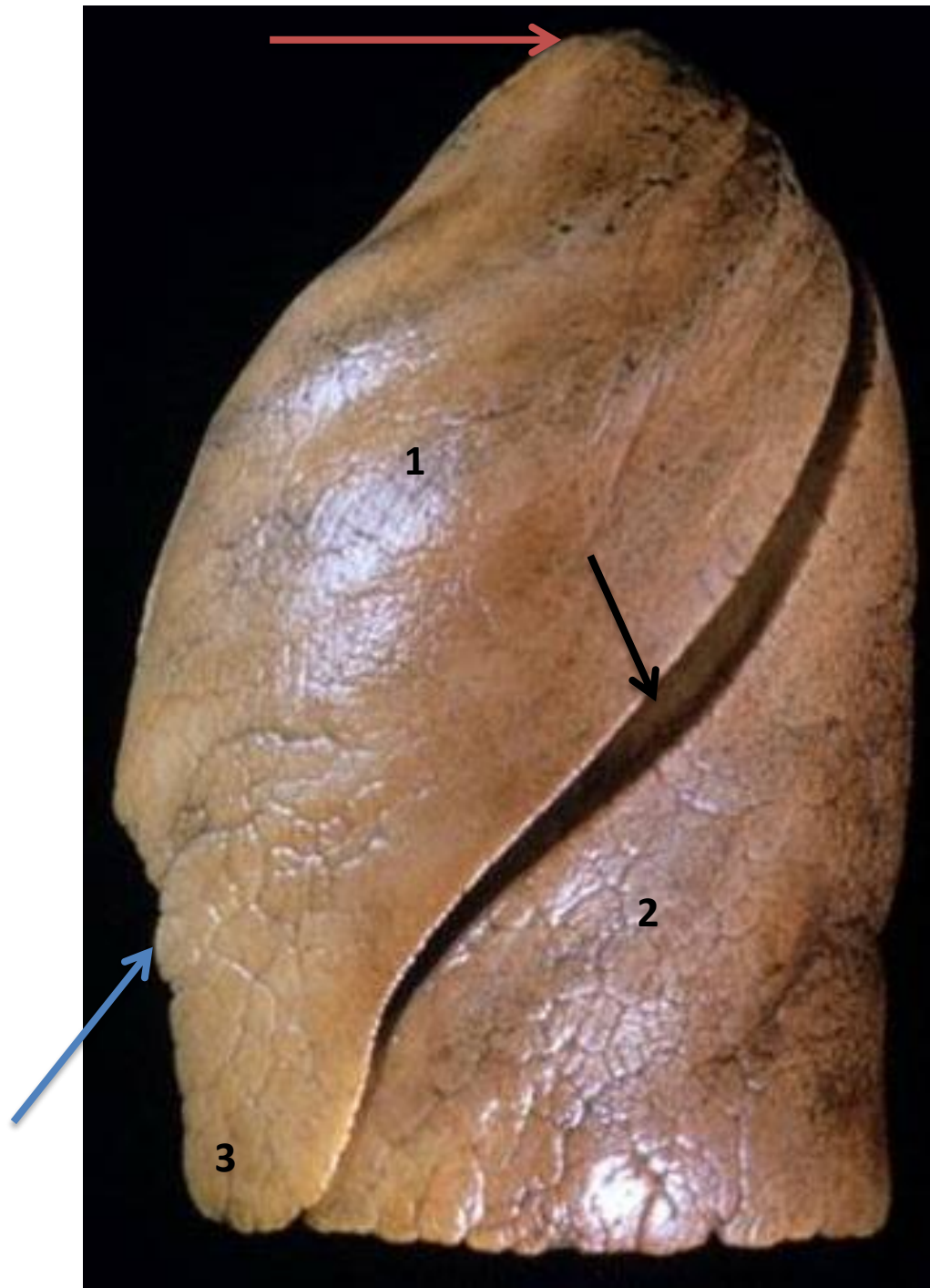**1-Upper lobe**

**2-Lower lobe**

- **Oblique fissure**  
(**black arrow**)

- **Cardiac notch**(**blue arrow**)

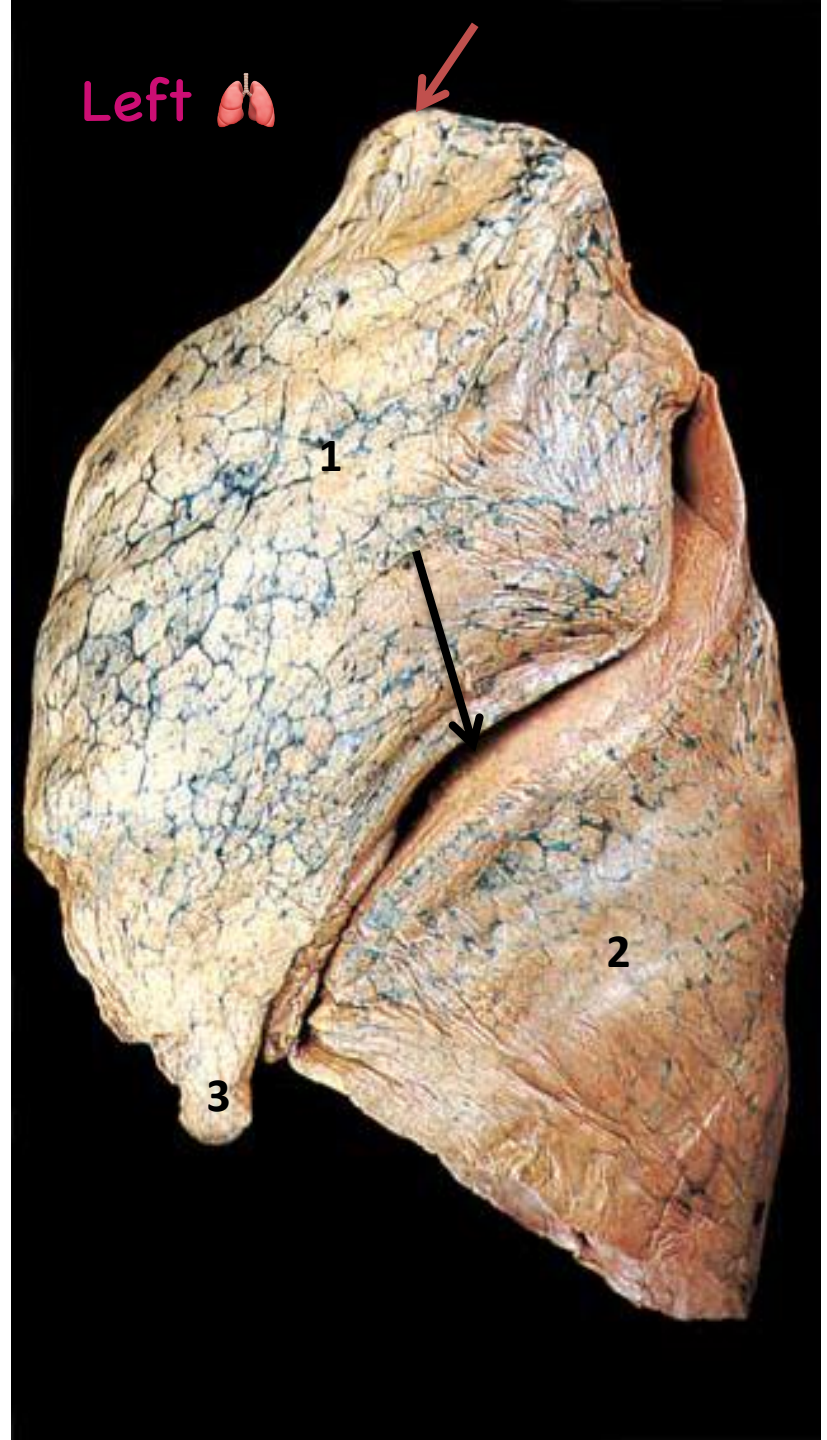
**3-Lingula**





## ***Identify:***

- **Apex of the left lung (red arrow)**
- 1-Upper lobe**
- 2-Lower lobe**
- **Oblique fissure (black arrow)**
- 3-Lingula**

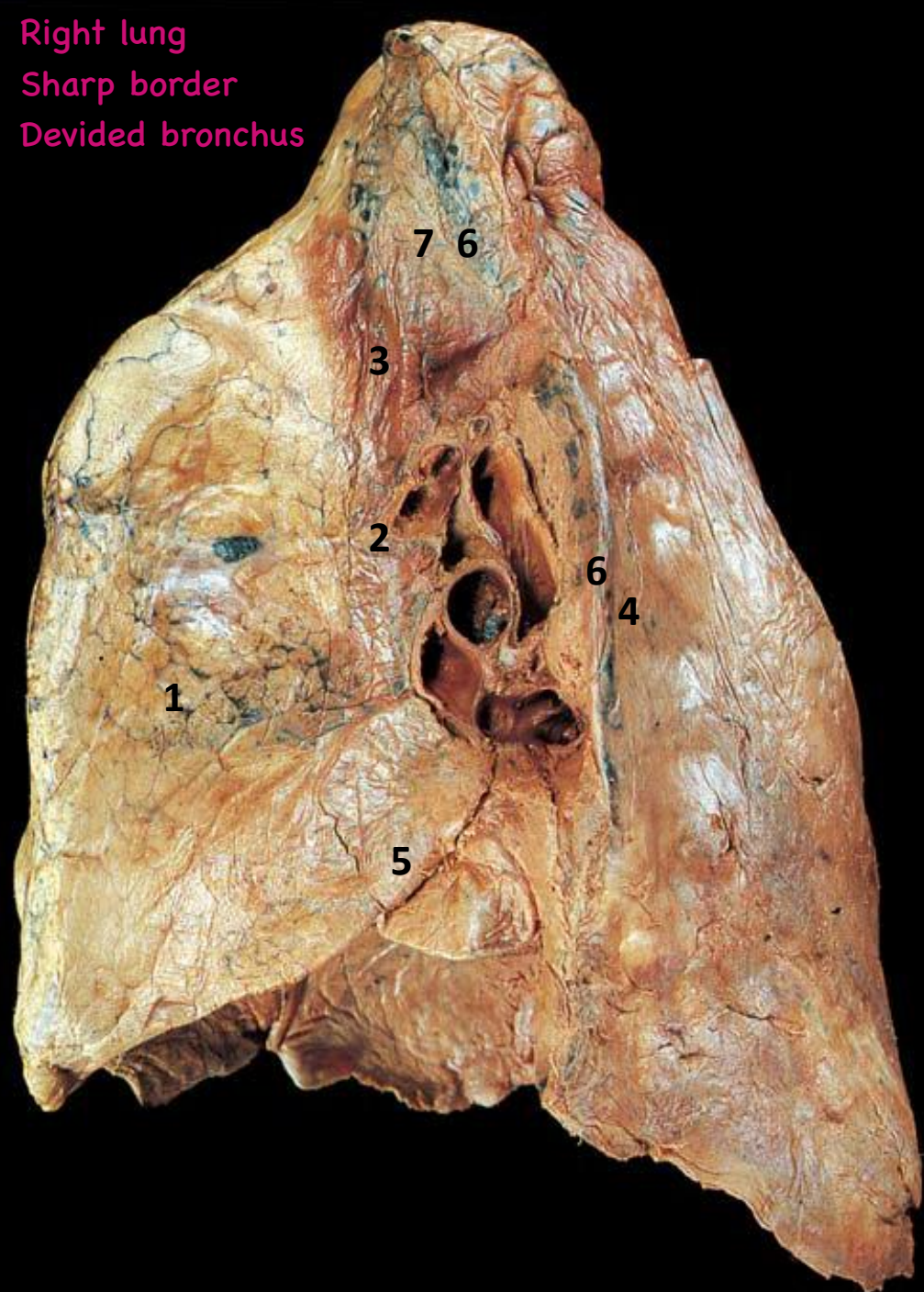


# ***Identify:***

بدي اميز right من left ومافي loops  
بشوف hilum + anterior border

Right lung  
Sharp border  
Devided bronchus

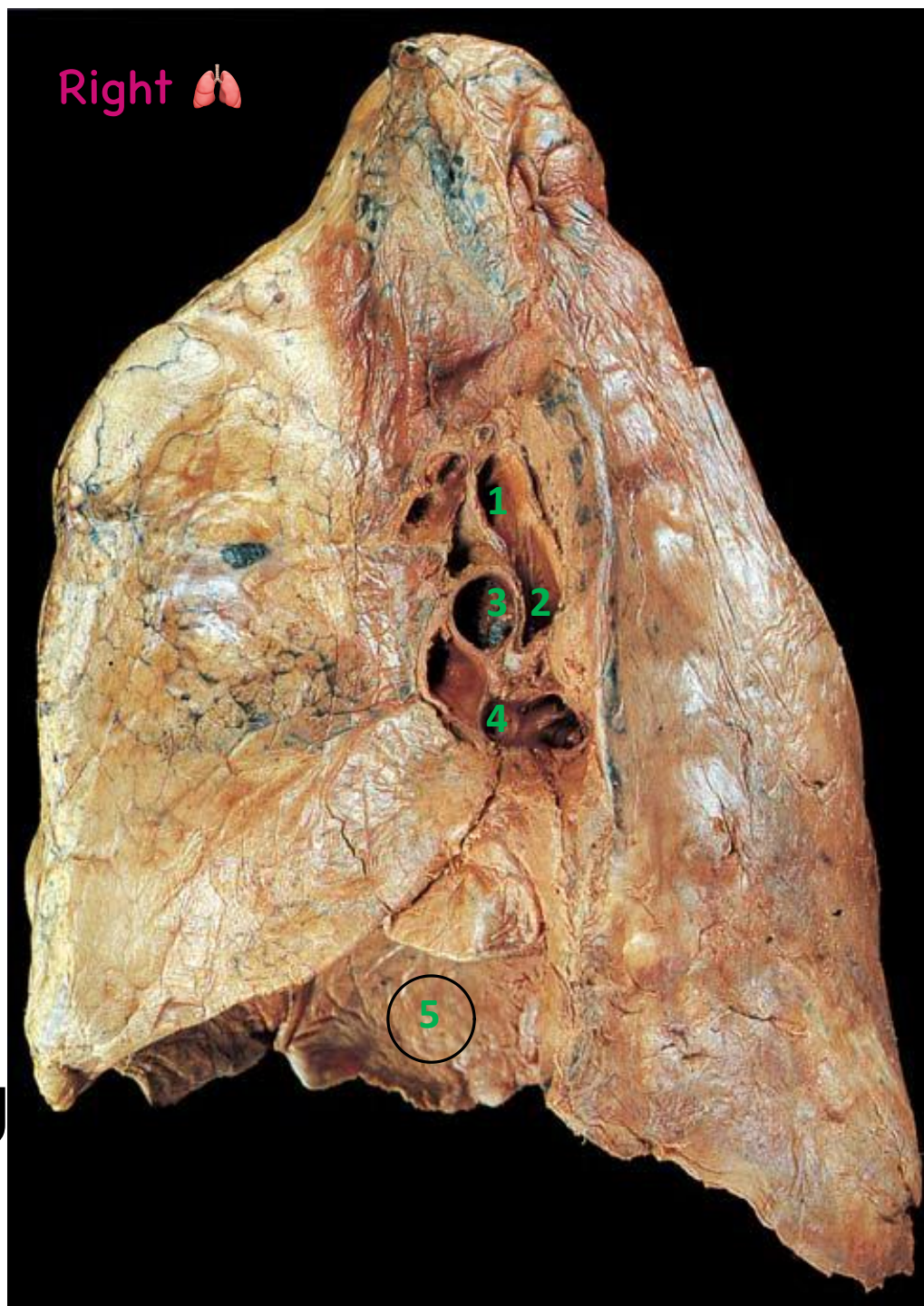
- 1-Rt. atrium impression**
- 2-SVC impression**
- 3-Rt. Brachiocephalic vein impression**
- 4-Azygos vein impression**
- 5-IVC impression**
- 6-Esophageal impression**
- 7-Tracheal impression**





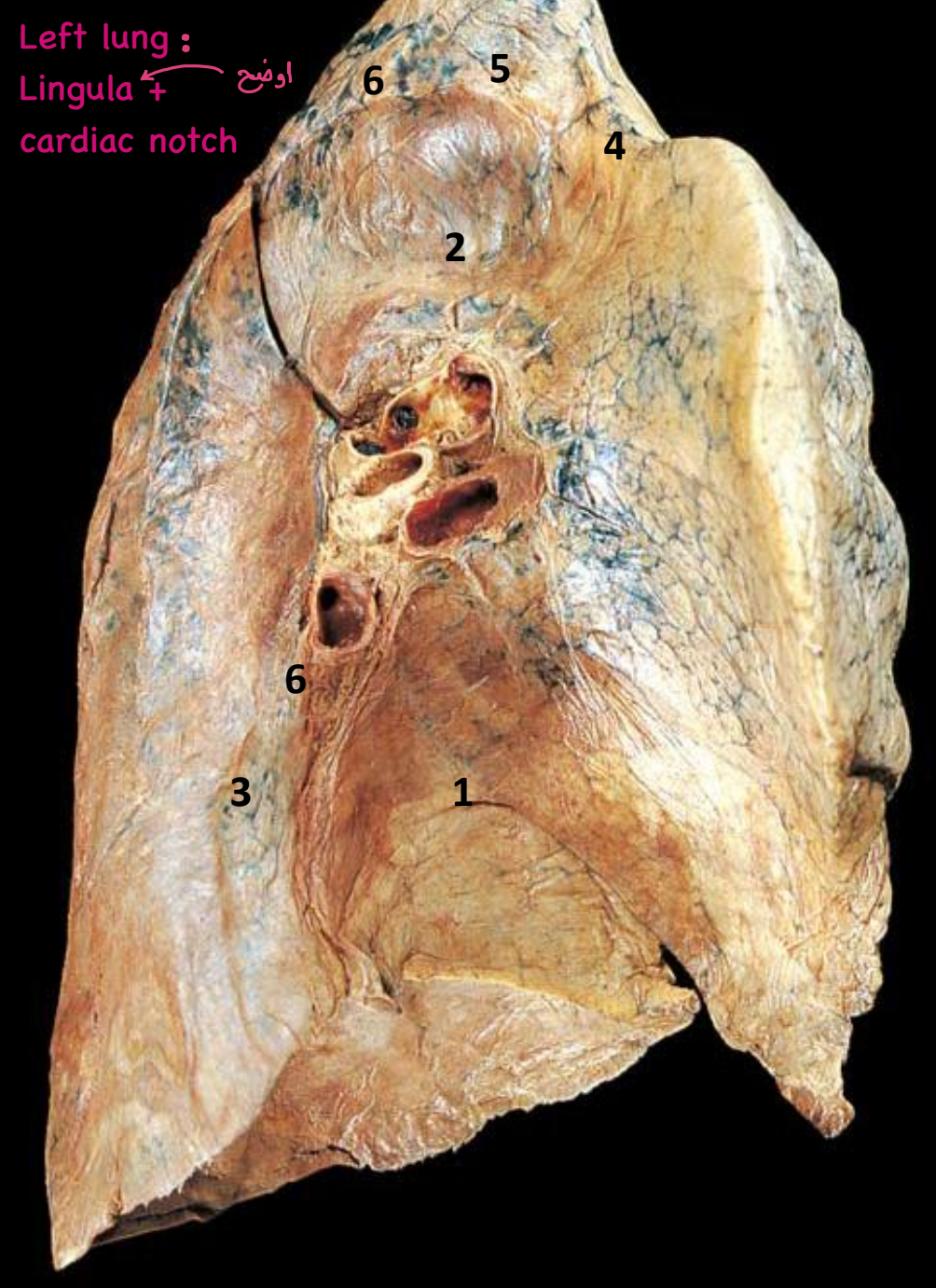
## ***Identify:***

- 1-Eparterial bronchus**
- 2-Hiparterial bronchus**
- 3-Right Pulmonary artery**
- 4-right Pulmonary veins**
- 5-Diaphragmatic surface of right lung**



# ***Identify:***

- 1-Left ventricle impression**
- 2-Aortic arch impression**
- 3-Thoracic aorta impression**
- 4-Lt. CCA impression**
- 5-Lt. Subclavian artery impression**
- 6-Esophageal impression**





# ***Identify:***

Most posterior structure

**1-Lt. Main bronchus**

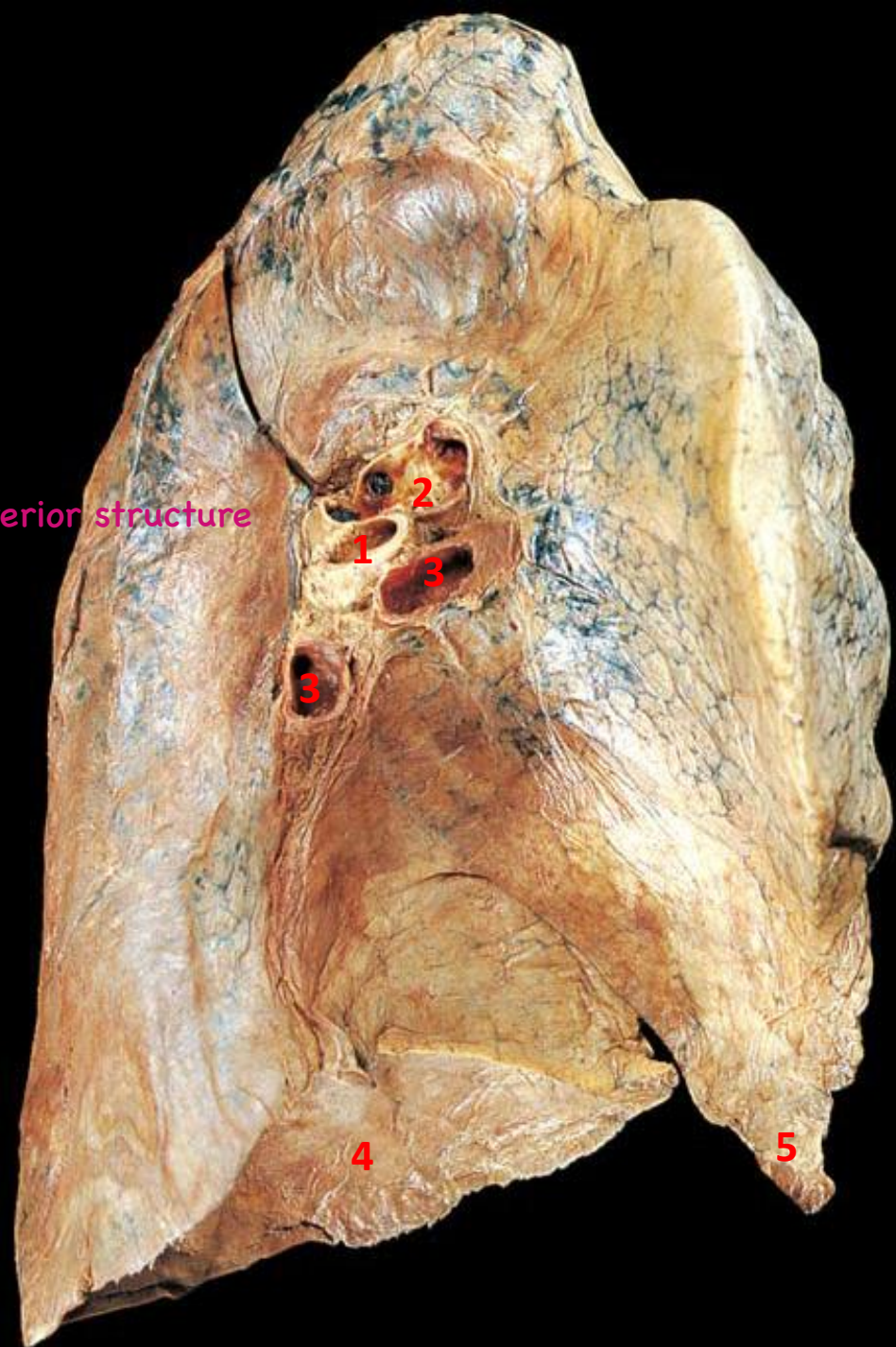
**2-Lt Pulmonary**

**artery** *Most superior structure*

**3-Lt Pulmonary veins** *Most anterior structure*

**4-Diaphragmatic surface of left lung**

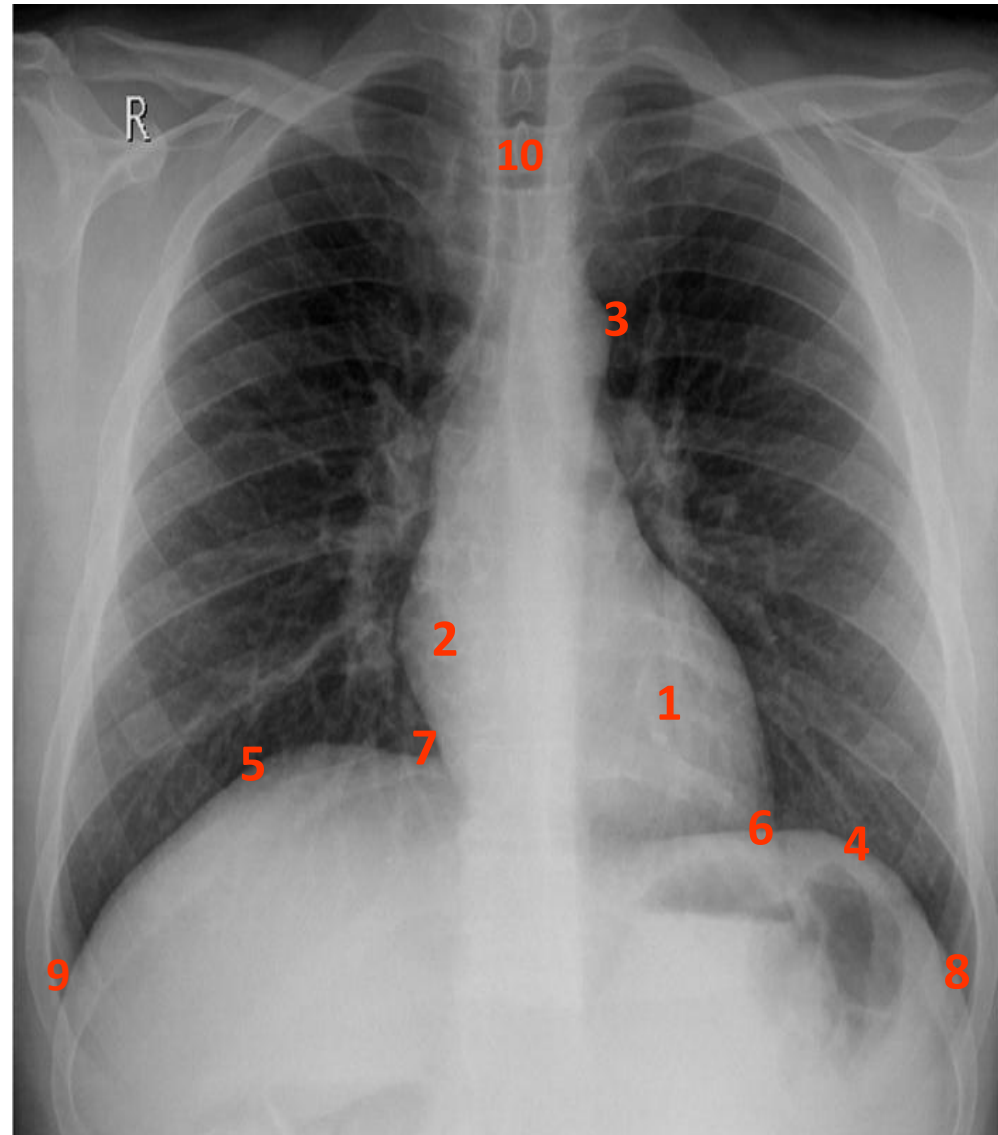
**5-Lingula**



## Normal x-ray

### Soft tissues:

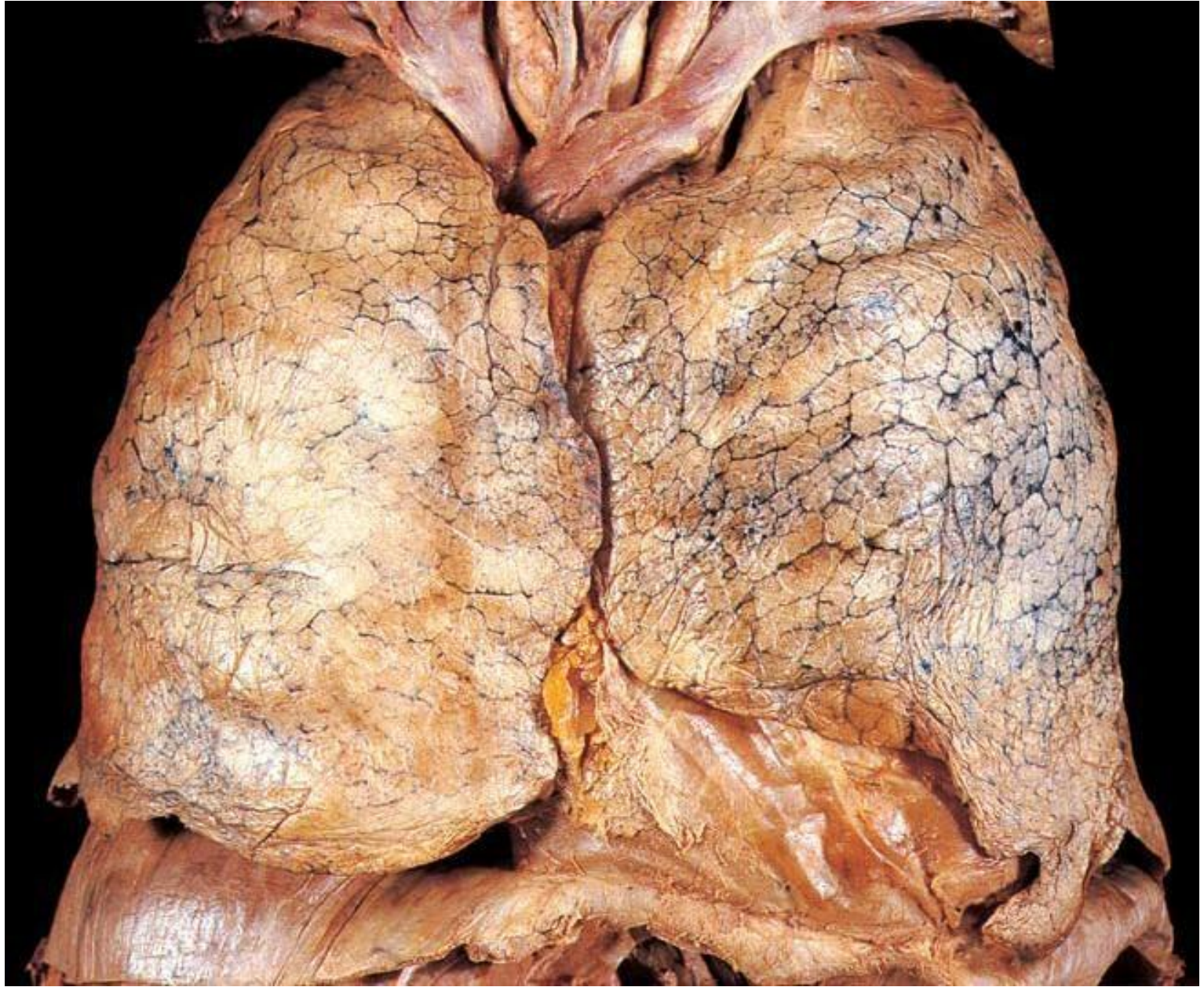
1. **Left ventricle** (left border of the heart).
2. **Right atrium** (right border of the heart).
3. **Aortic knuckle** (arch of aorta). *in x-ray*
4. **Left cupola of diaphragm.**
5. **Right cupola of diaphragm.**
6. **Left cardio-phrenic angle.**
7. **Right cardio-phrenic angle.**
8. **Left costo-phrenic angle.**
9. **Right costo-phrenic angle.**
10. **Tracheal shadow.**



Obliteration of the **cardio** diaphragmatic angle: **pericardial effusion**

Obliteration of the **costo** diaphragmatic angle: **plural effusion**

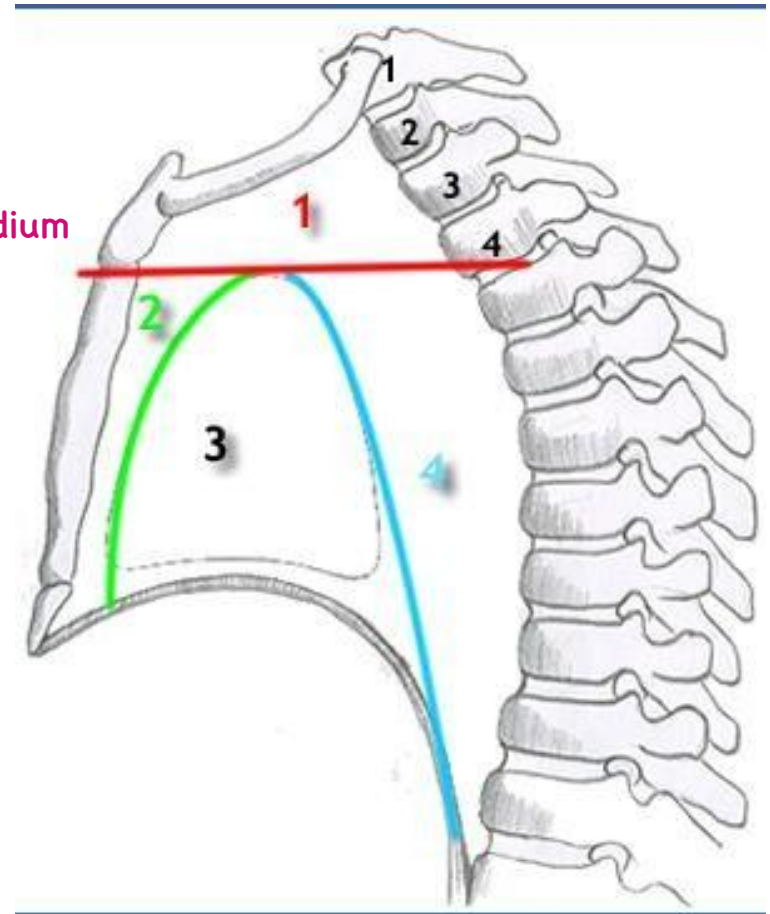






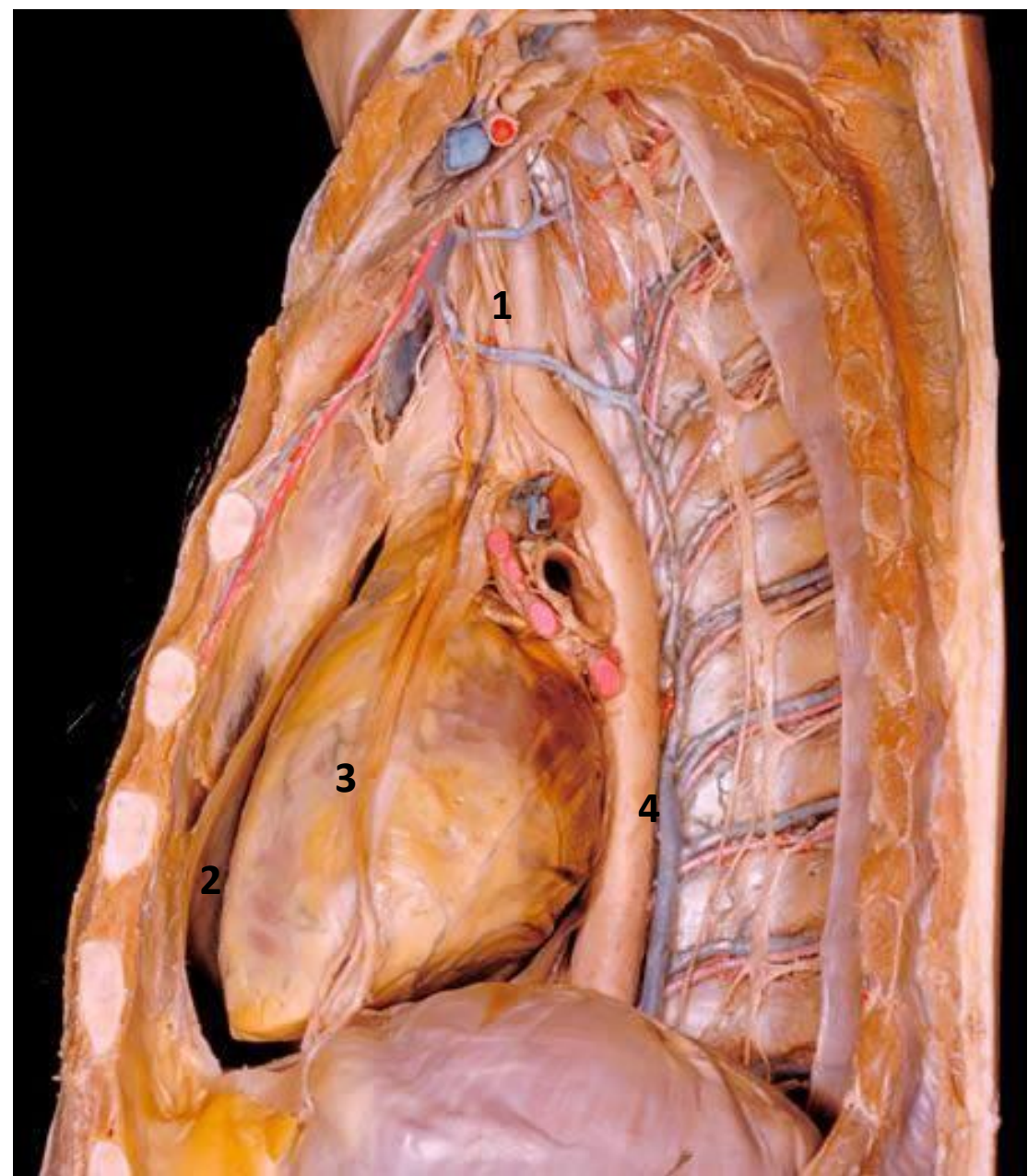
## *Identify:*

- **(1) Superior Mediastinum**
- **(2,3,4) Inferior Mediastinum** Heart, pericardium
- **(2) Anterior Mediastinum**
- **(3) Middle Mediastinum**
- **(4) Posterior Mediastinum**



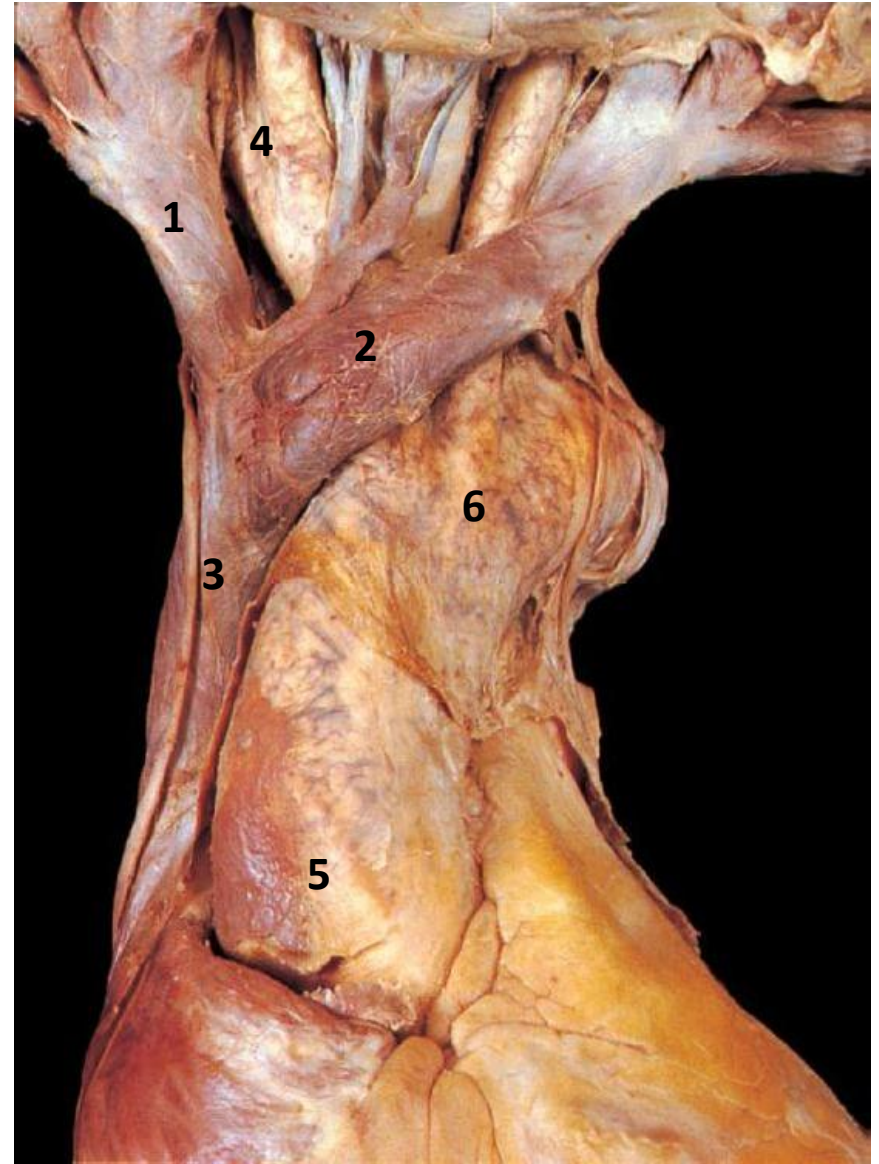
***Identify:***

- 1-Superior Mediastinum**
- 2-Anterior Mediastinum**
- 3-Middle Mediastinum**
- 4-Posterior Mediastinum**



***Identify:***

- 1- Rt. Brachiocephalic vein**
- 2- Lt. Brachiocephalic vein**
- 3- SVC**
- 4- Brachiocephalic artery** → Branch from 6
- 5- Ascending Aorta**
- 6- Arch of Aorta**



## ***Identify:***

**1-Arch of Aorta**

**2-Trachea**

**3-Left common carotid artery**

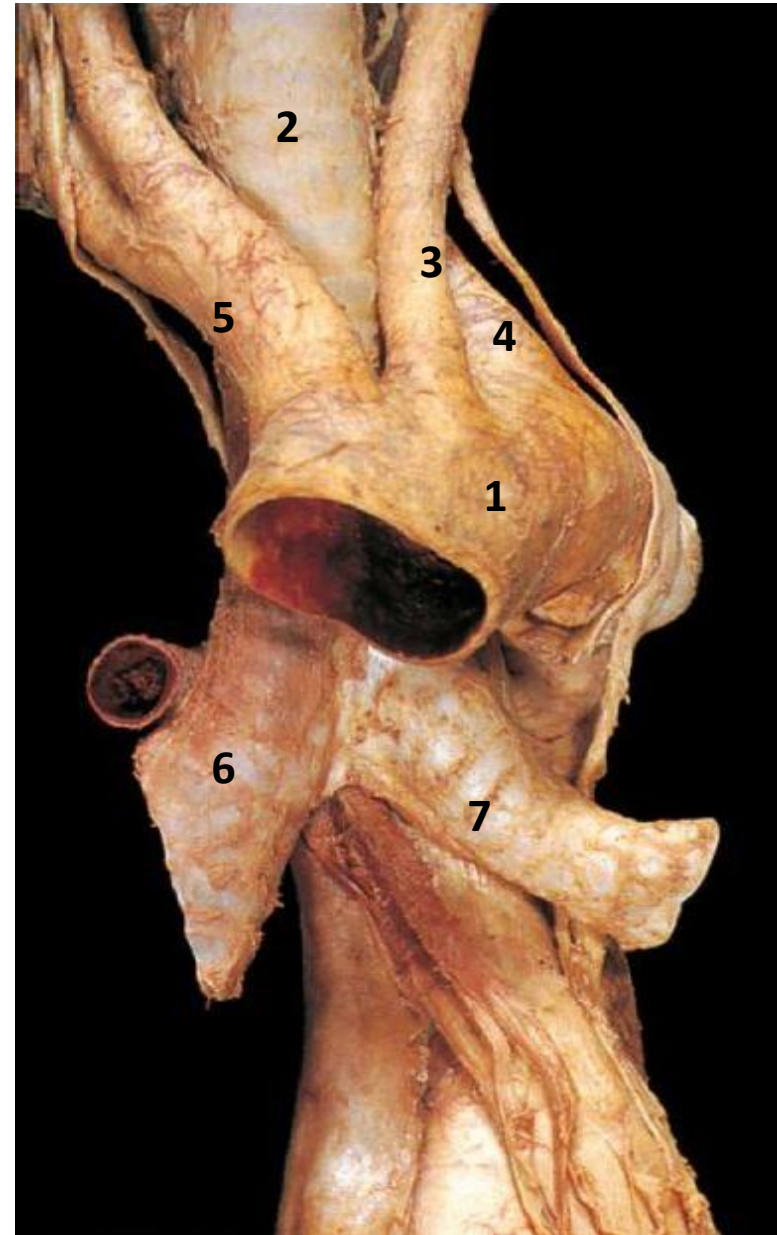
**4-Left subclavian artery**

**5- brachiocephalic artery**

**6-Right main Bronchus**

**7- Left. main bronchus**

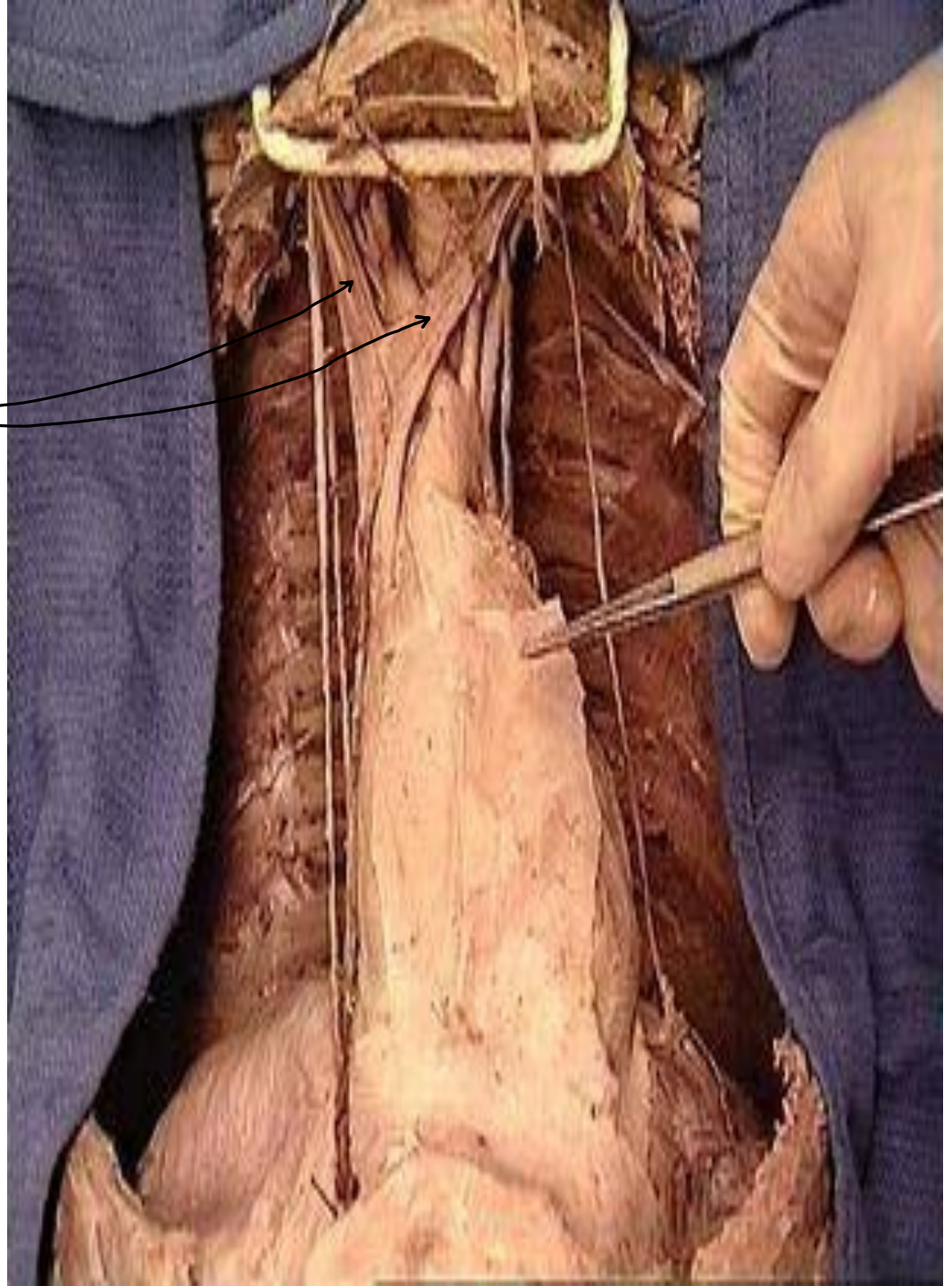
رج تقسم  
الى





***Identify:***

- **Rt. & Lt. Brachiocephalic V.** → عابدين
- **SVC**





***Identify:***

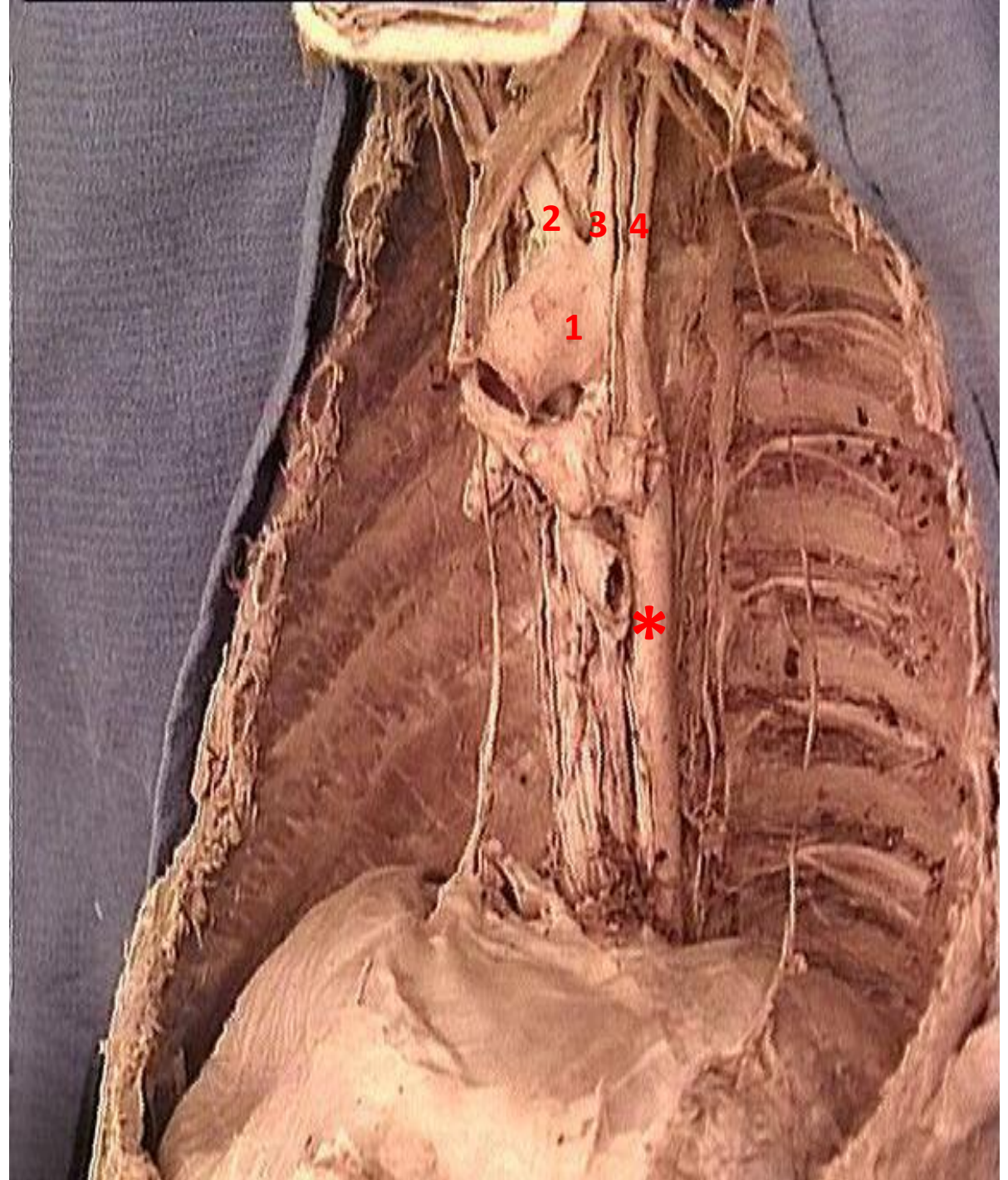
**1-Arch of aorta**

**2-Brachiocephalic a**

**3-Lt CCA**

**4-Lt subclavian A**

**\*Descending Aorta**



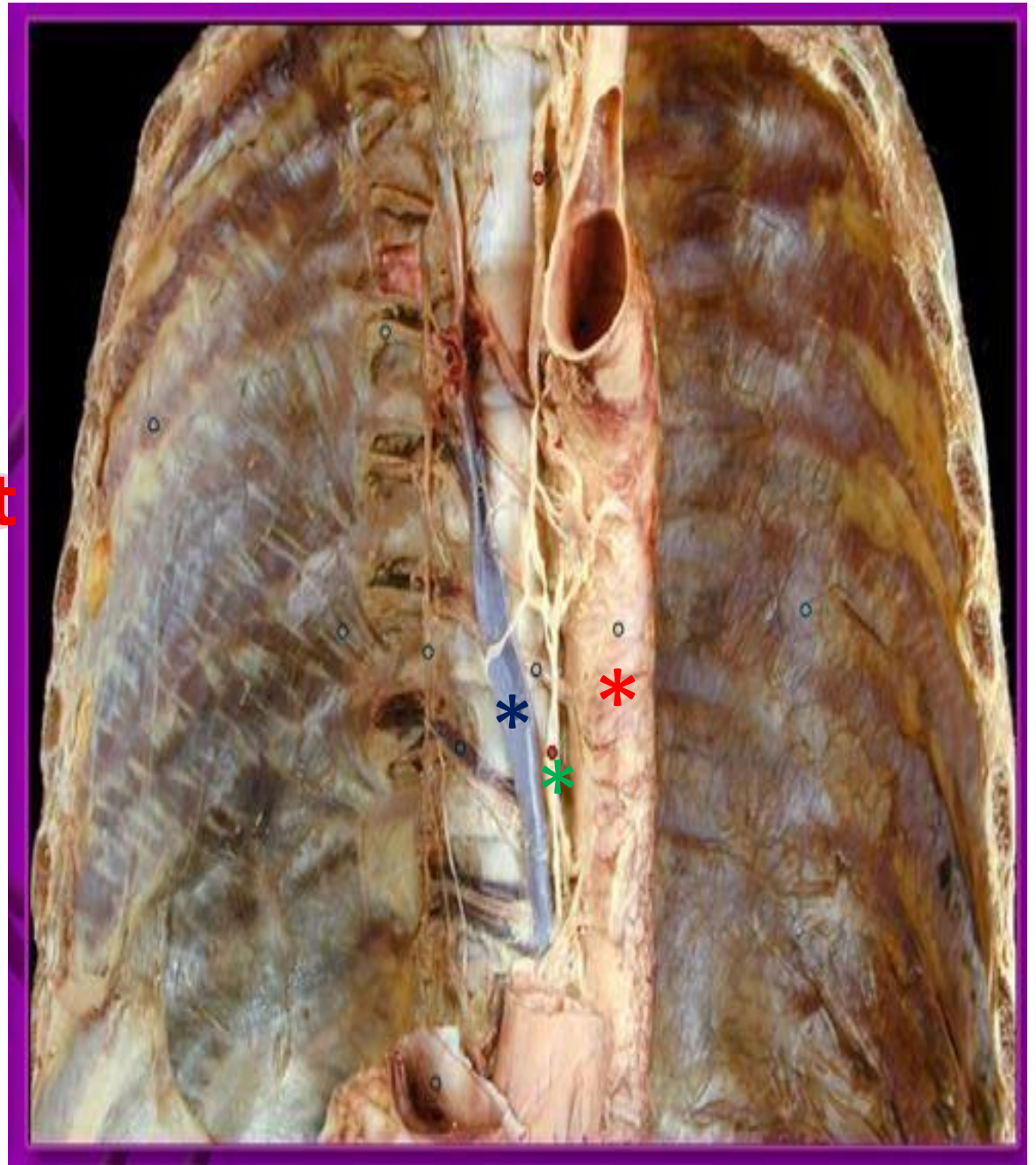
***Identify:***

**\*Thoracic**

**Aorta**

**\*Azygos vein**

**\*Thoracic duct**

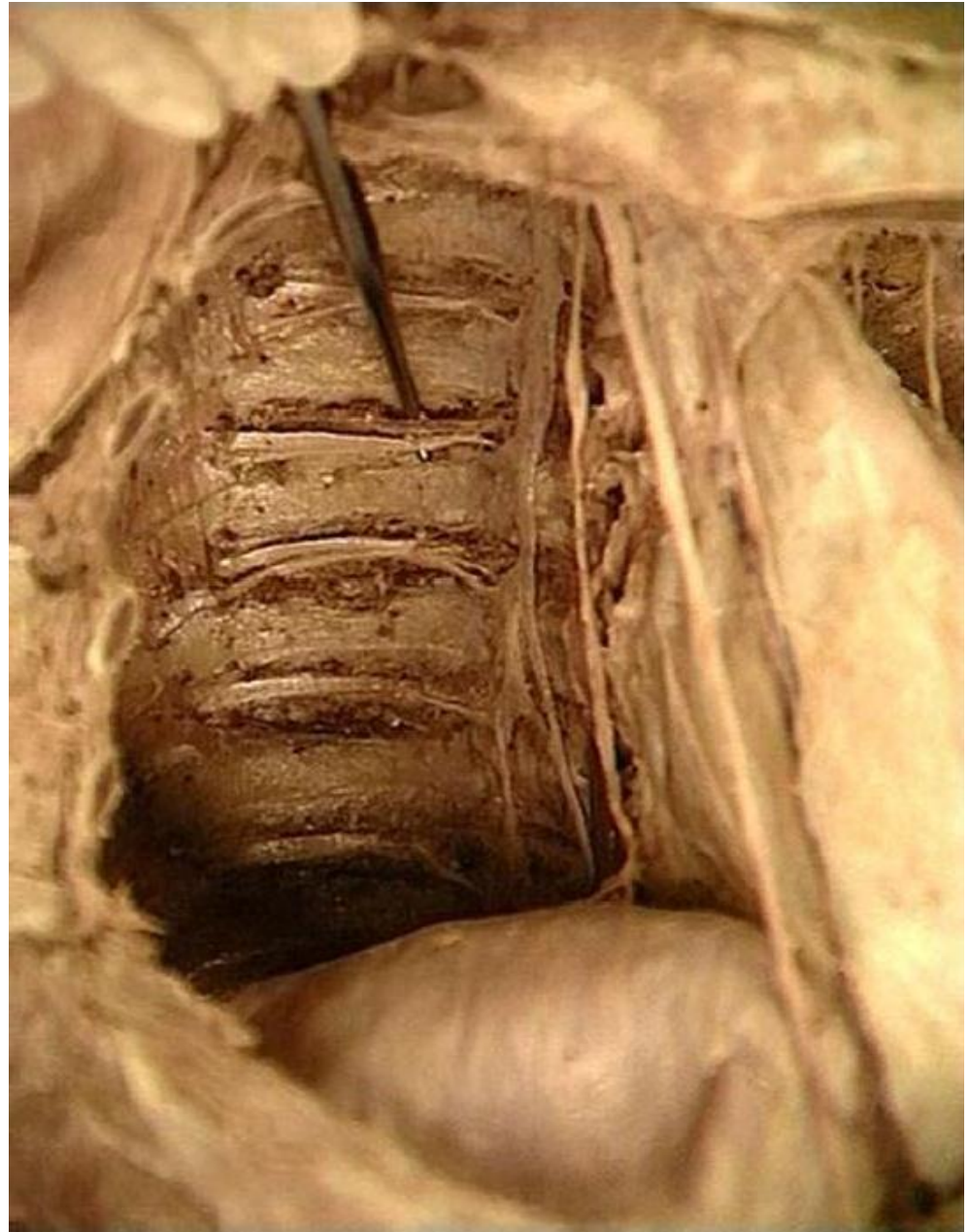



Costal groove

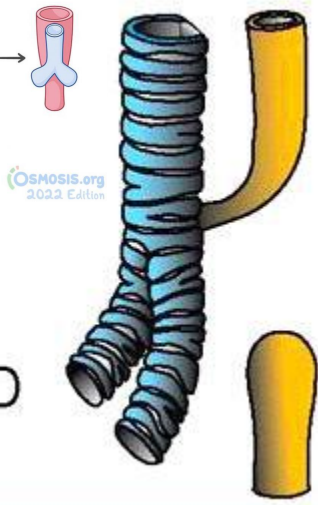
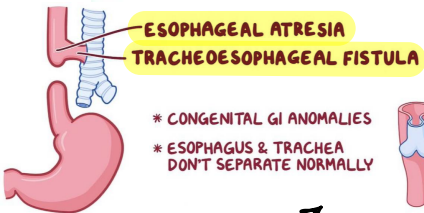
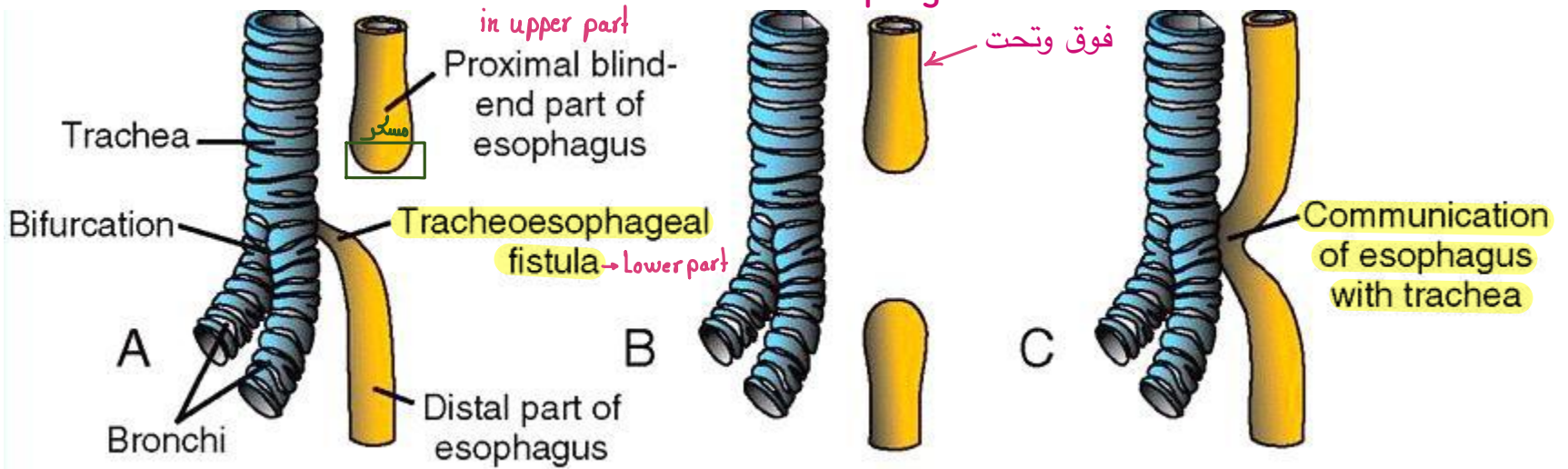
***Identify:***

- Posterior  
intercostal VAN

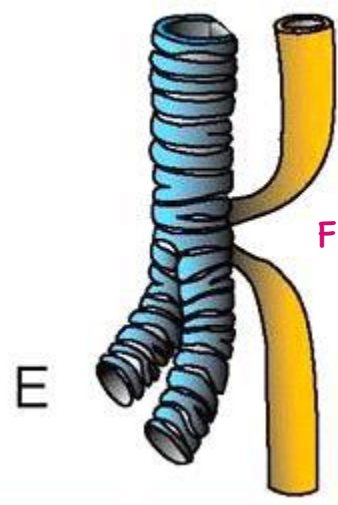


# Tracheo- esophageal fistula

esophageal atresia



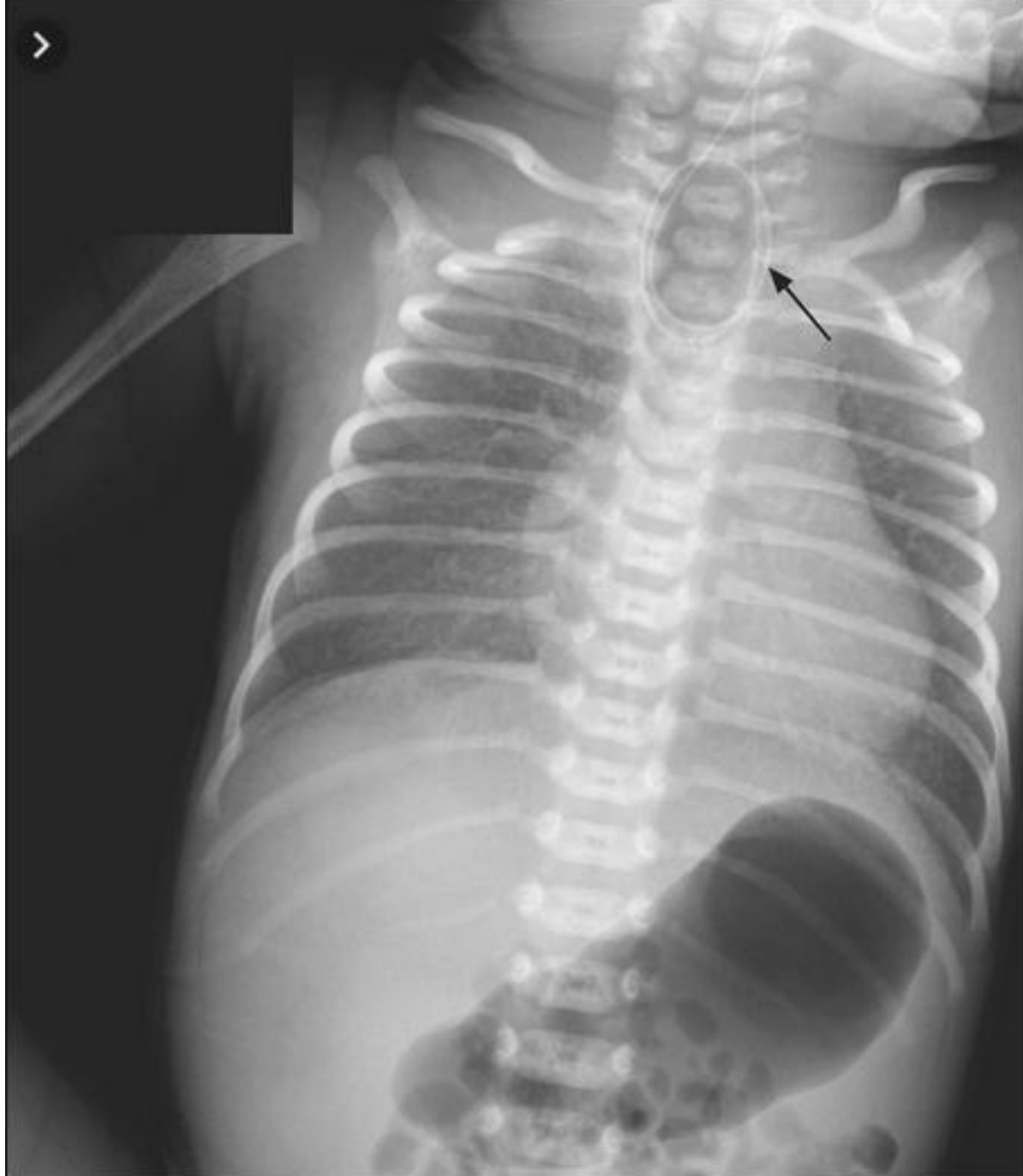
عكس A



Fistula in lower & upper



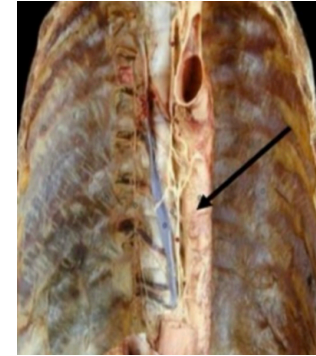
**Radiological picture  
of Tracheo-  
esophageal fistula  
“Coiled Ryle tube”**



## شوفوا هالاسئلة:

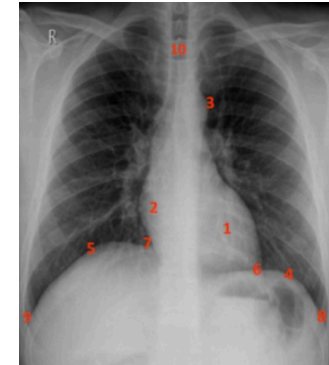
1- The structure marked by the black arrow is which one of the followings?

- A) Azygous vein
- B) Thoracic duct
- C) Inferior vena cava
- D) Descending aorta
- E) Trachea



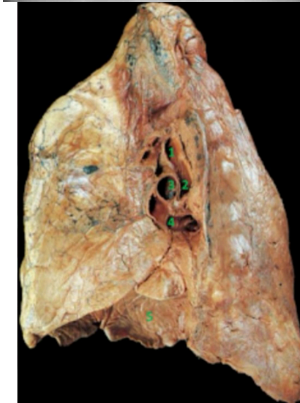
2- 8 in the following figure represents:

- A) Left cardio-phrenic angle
- B) Left Costo-phrenic angle
- C) aortic knuckle ( arch of aorta)
- D) Right cardio-phrenic angle
- E) Right Costo-phrenic angle



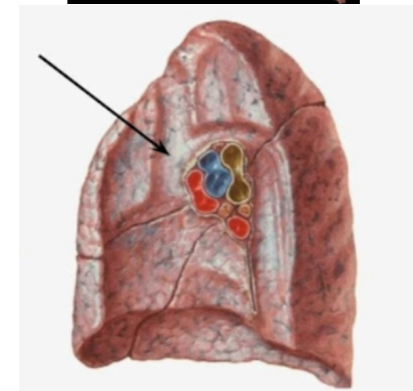
3- 1 in the figure below indicates:

- A) hiparterial bronchus
- B) eparterial bronchus
- C) right pulmonary artery
- D) upper right pulmonary vein
- E) lower right pulmonary vein



4- the groove that is pointed at by the arrow below represents:

- A) trachea
- B) oesophagus
- C) superior vena cava
- D) arch of azygous
- E) right brachiocephalic vine





تفضلوا الأجوبة: 📌❤️

1- D

2- B

3- B

4- C

بالتوفيق ... 🎀❤️

*dane*