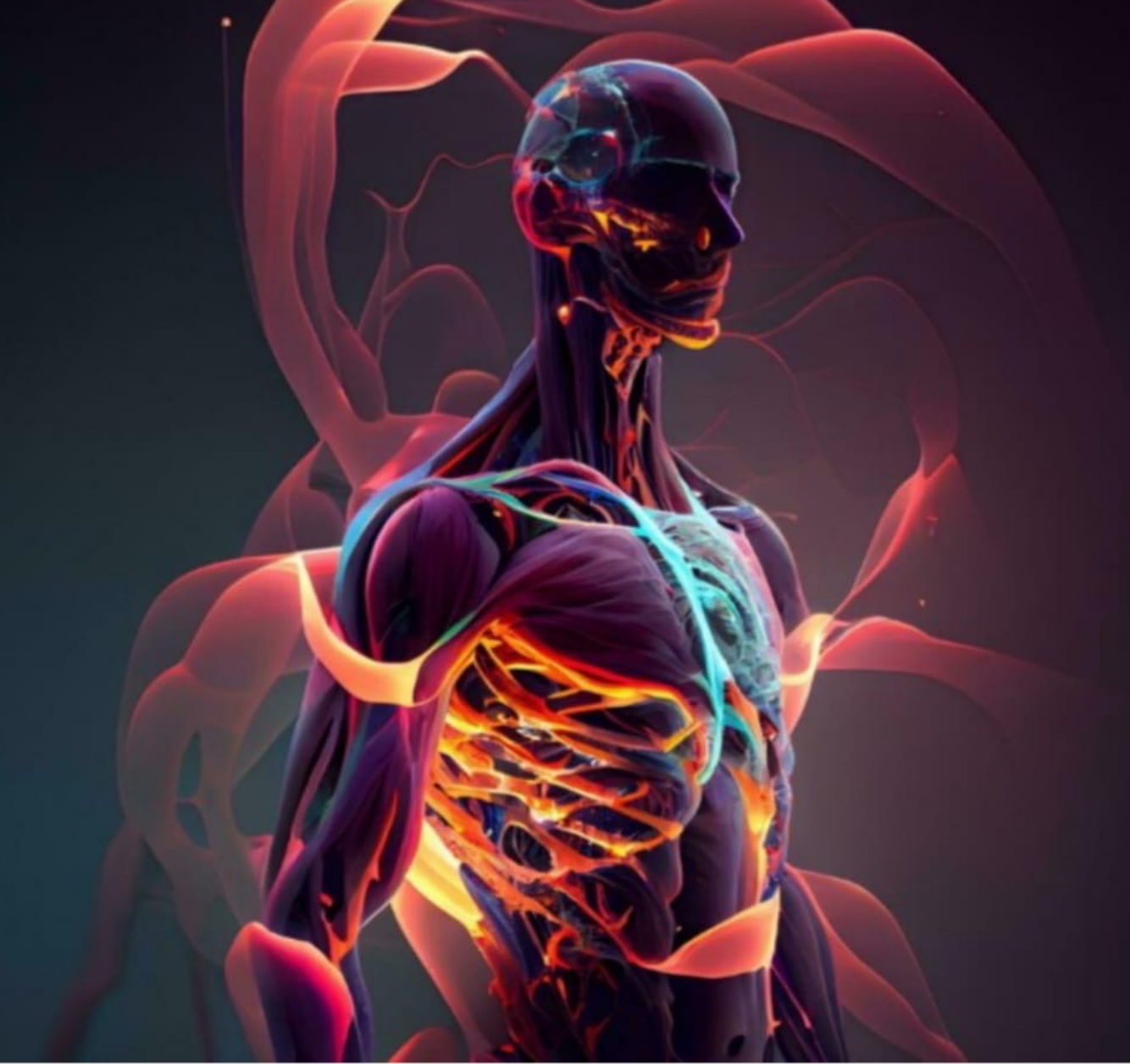



Lecture: Lab 1


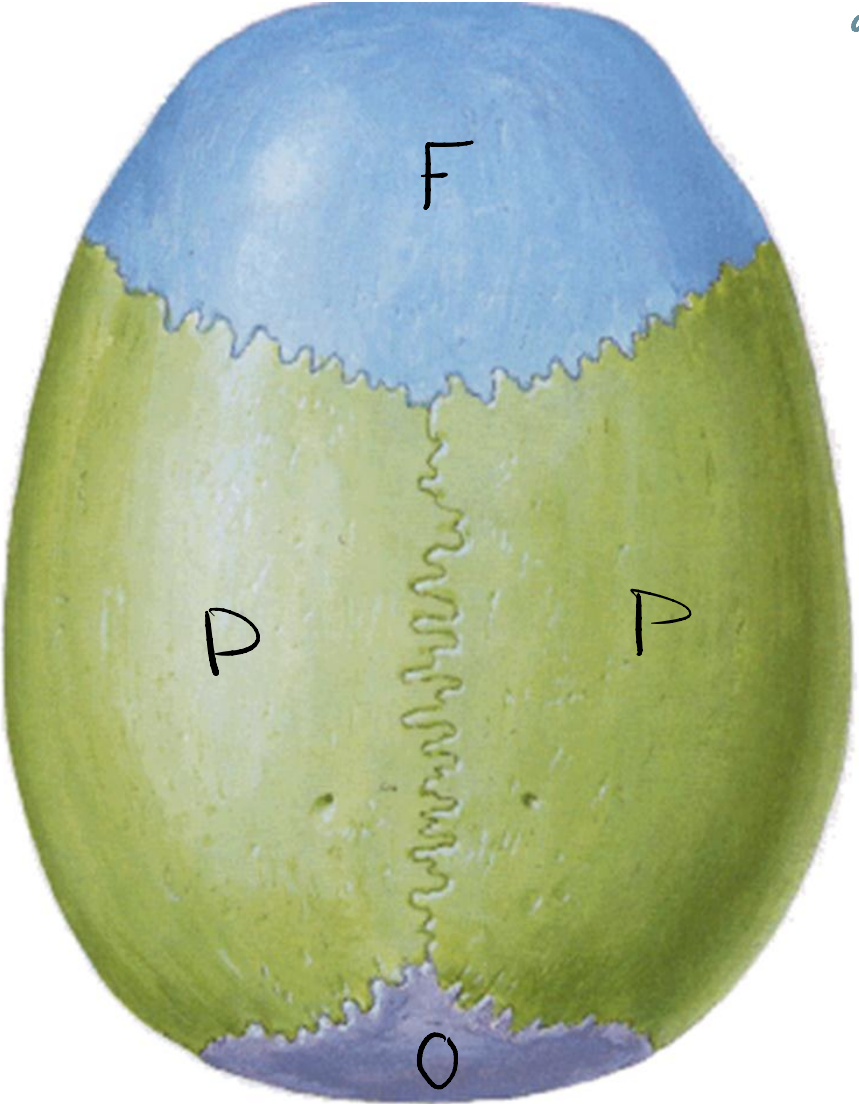
Done By: Wafaa Alfarabshah

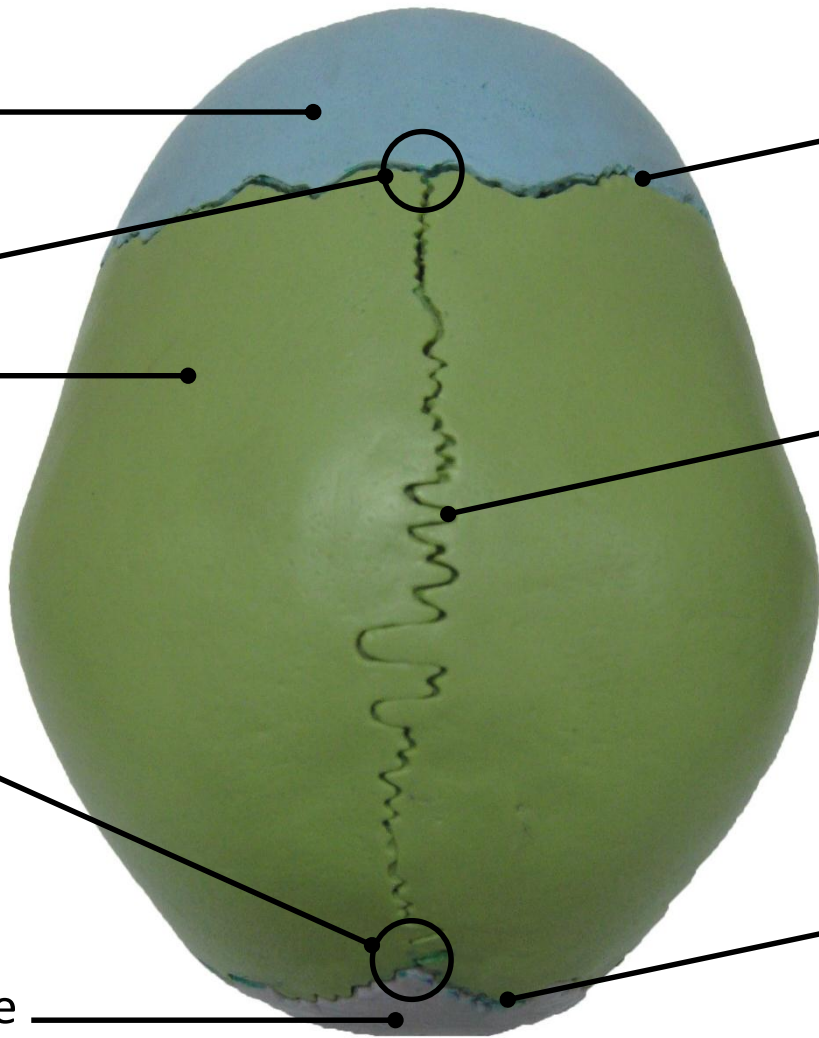
**Lab 1**

**Skull**

# Norma Verticalis

the Superior view  
of the skull





Frontal Bone

Coronal Suture

Between P & F

كانت الـ Anterior fontanelle في الـ babies  
لا تسمح بنمو الـ skull  
حتى عمر 2 سنوات  
Site of IV injection  
in cases of meningitis

Bregma

Parietal Bone

Sagittal Suture

Between P & P

لا أي 2 bones بيقتربوا من

بعض المفردات يعملوا joints

في الـ skull ينسجيم [Imovable] Sutures

Lambda

Lambdoid Suture

Between O & P

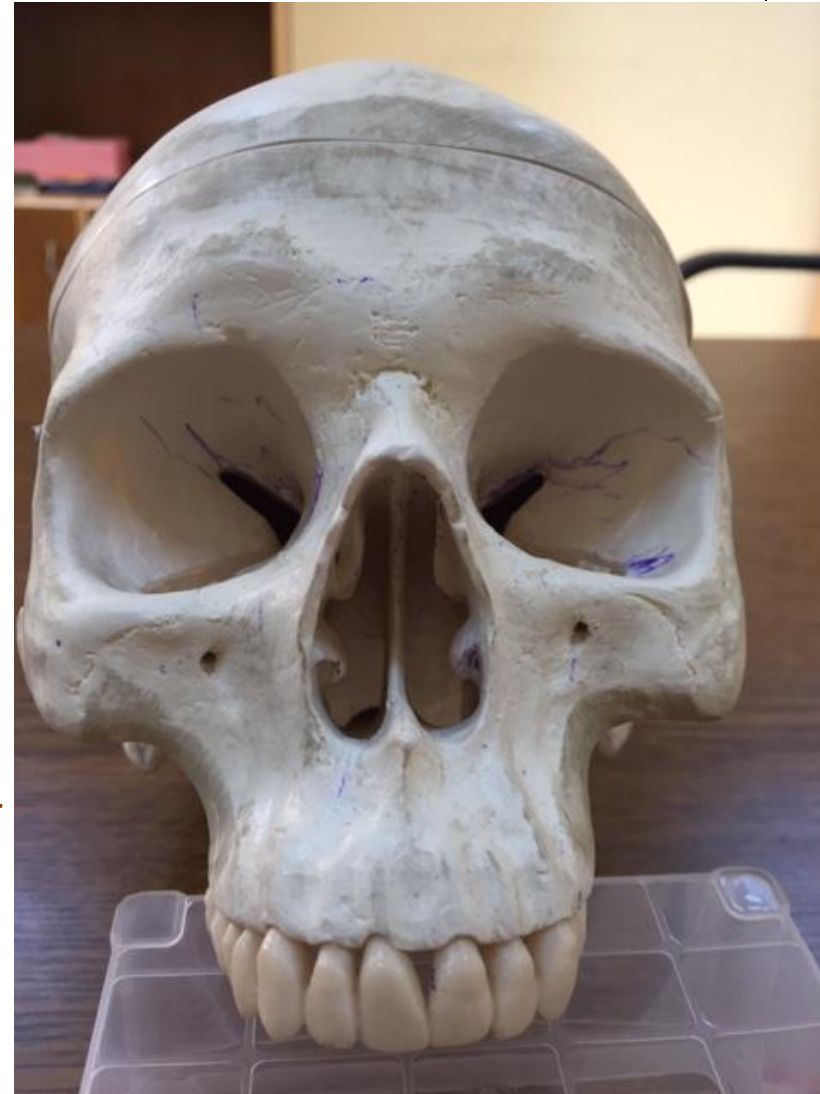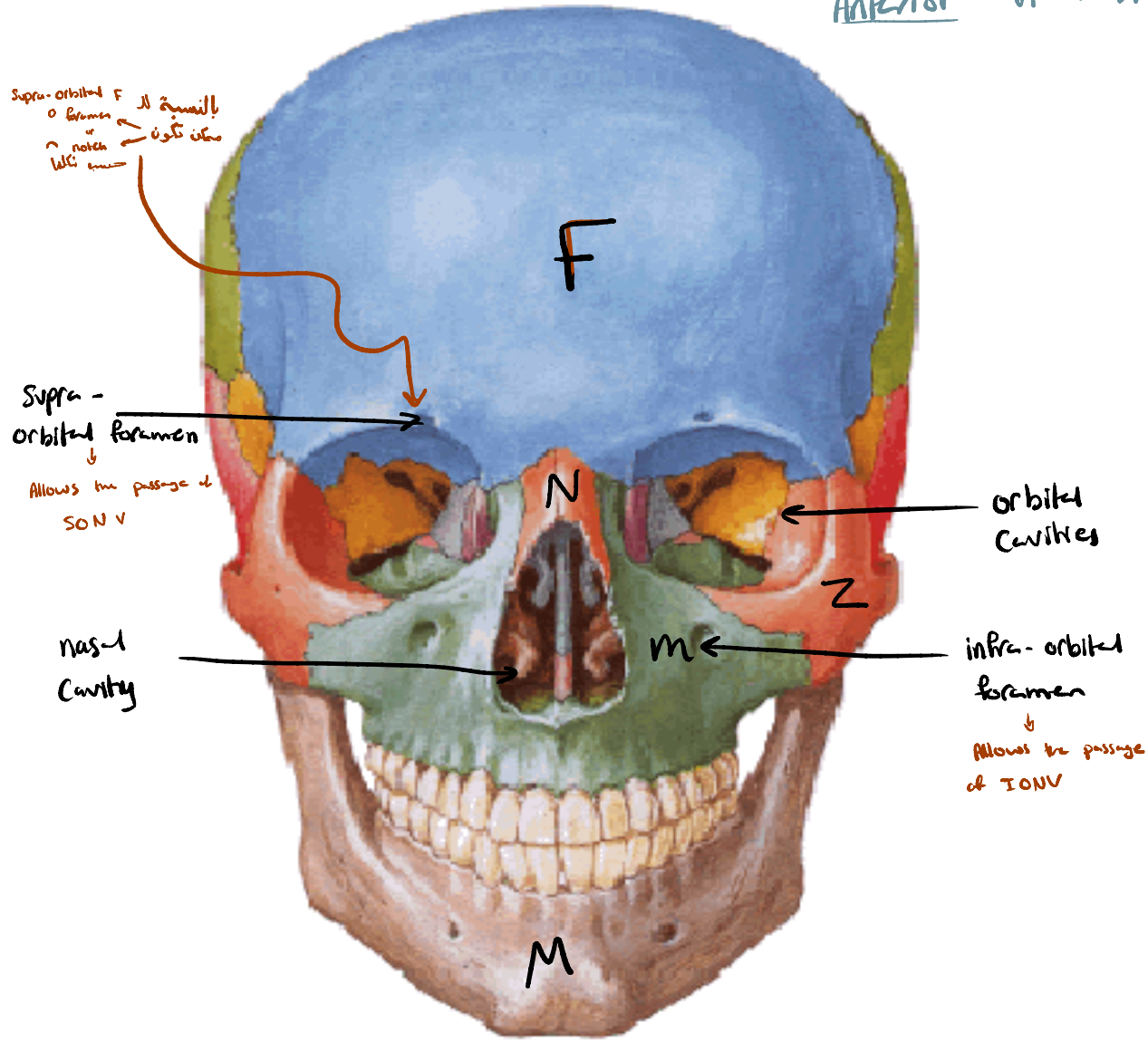
Occipital Bone

# Norma Frontalis

Anterior view of the skull

formed by


- N
- F
- M
- Z
- Mandible



Frontal Bone



Nasal Bone



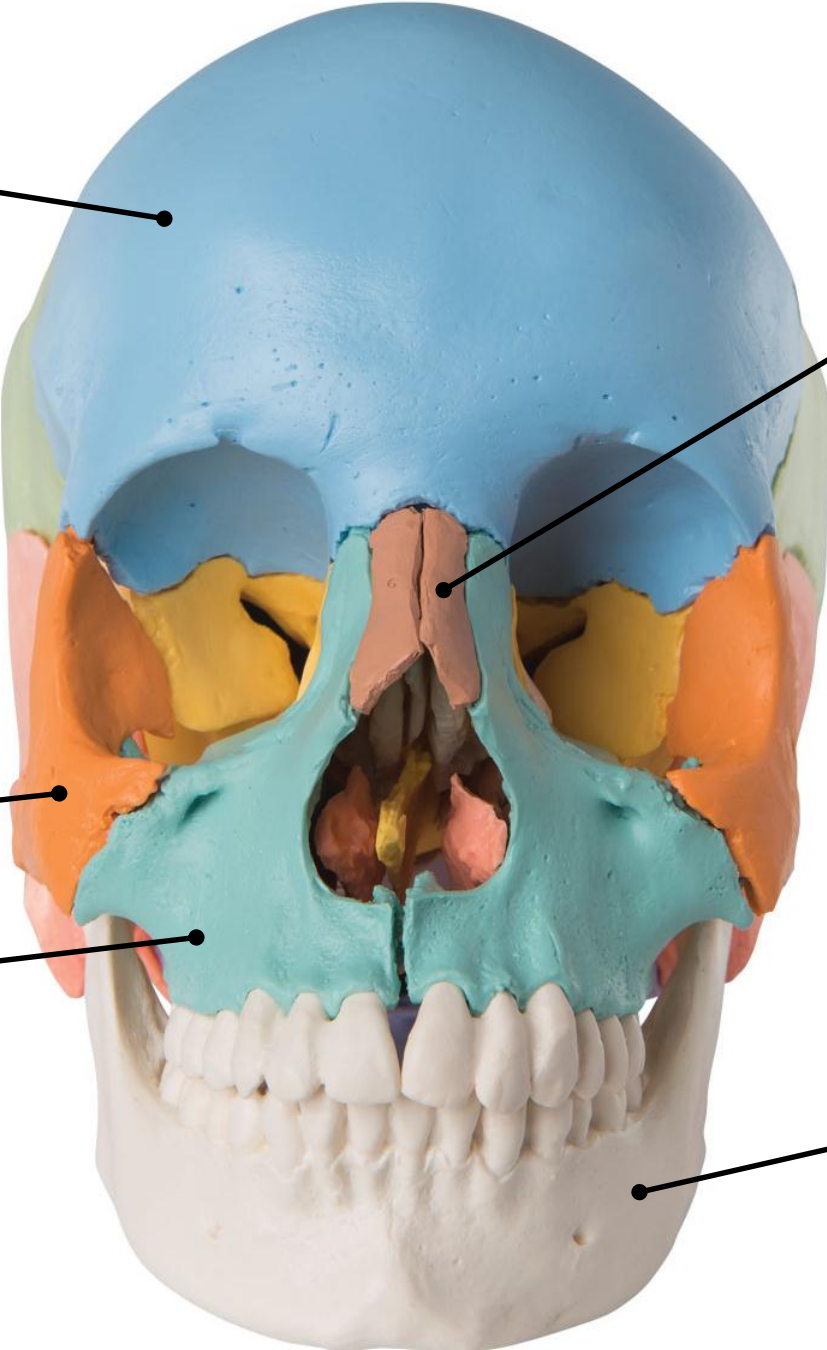
Zygomatic Bone



Maxillary Bone



Mandible



Frontal Bone



Supraorbital Foramen (Notch)



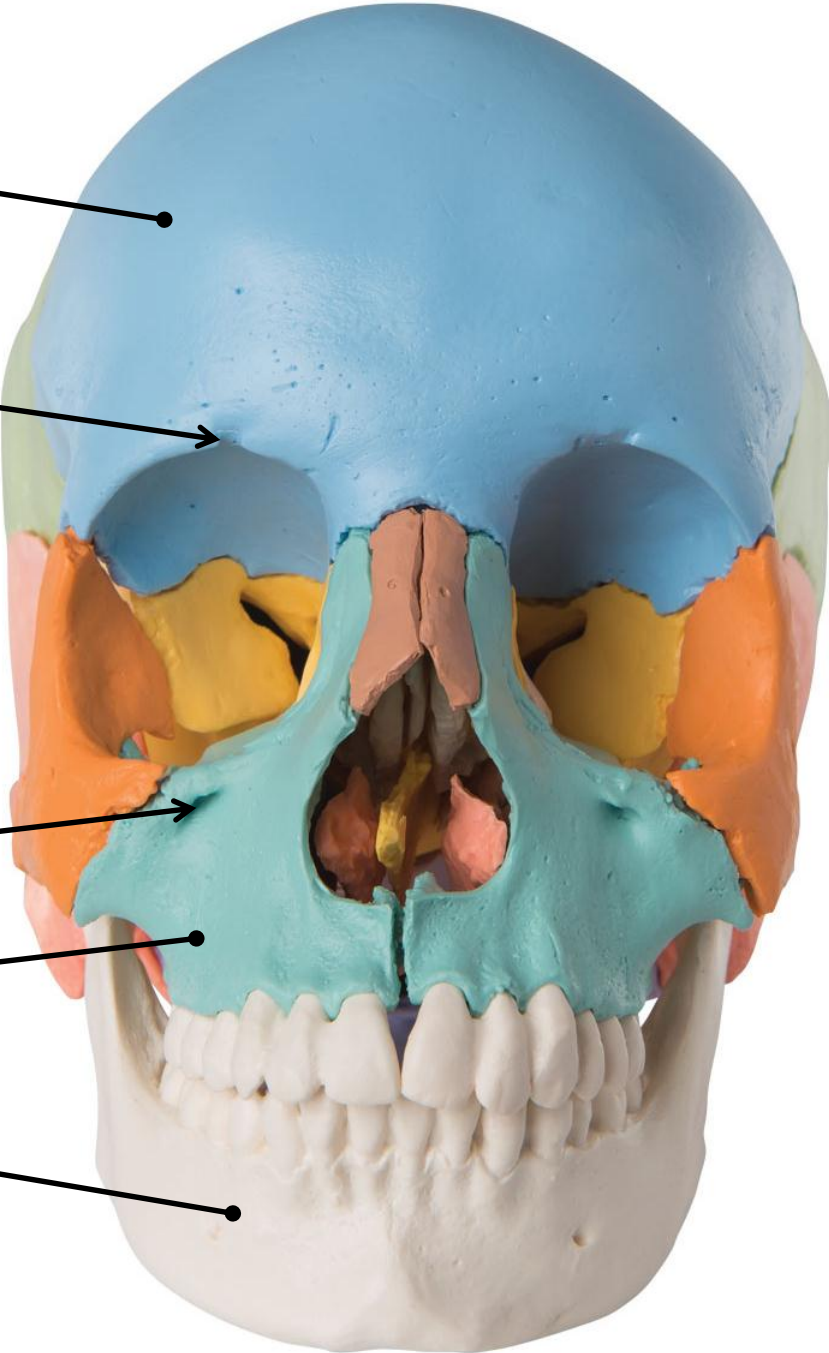
Infraorbital Foramen



Maxillary Bone

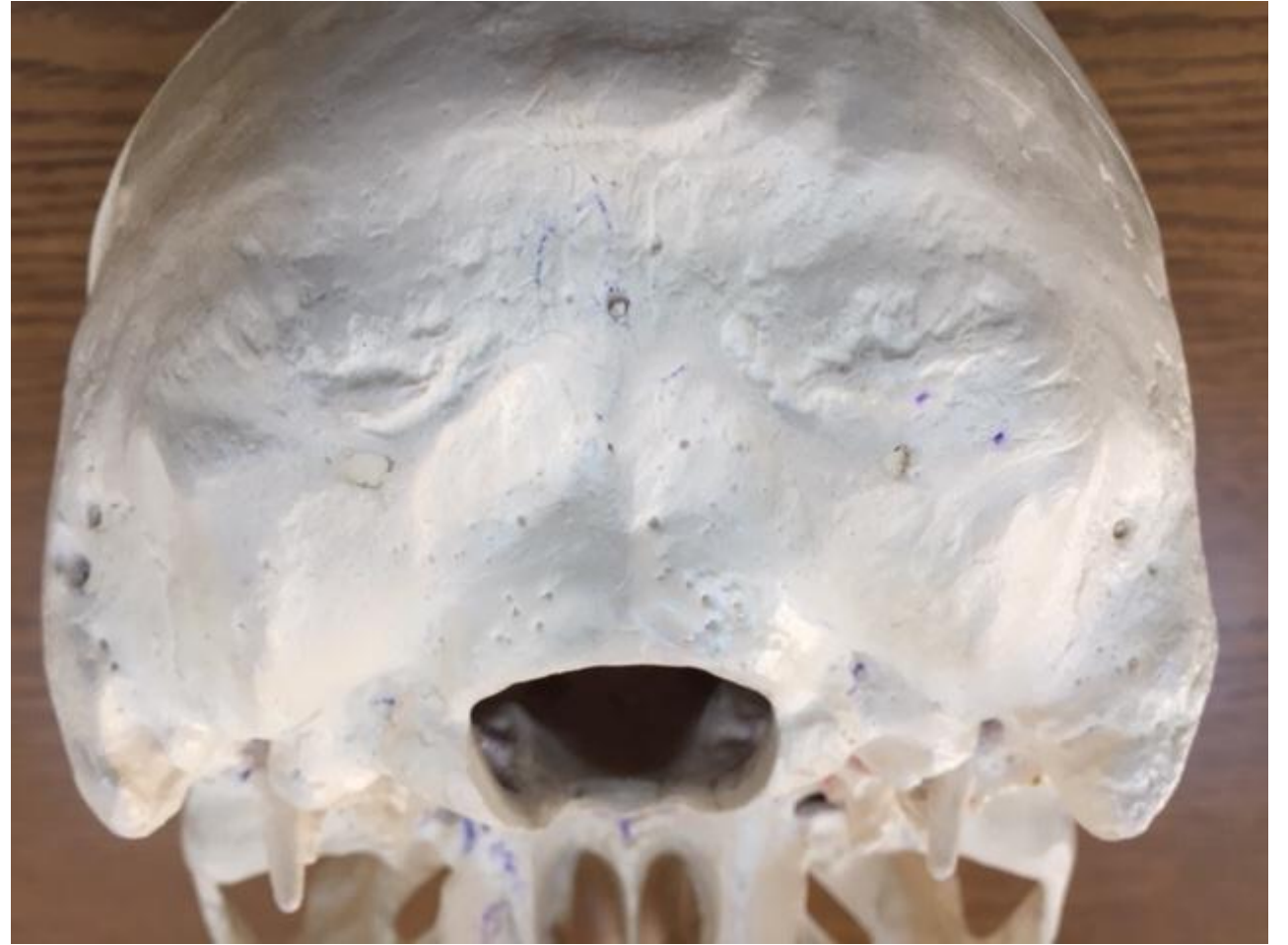
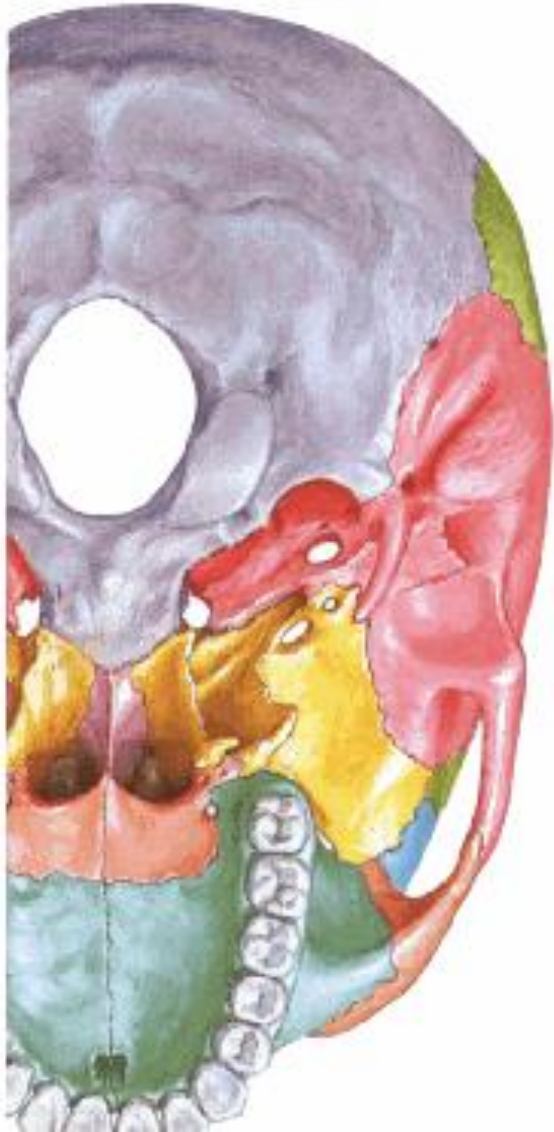
Mandible

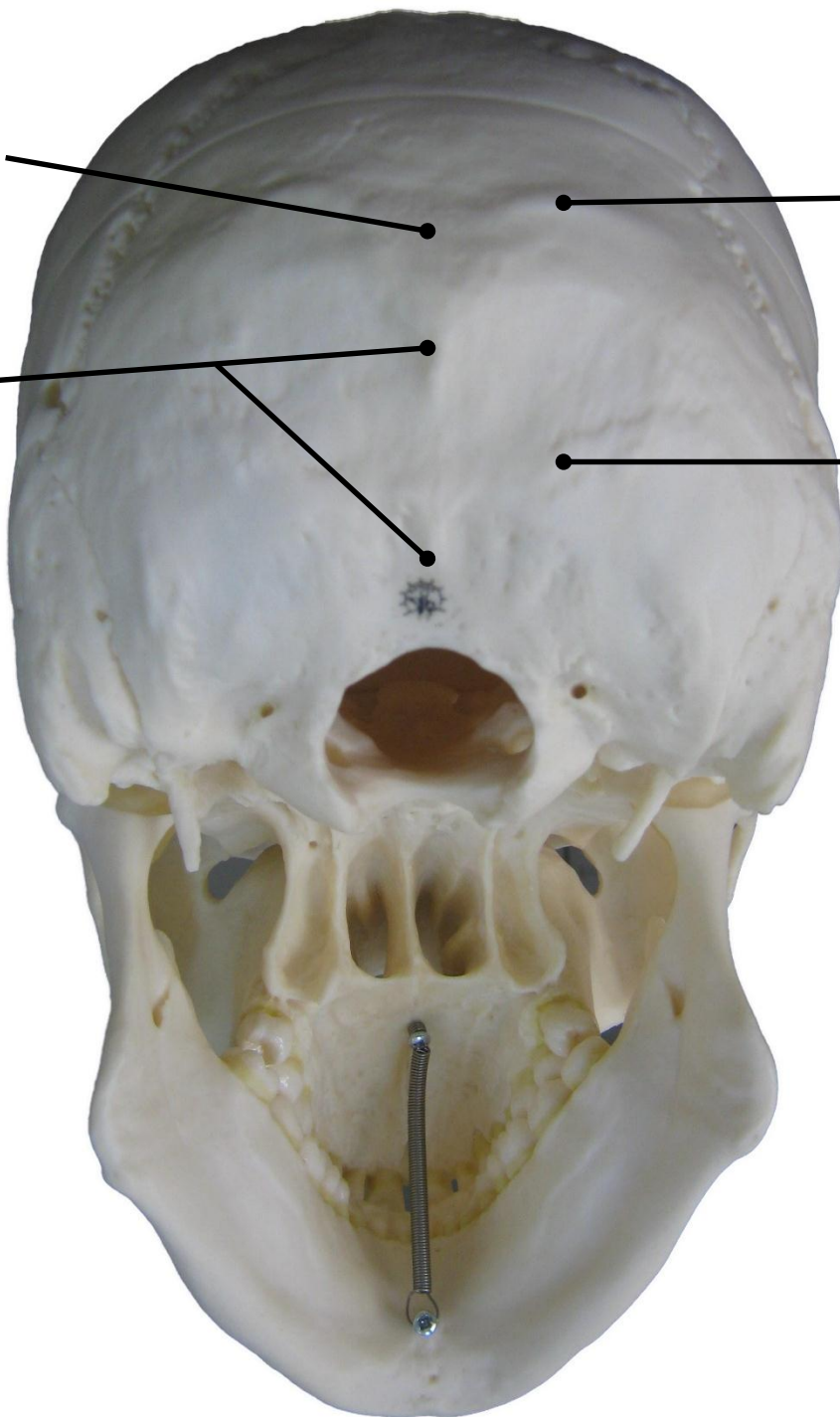


# Norma Occipitalis

The posterior view of the skull







External Occipital Protuberance

بروز [process]   
 آغزی نقلتہ یا ار protuberance گوں ار inton

Superior Nuchal Line

\* بکون طالع من ال protuberance

External Occipital Crest

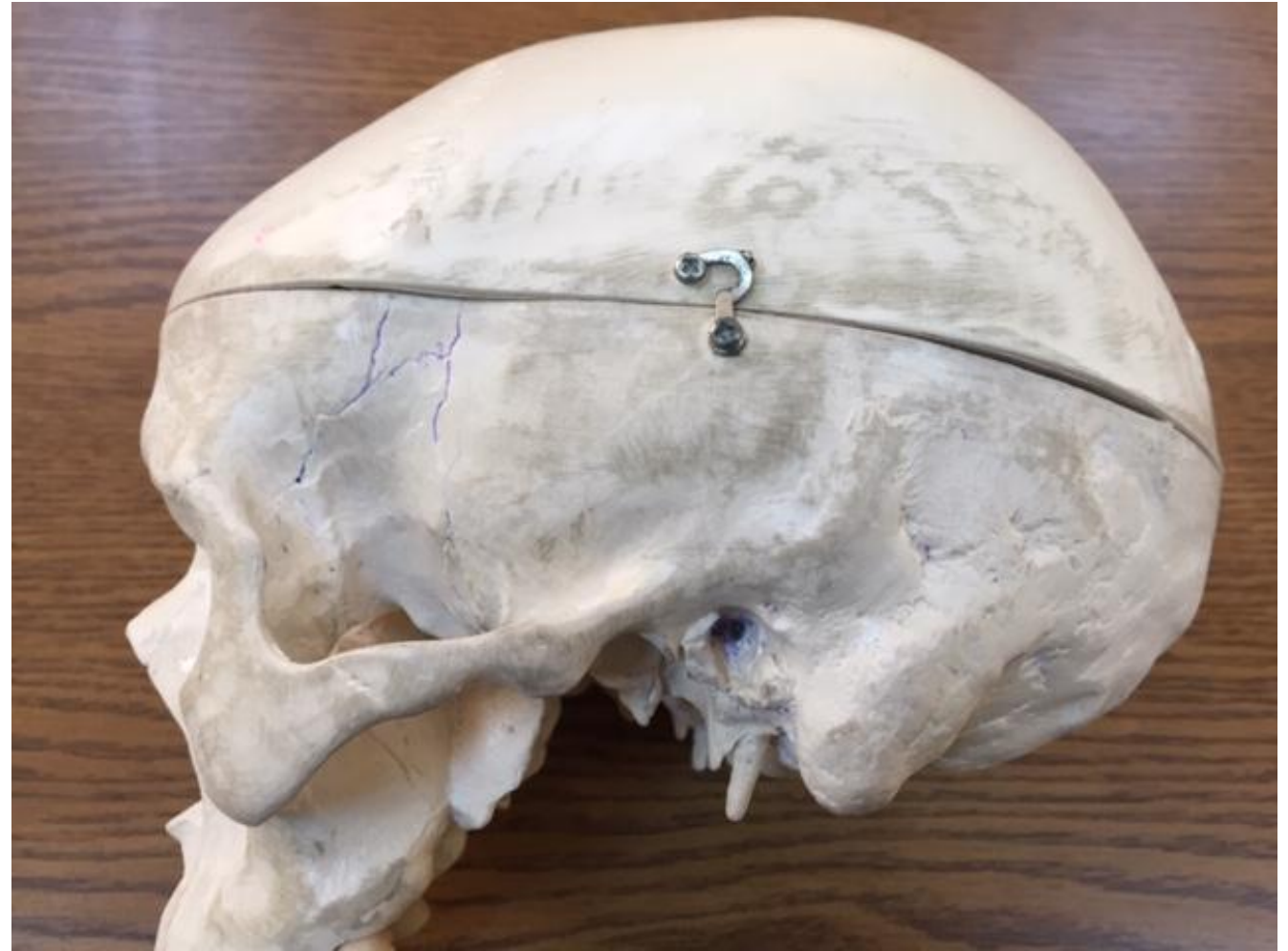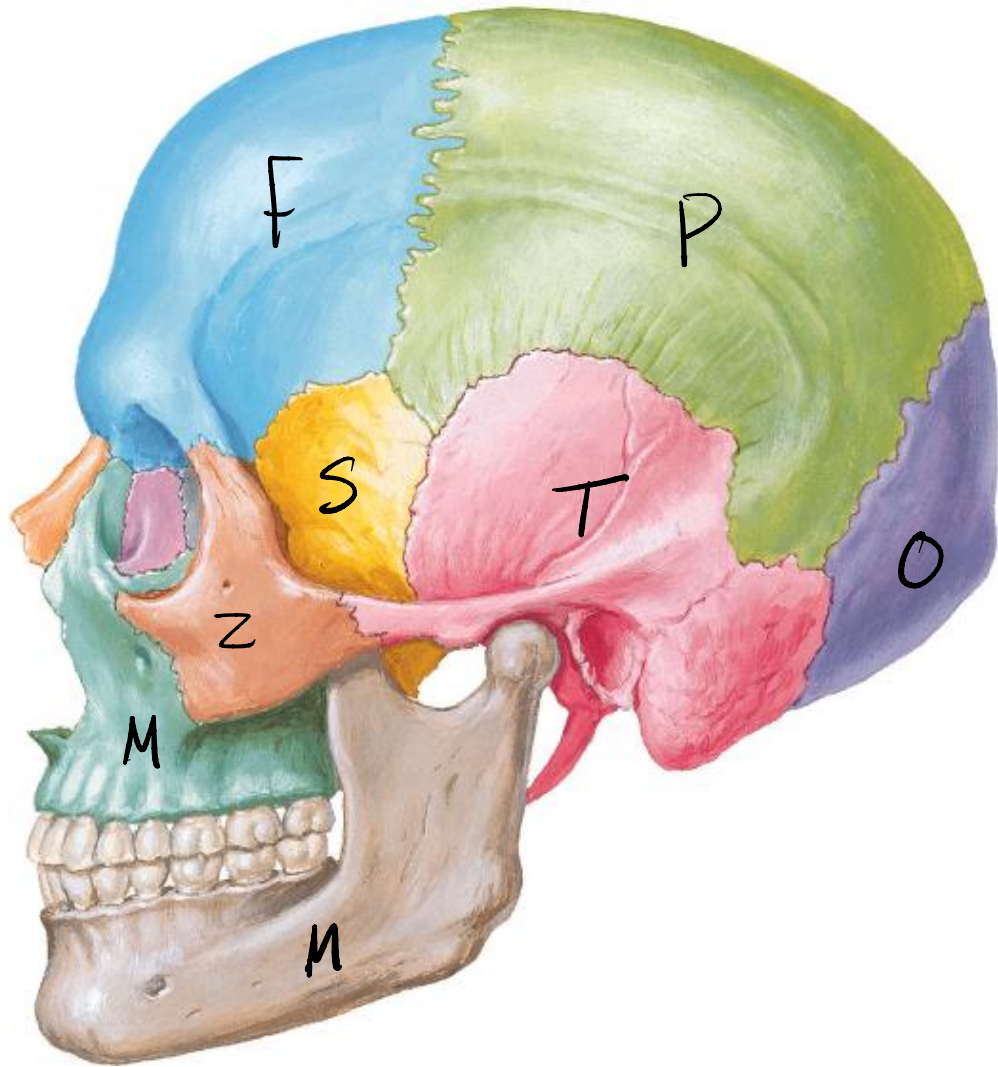
Sharp line seperating   
 2 surfaces .

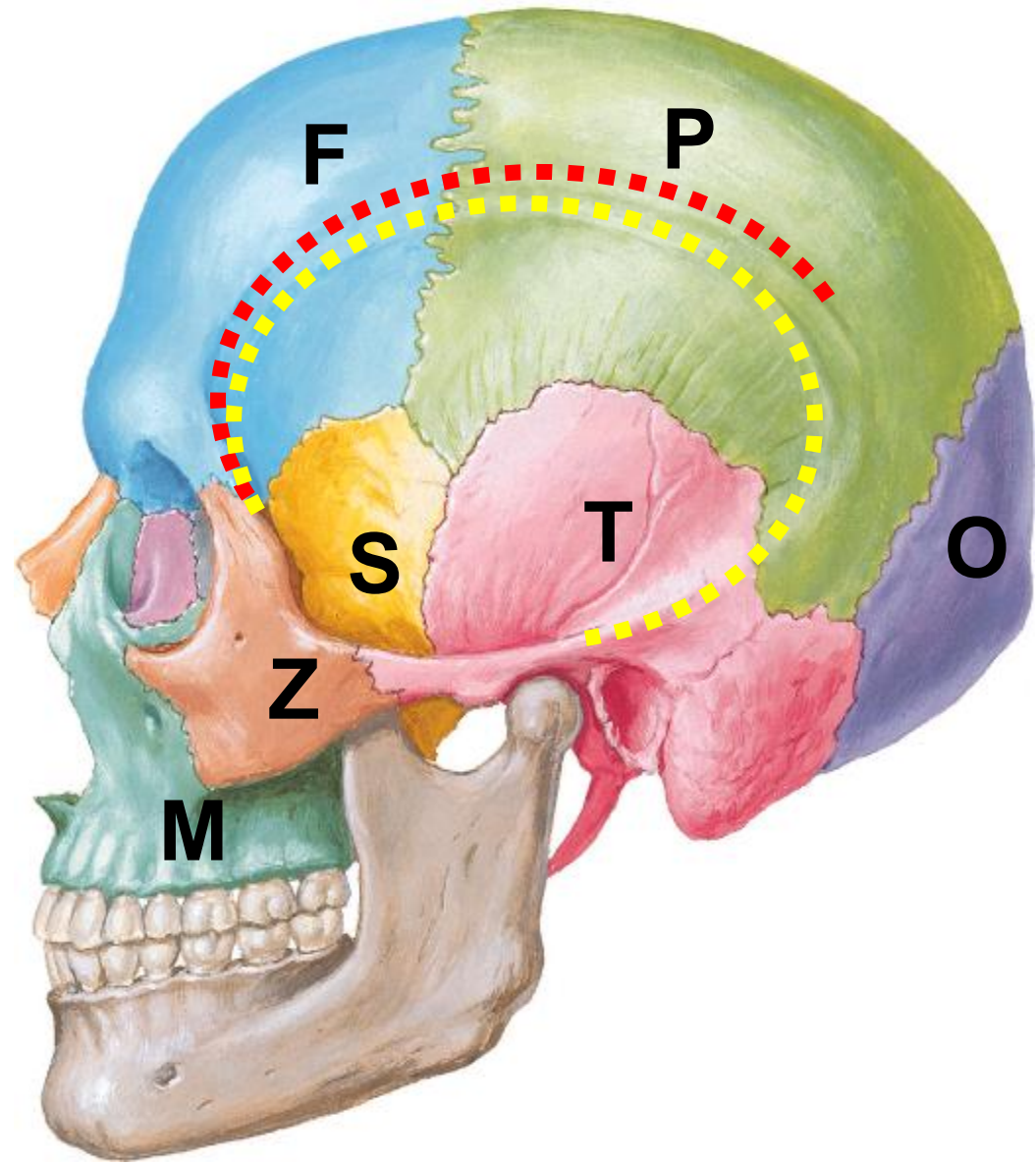
Inferior Nuchal Line

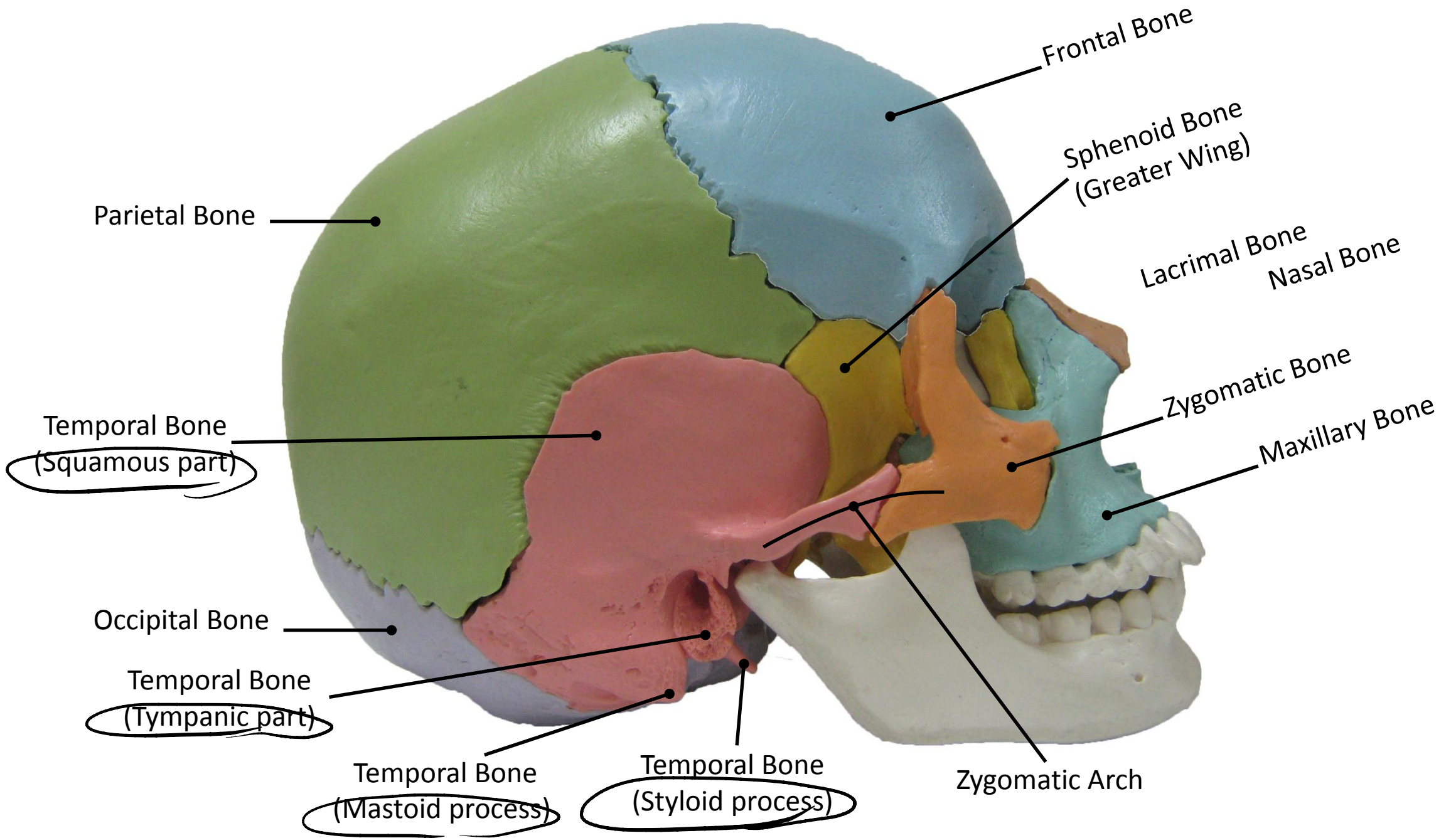
\* بکون طالع من ال crest

# Norma Lateralis

The lateral view of the skull







إصابة ال Pterion تؤدي إلى  
 extra-axial middle meningeal A ال  
 hemorrhage  
 والذي يؤثر على ال motor area  
 و يهبط على الاعراض التالية:  
 1- vomiting  
 2- headache  
 3- blurry vision

Superior Temporal Line

Inferior Temporal Line

Pterion → middle meningeal A passes through Pterion  
 H shaped suture connecting  
 4 bones  $\begin{matrix} F \\ P \\ T \\ S \end{matrix}$

Sphenoid Bone  
 (Greater Wing)

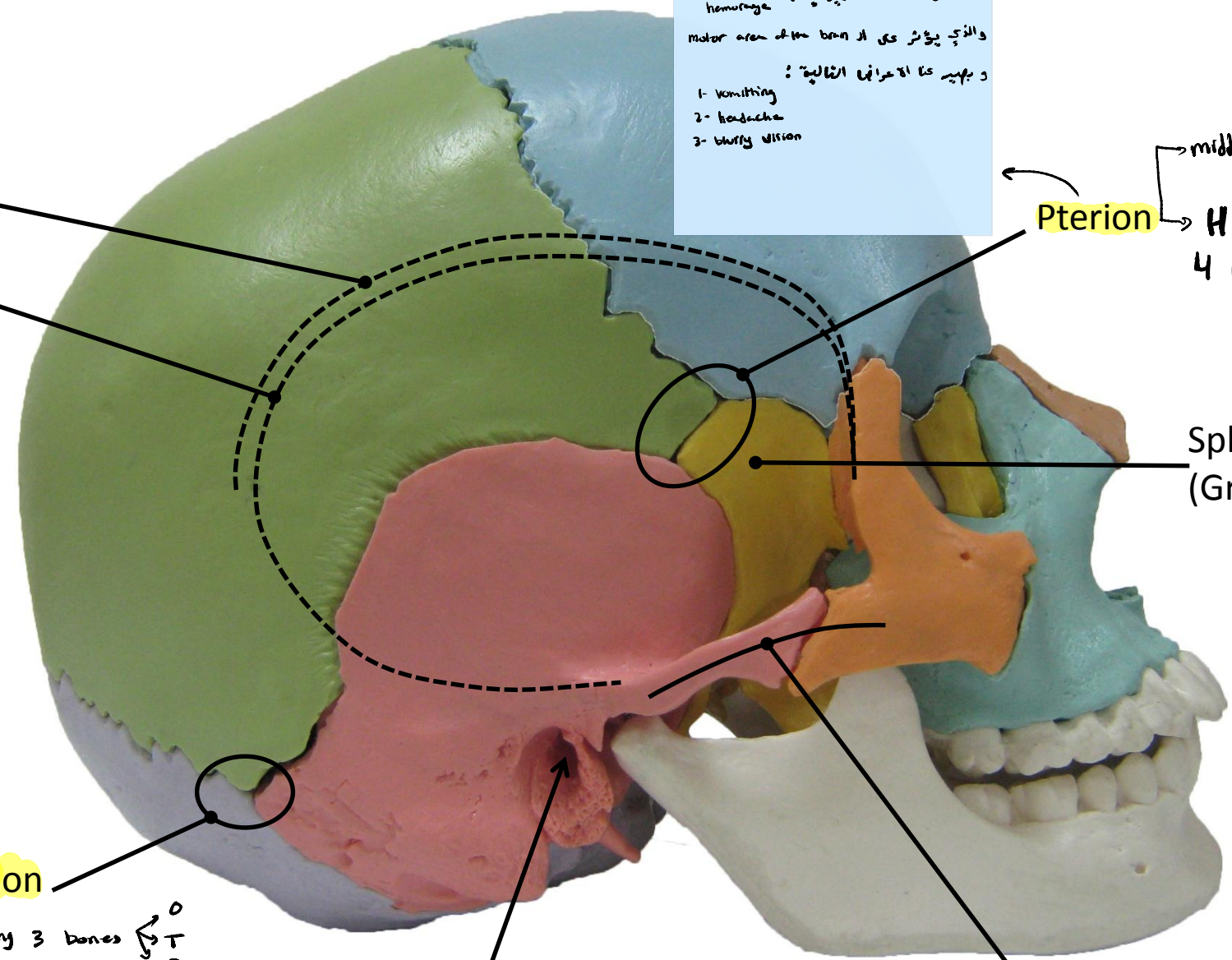
Asterion

Suture connecting 3 bones  $\begin{matrix} O \\ T \\ P \end{matrix}$

External Auditory Meatus

Zygomatic Arch

→ made of  $\begin{cases} \text{Zygomatic process of temporal bone} \\ \text{Temporal process of zygomatic bone} \end{cases}$

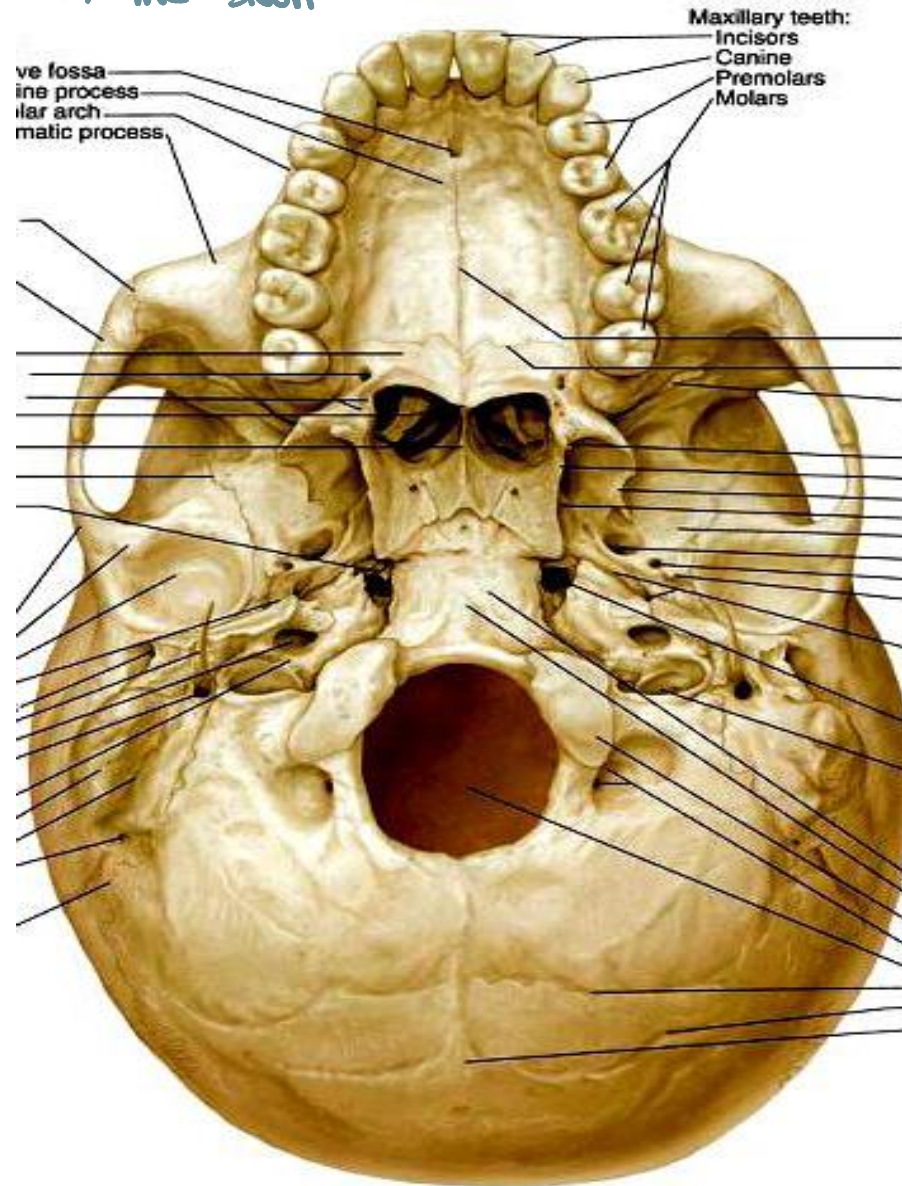
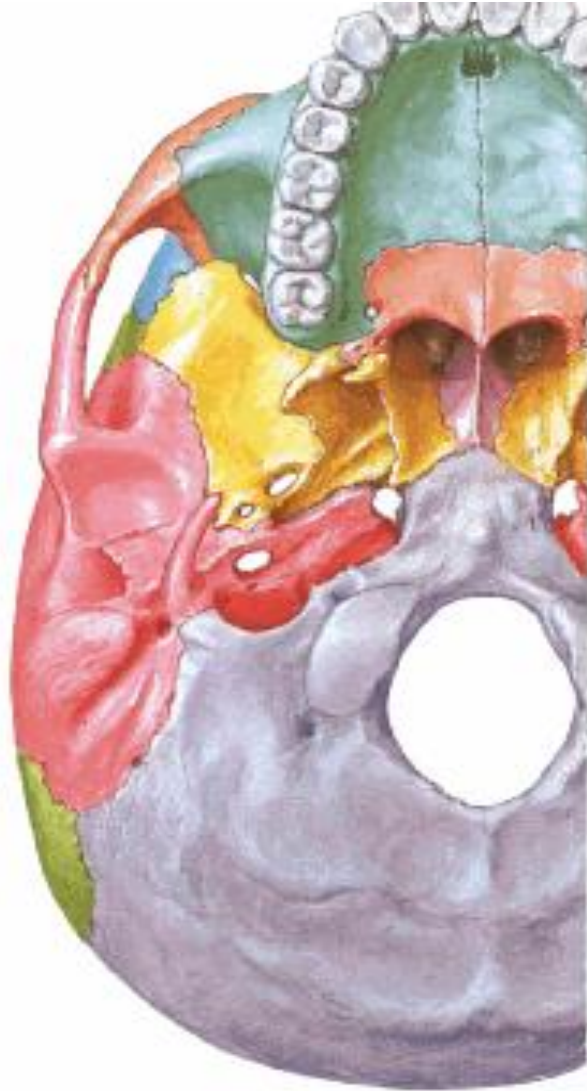

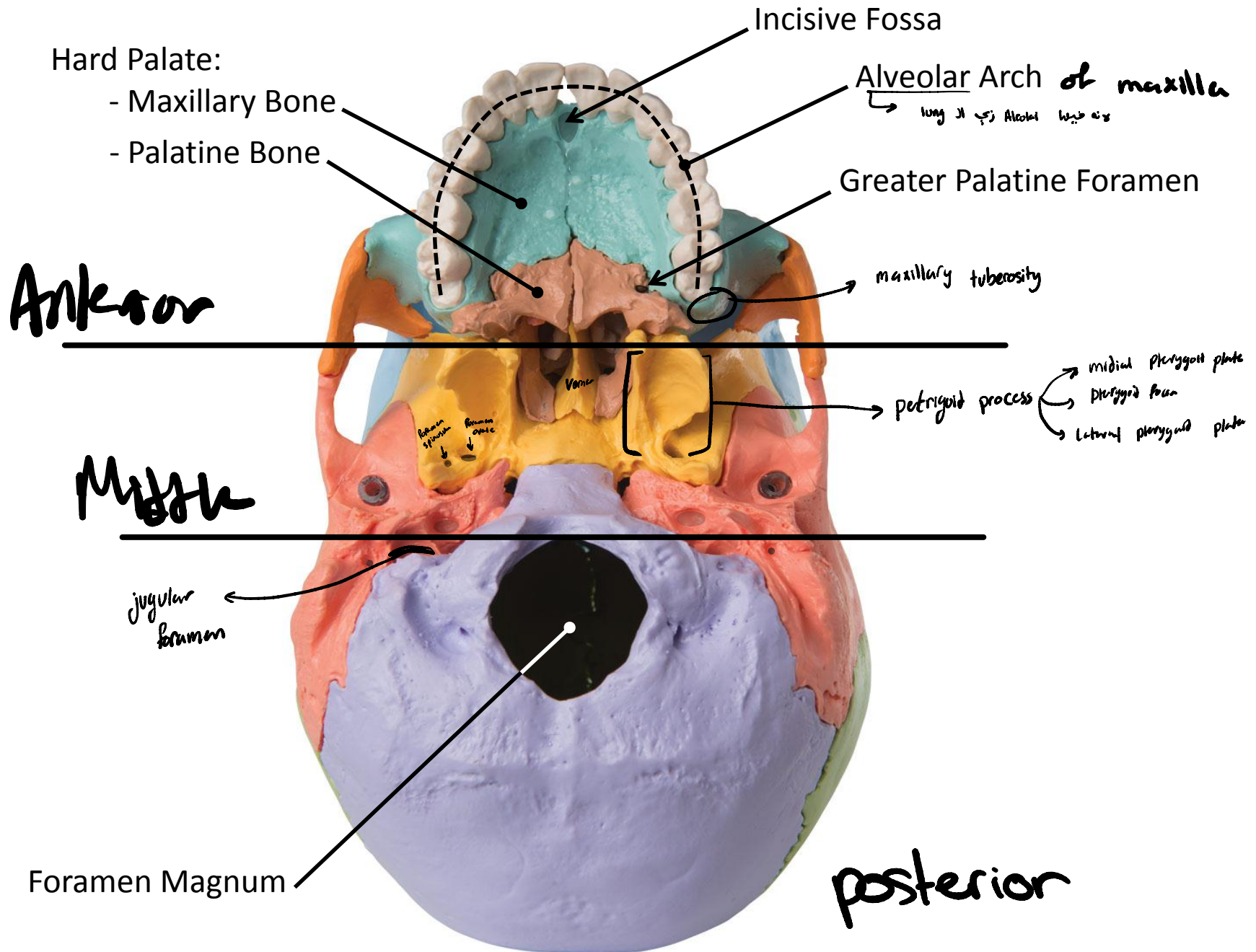
# Norma Basalis Externa

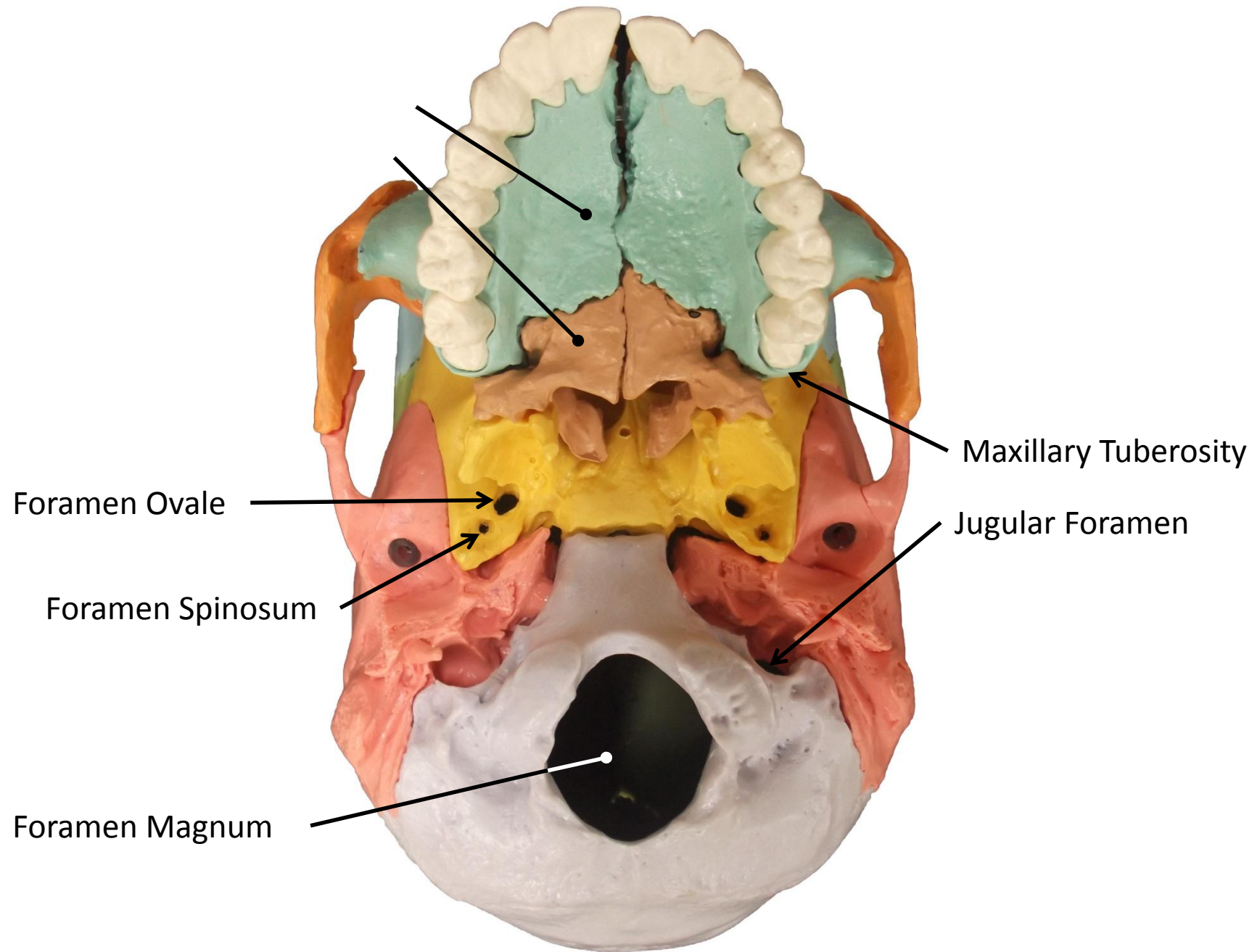
3

أجزاء

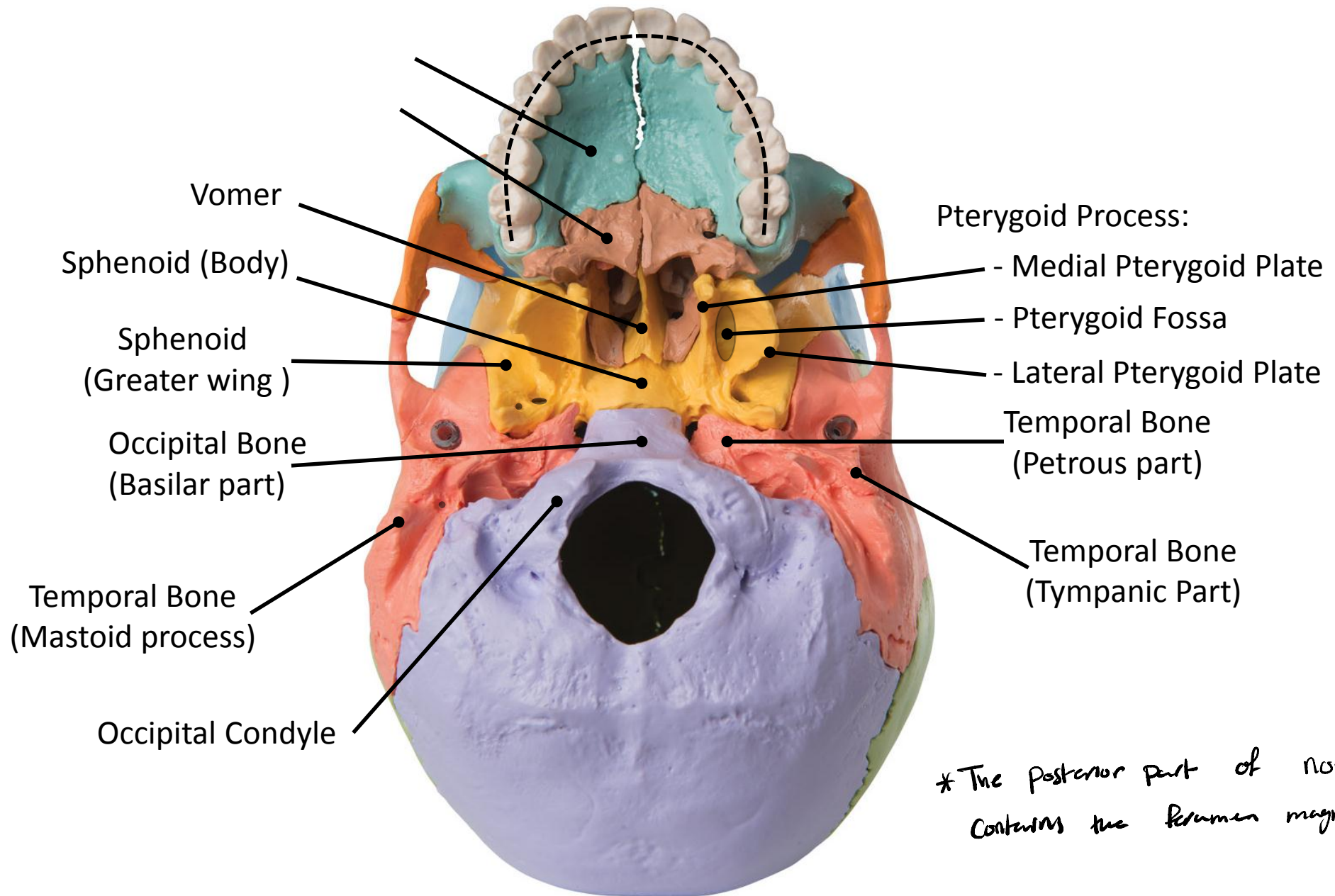
The inferior view of the skull





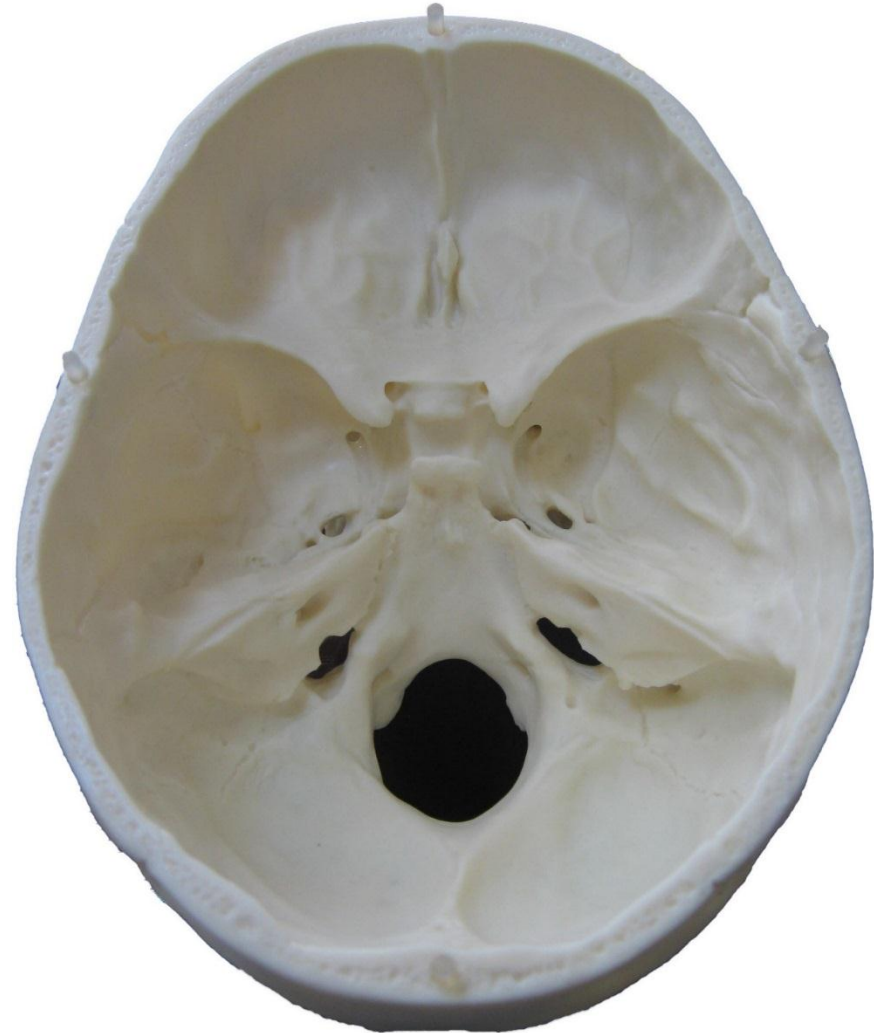
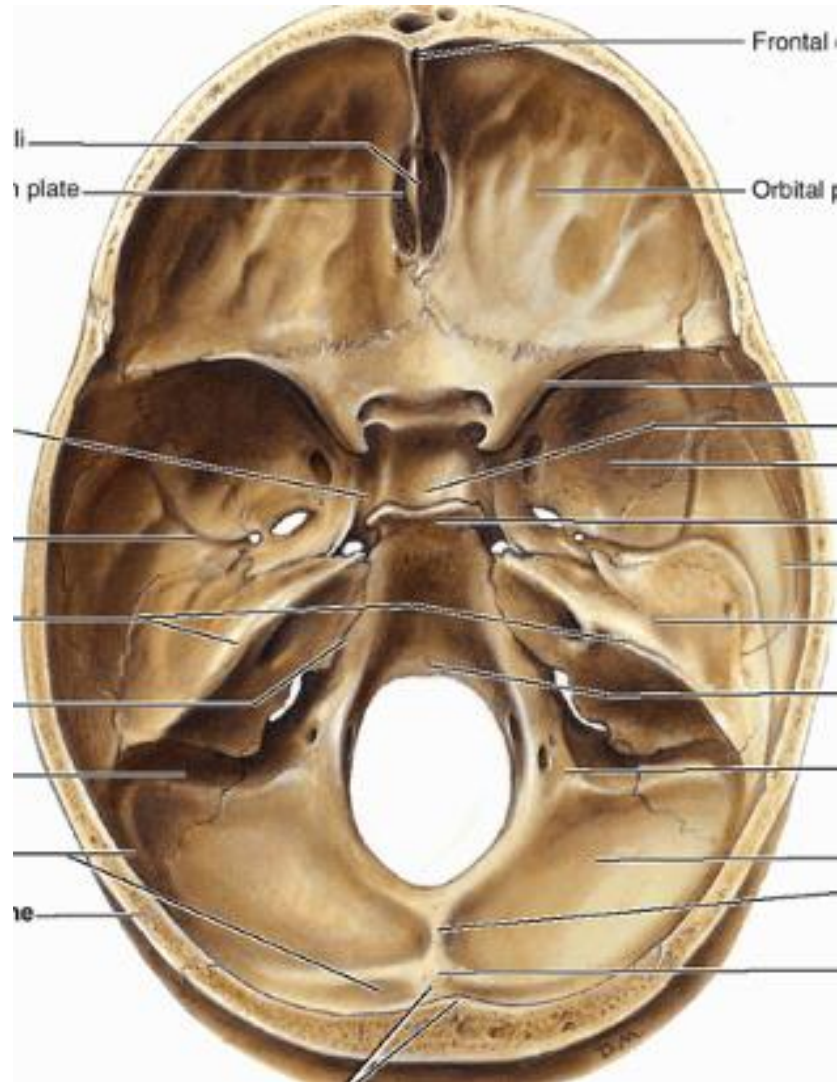






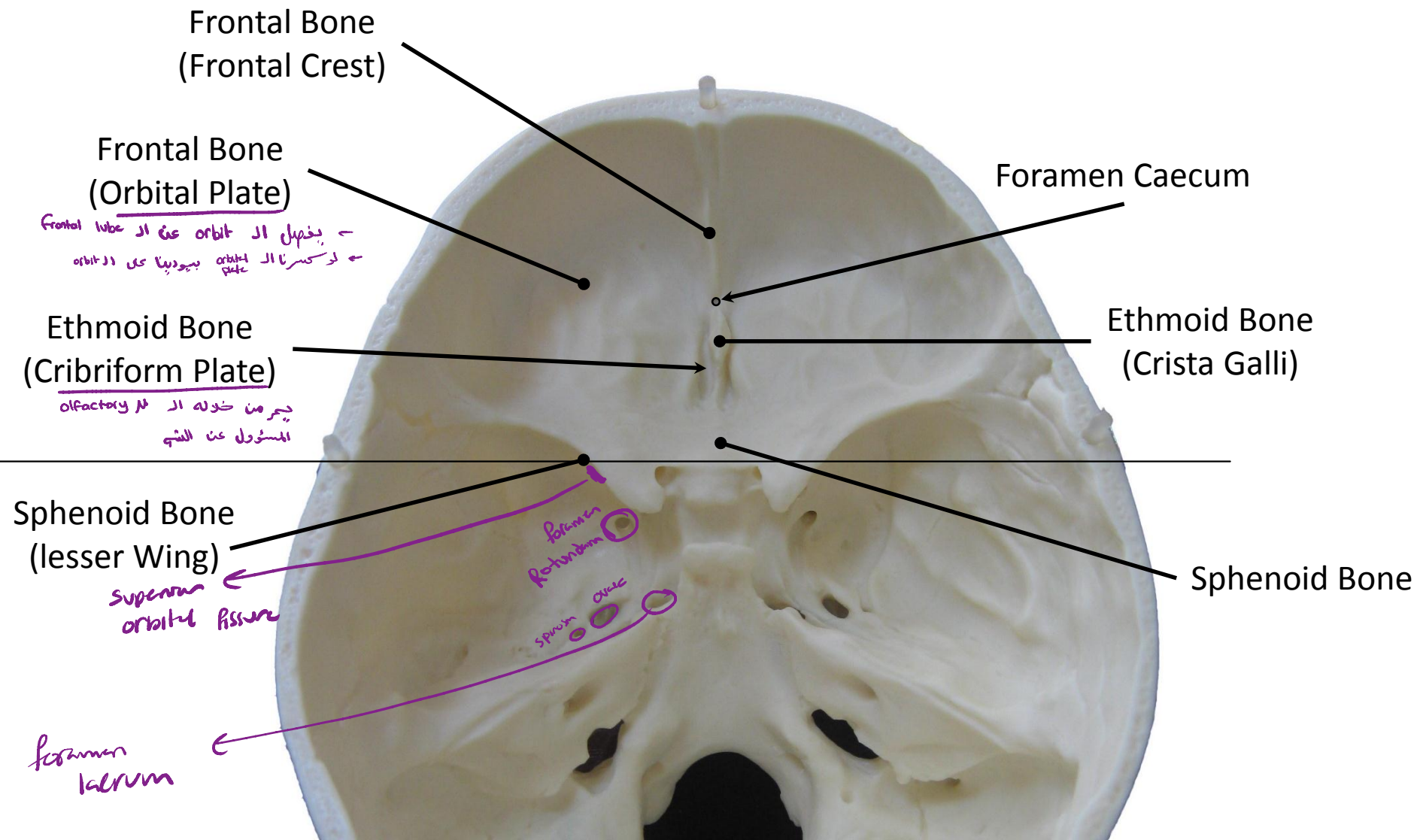
# Cranial Cavity

The internal view of the skull



Anterior cranial fossa ← lesser wing of sphenoid ← Frontal sinus

Antrum



Middle cranial fossa ← Petrous part of temporal bone ← lesser wing of sphenoid

middle



Sphenoid Bone (Body)

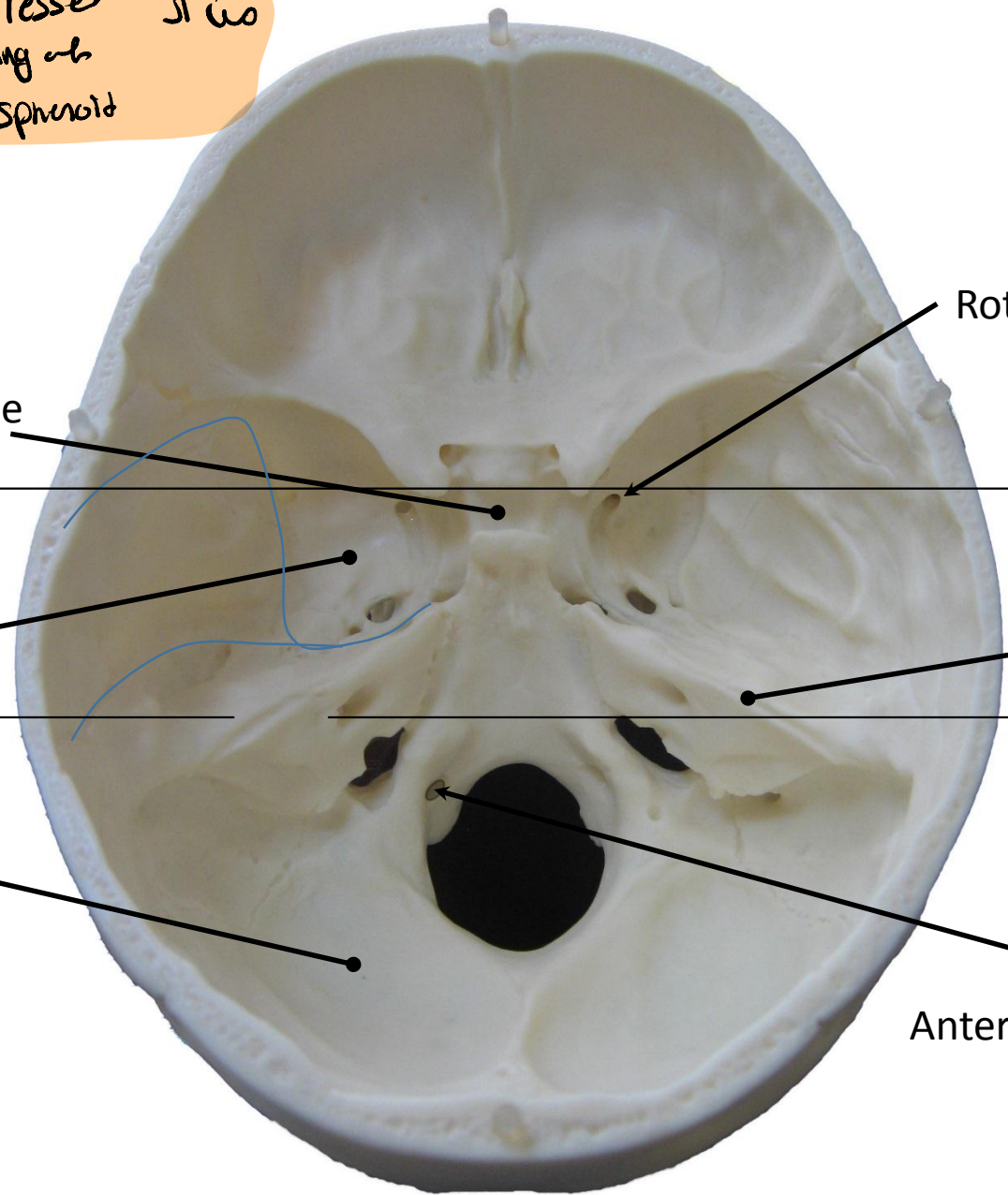
Sphenoid Bone (Greater Wing)

Occipital Bone

Rotundum Foramen

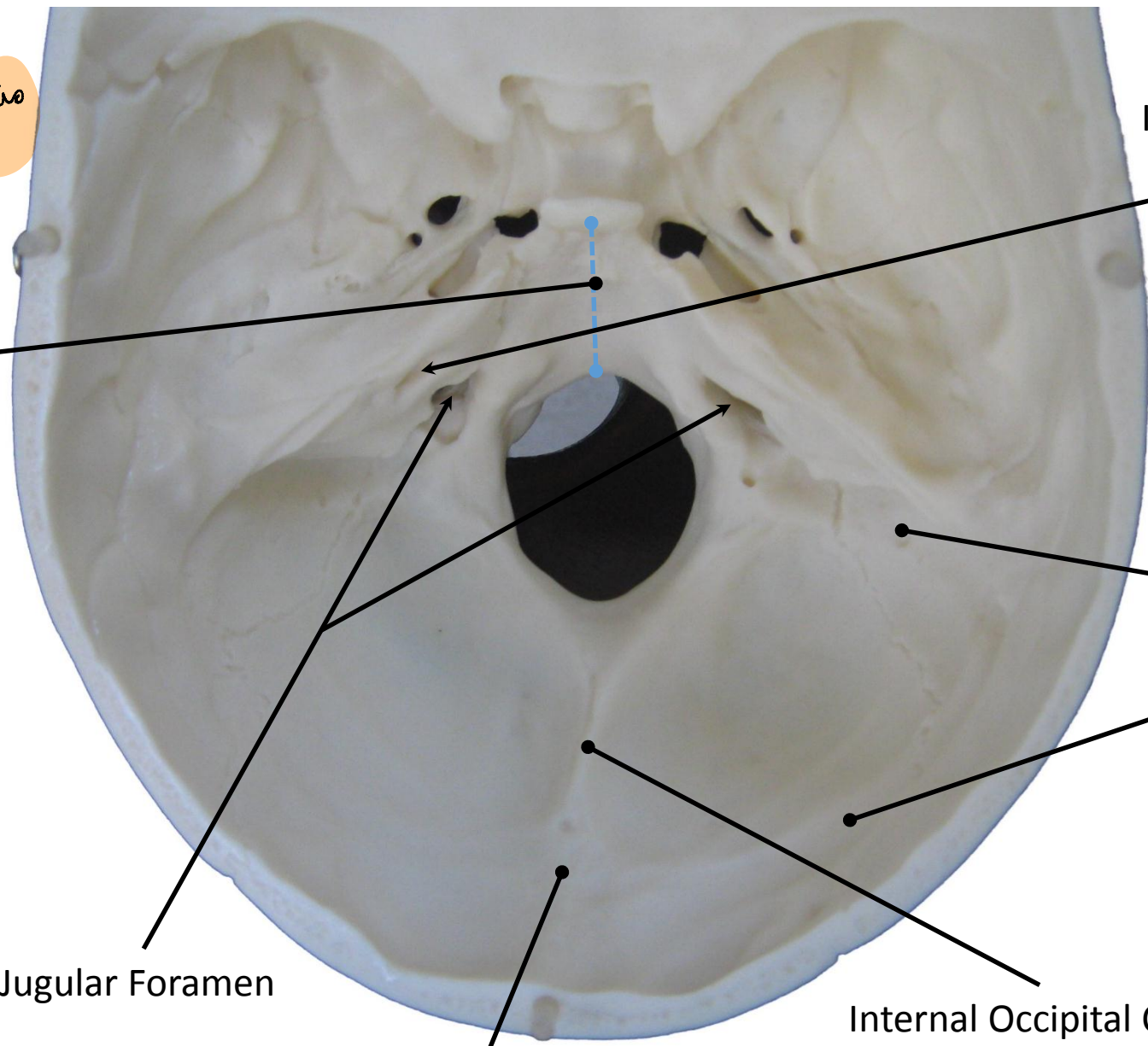
Temporal Bone (Petrous Part)

Anterior Condylar Foramen (Hypoglossal)



posterior cranial fossa ← occipital bone ← petrous part of temporal bone

posterior



Clivus

Internal Auditory Meatus

Sigmoid Sulcus

Transverse Sulcus

Internal Occipital Crest

Internal Occipital Protuberance

Jugular Foramen

