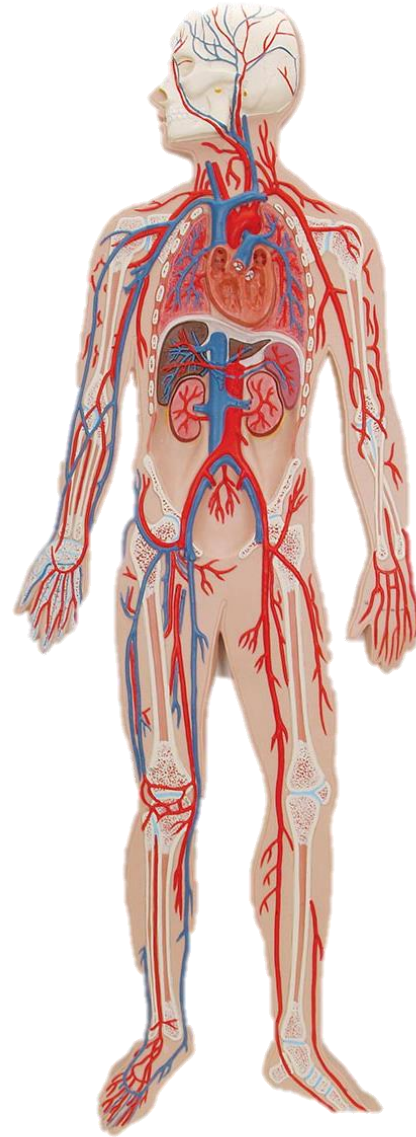
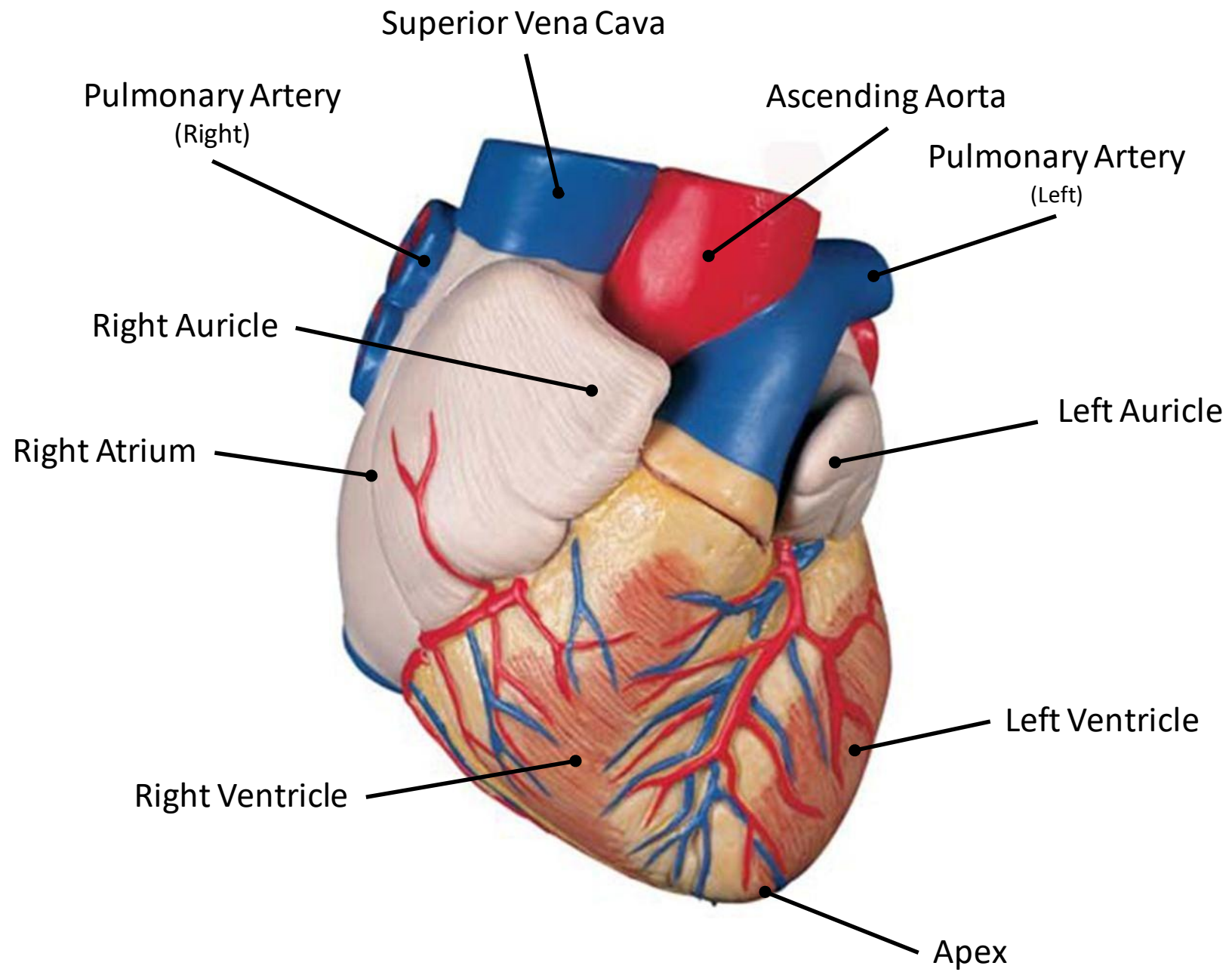
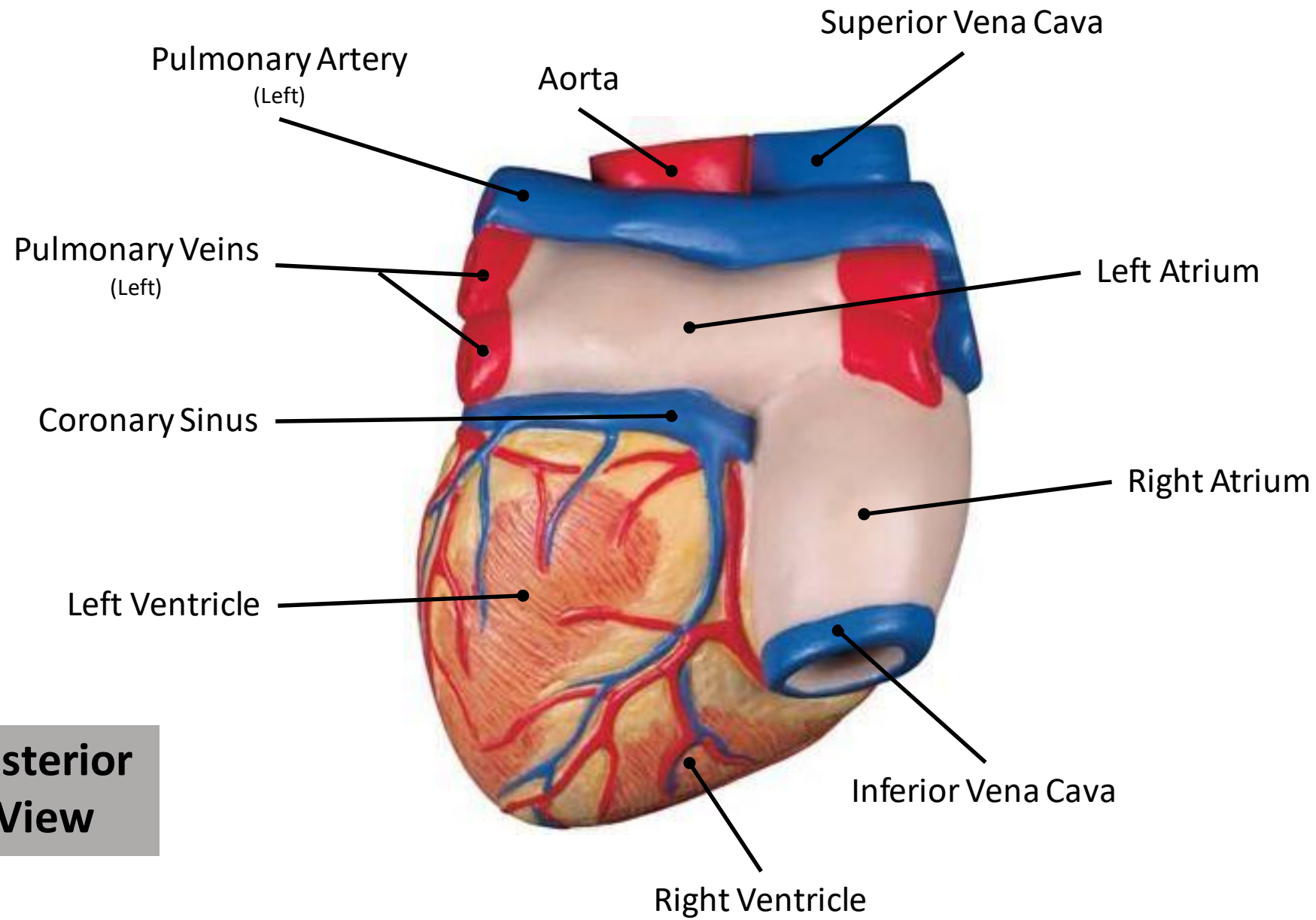


Lab 8

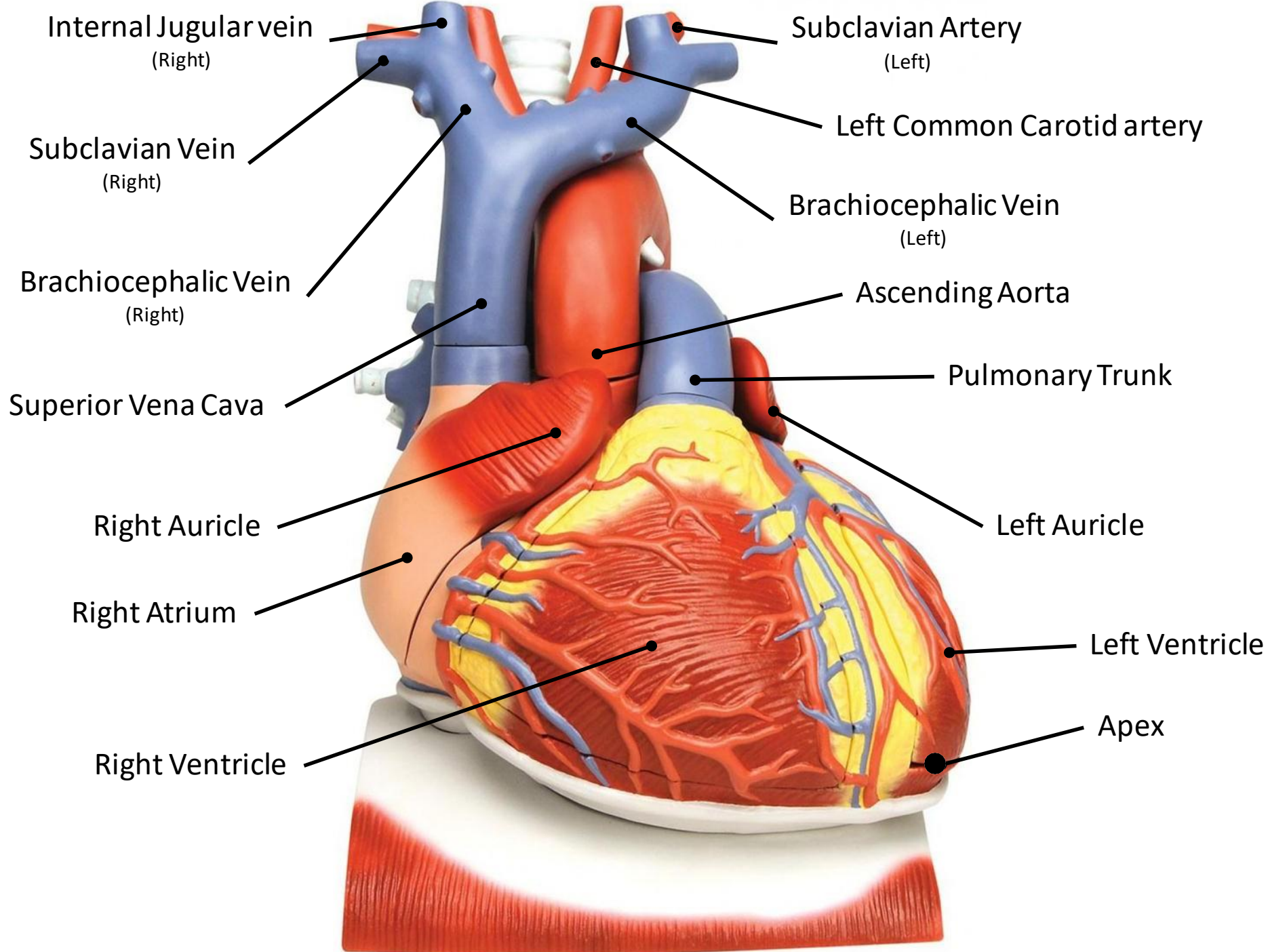
CVS



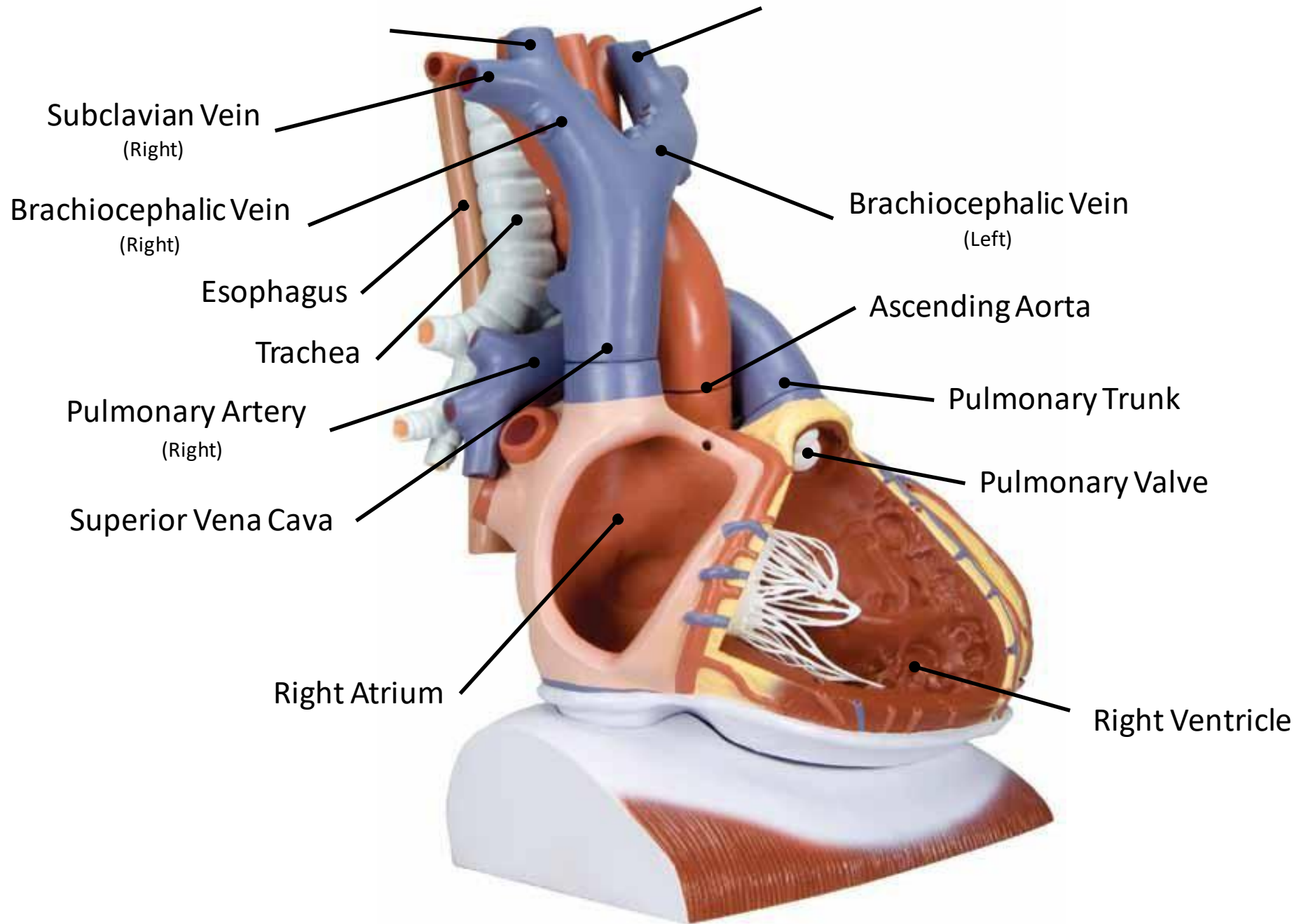


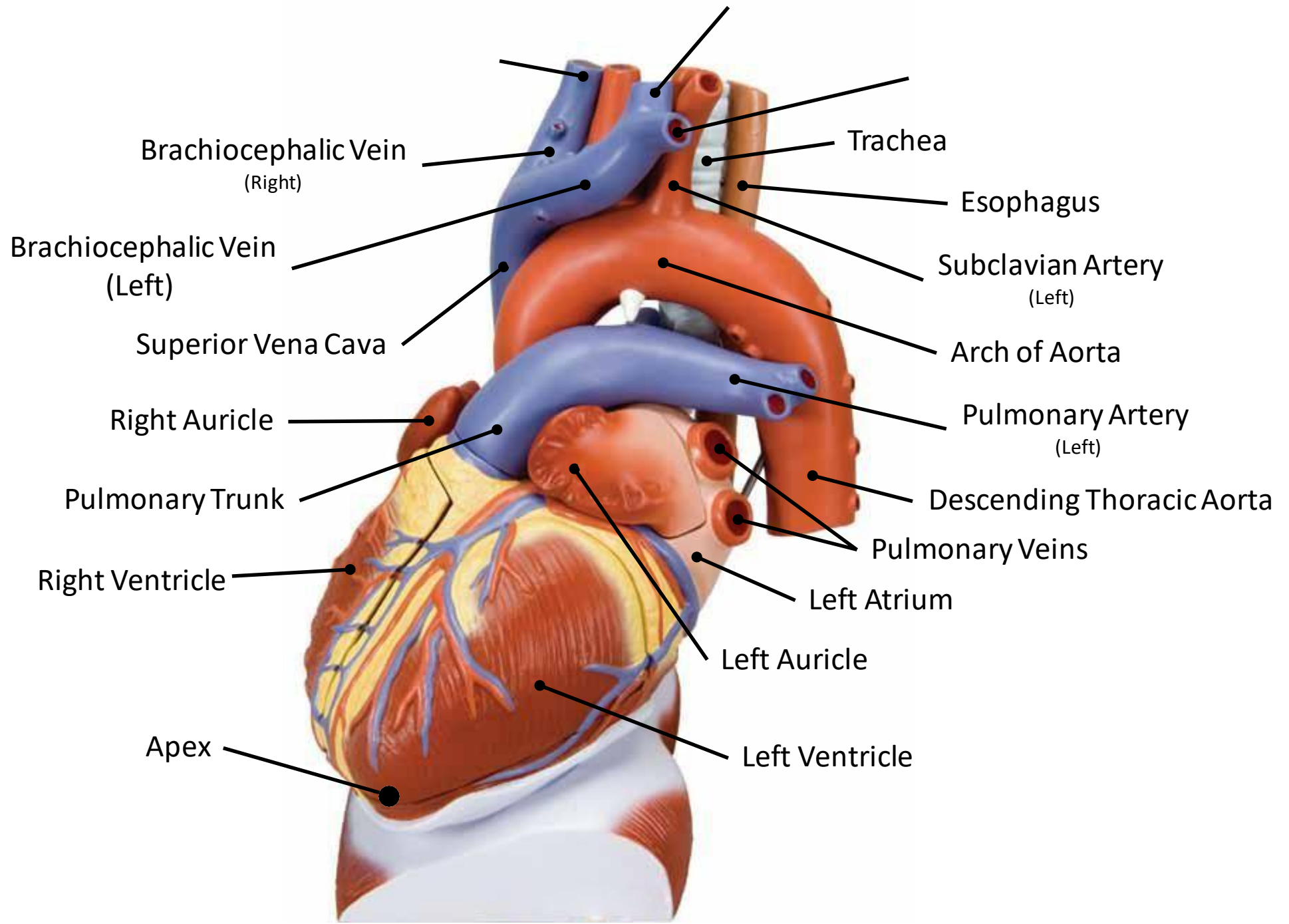


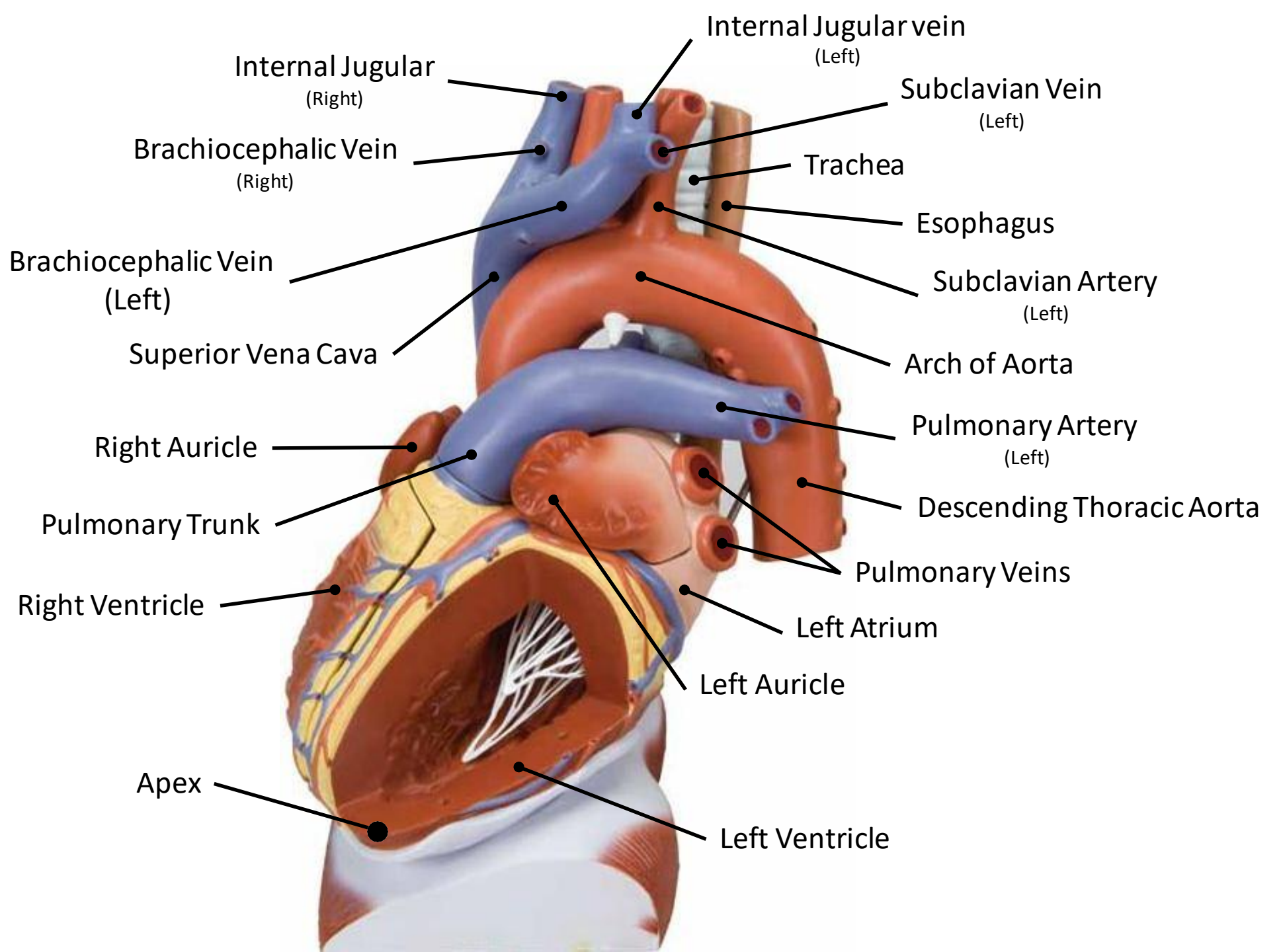
**Posterior  
View**

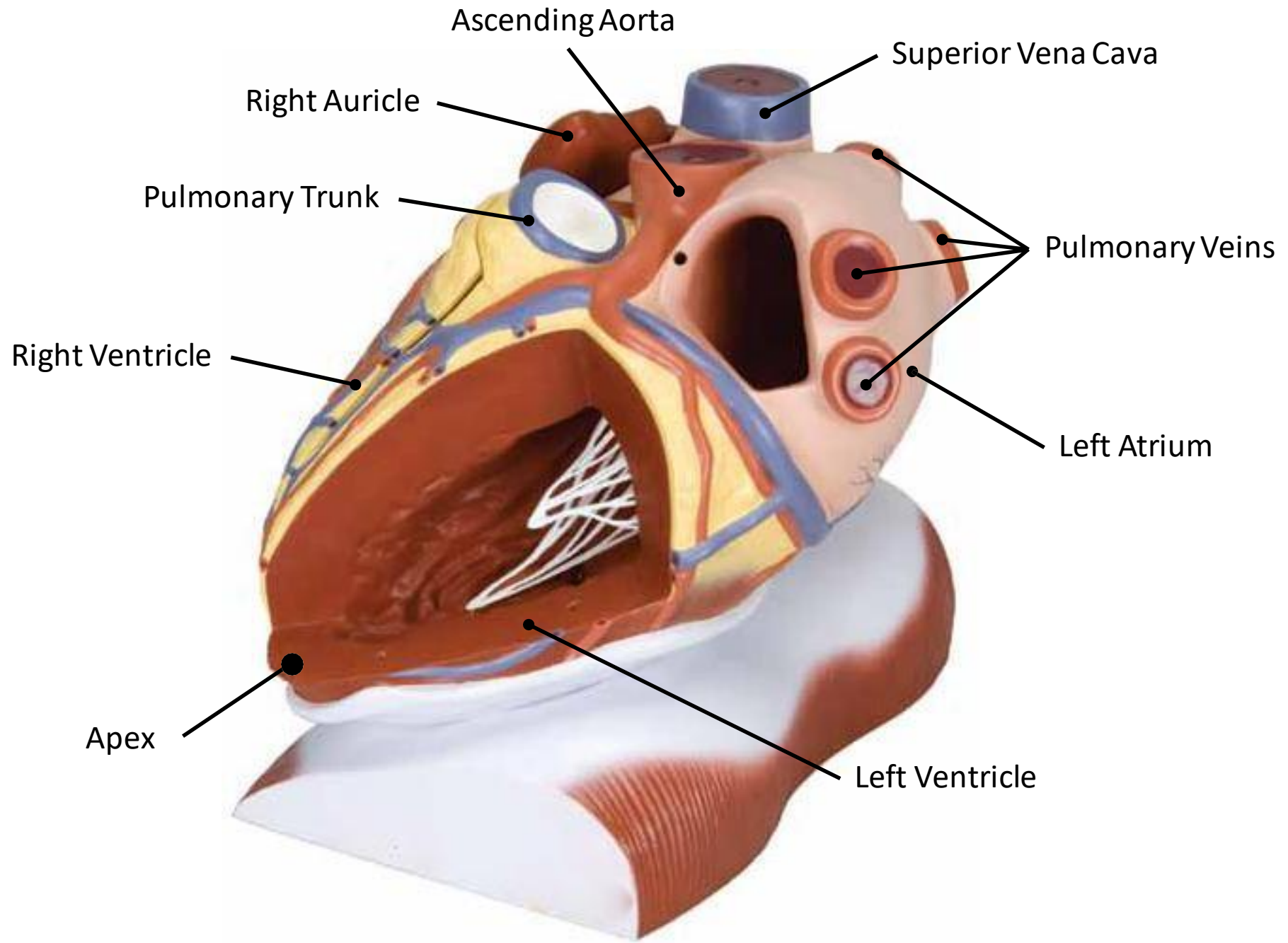




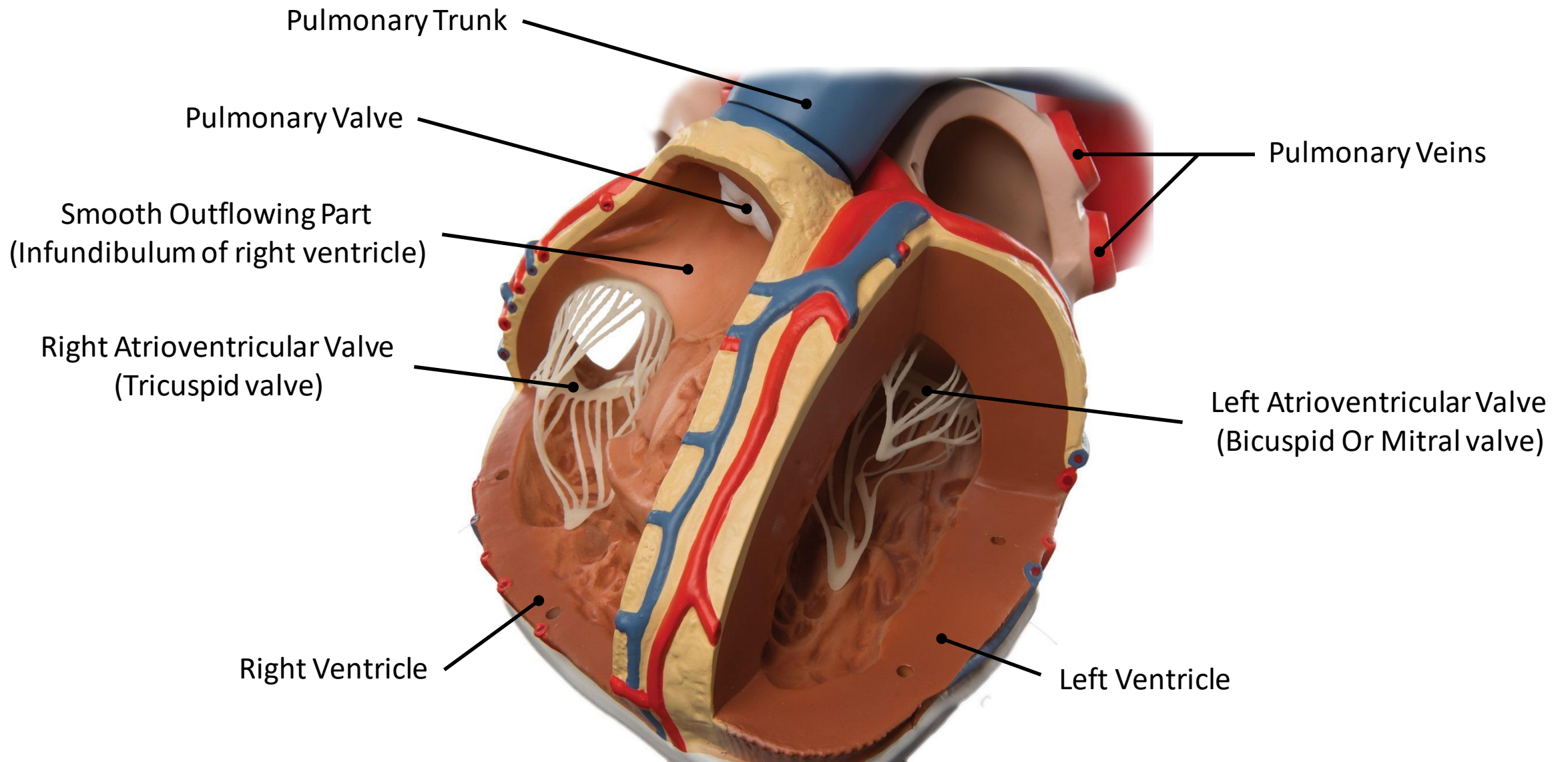




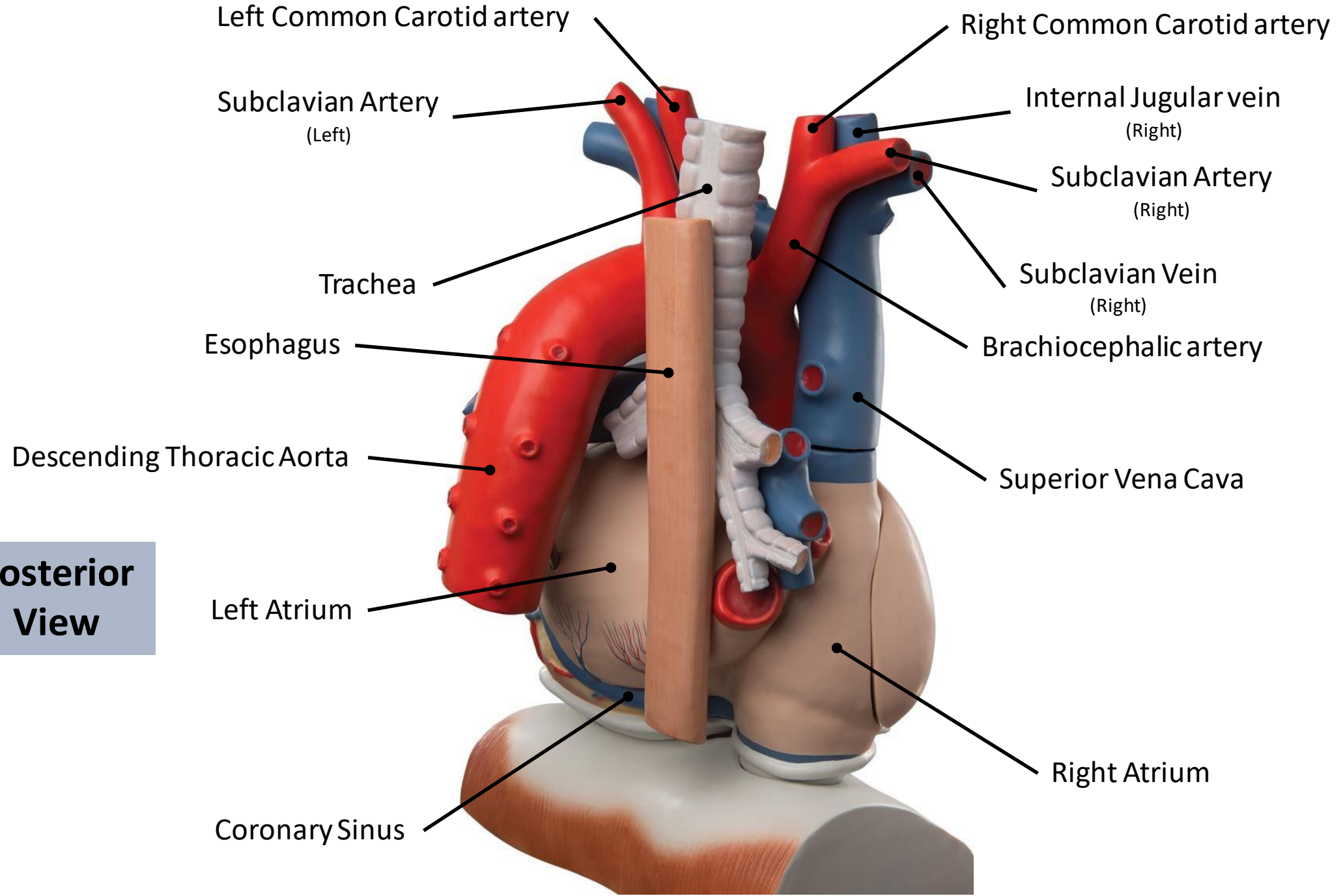




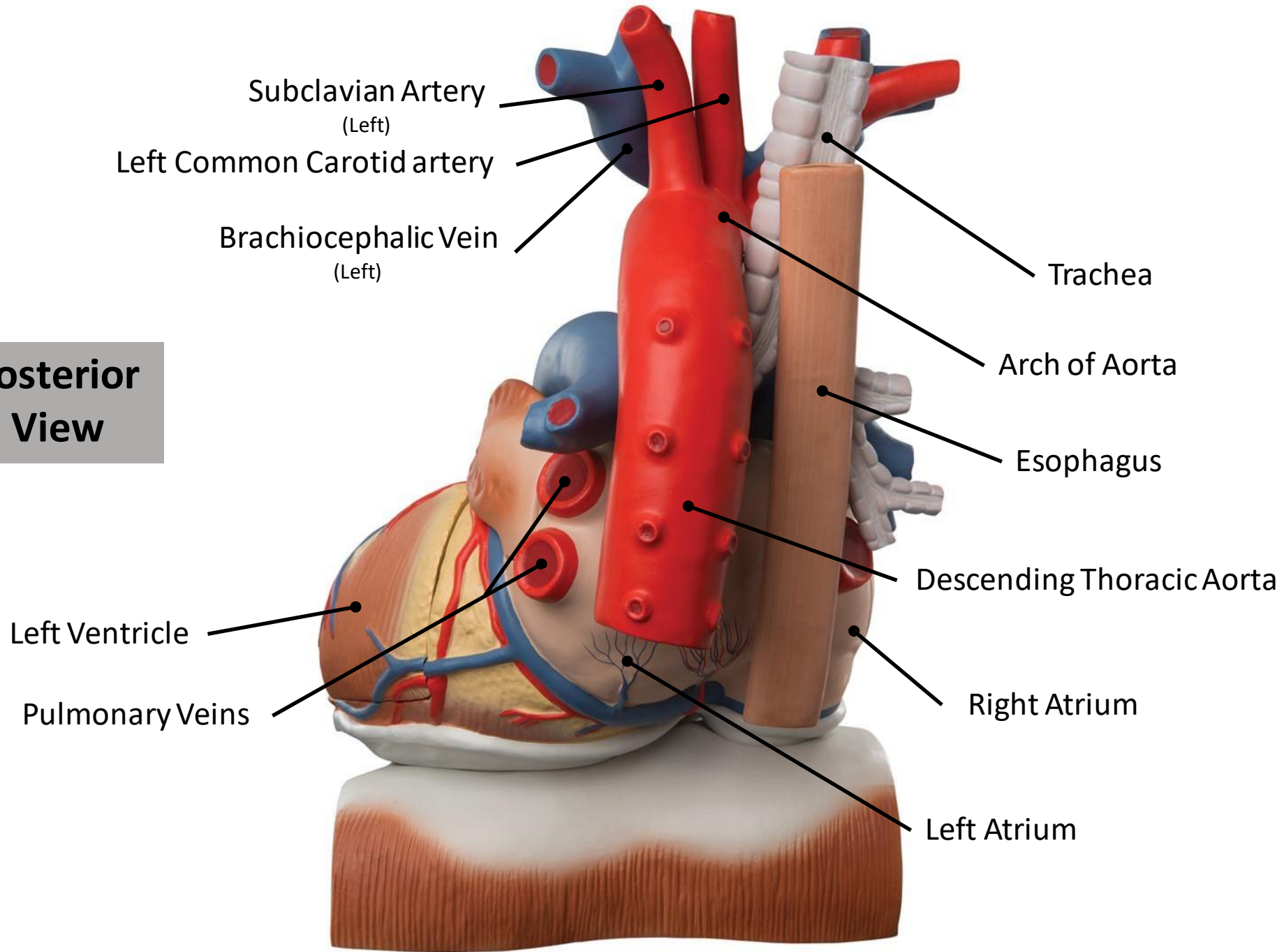


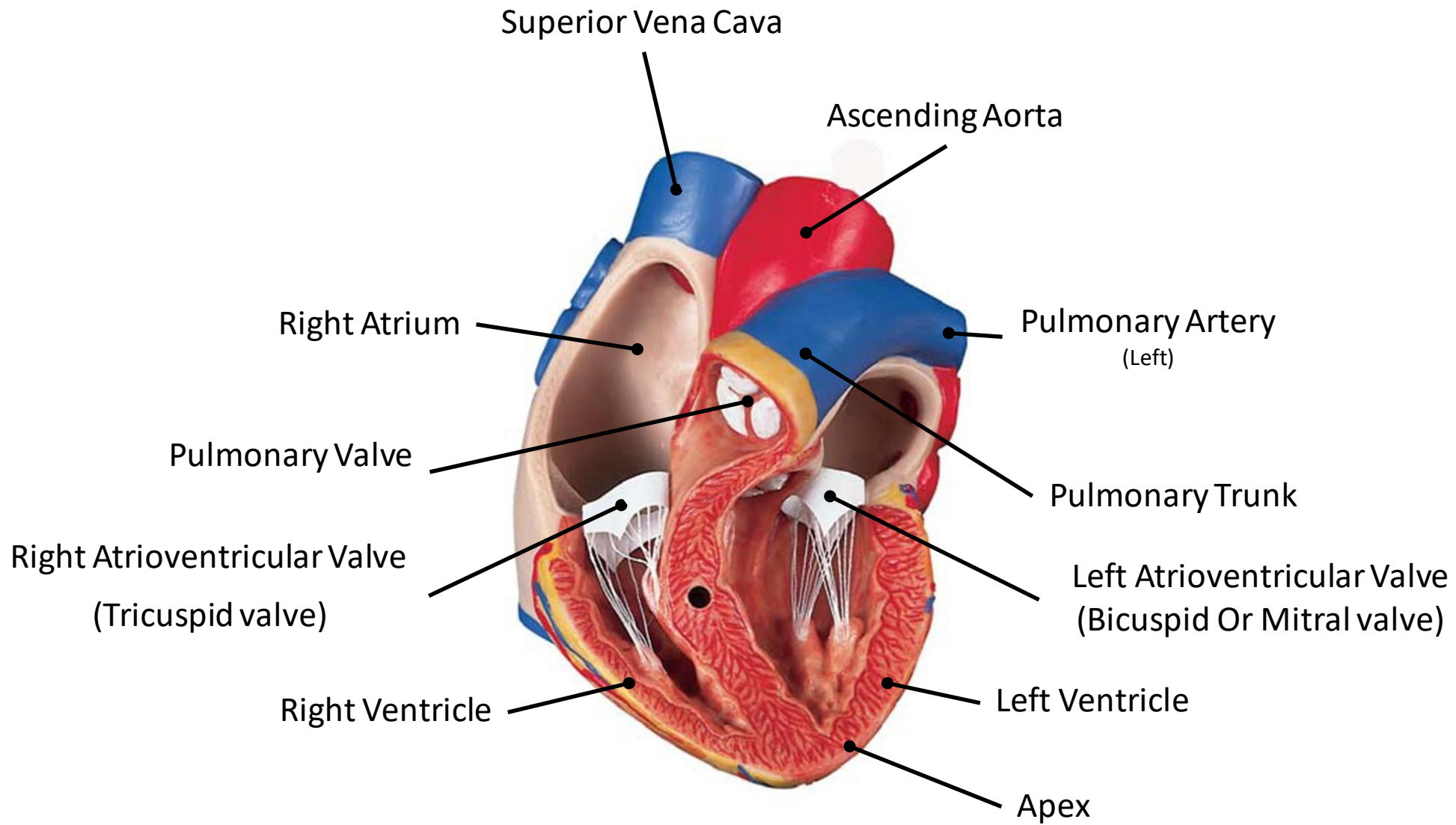


**Posterior  
View**

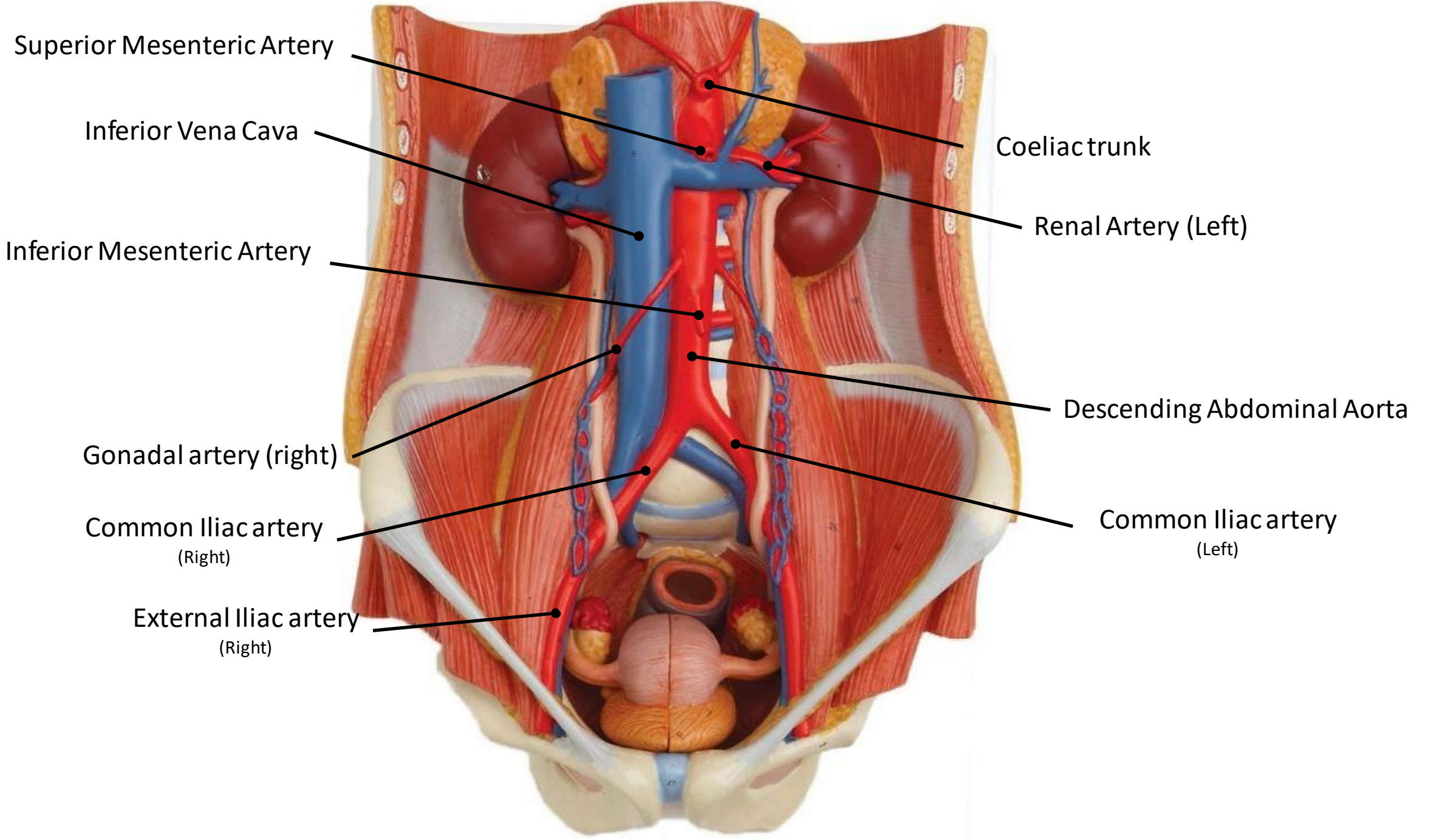


**Posterior  
View**









Superior Mesenteric Artery

Inferior Vena Cava

Inferior Mesenteric Artery

Gonadal artery (right)

Common Iliac artery  
(Right)

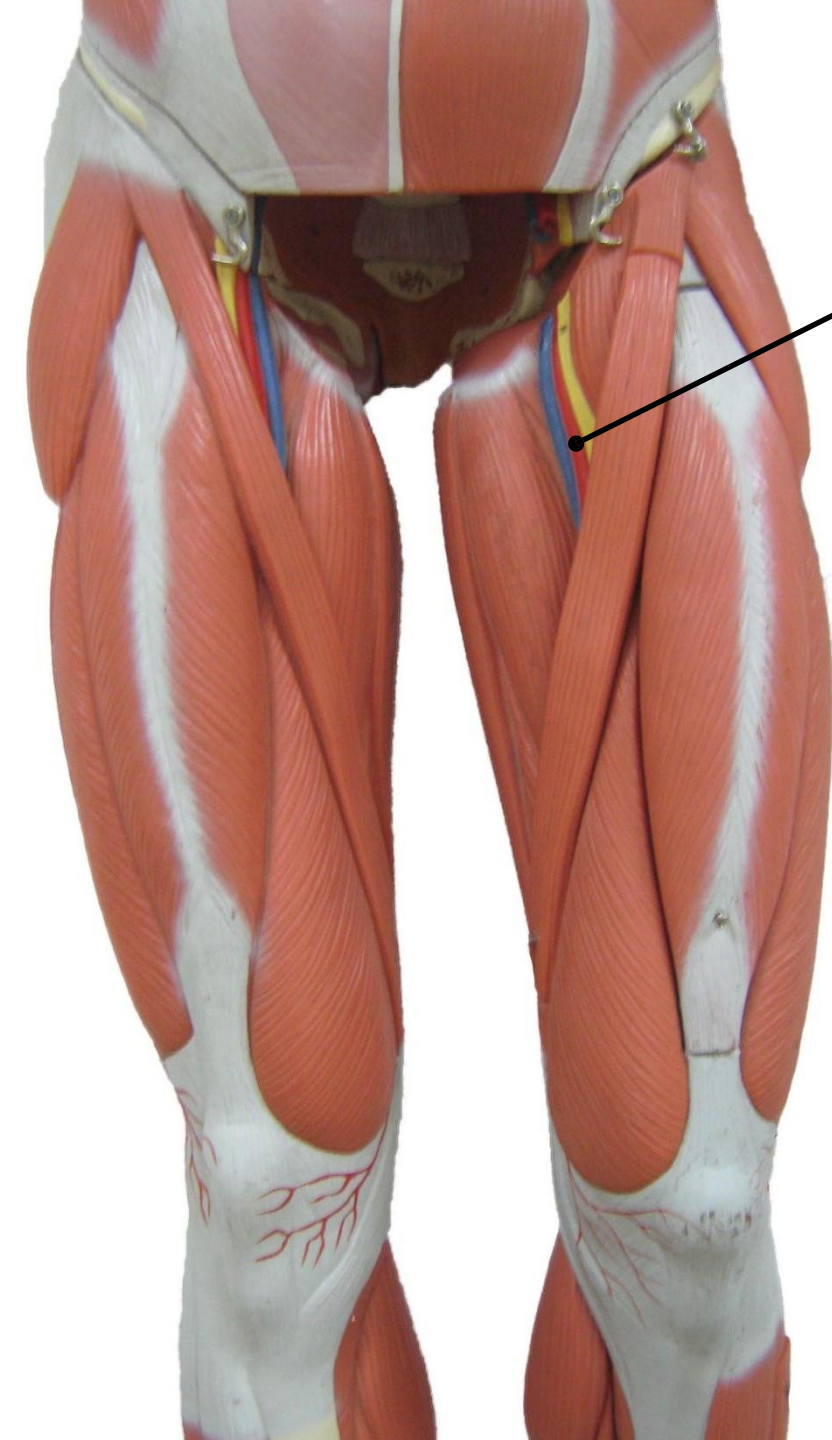
External Iliac artery  
(Right)

Coeliac trunk

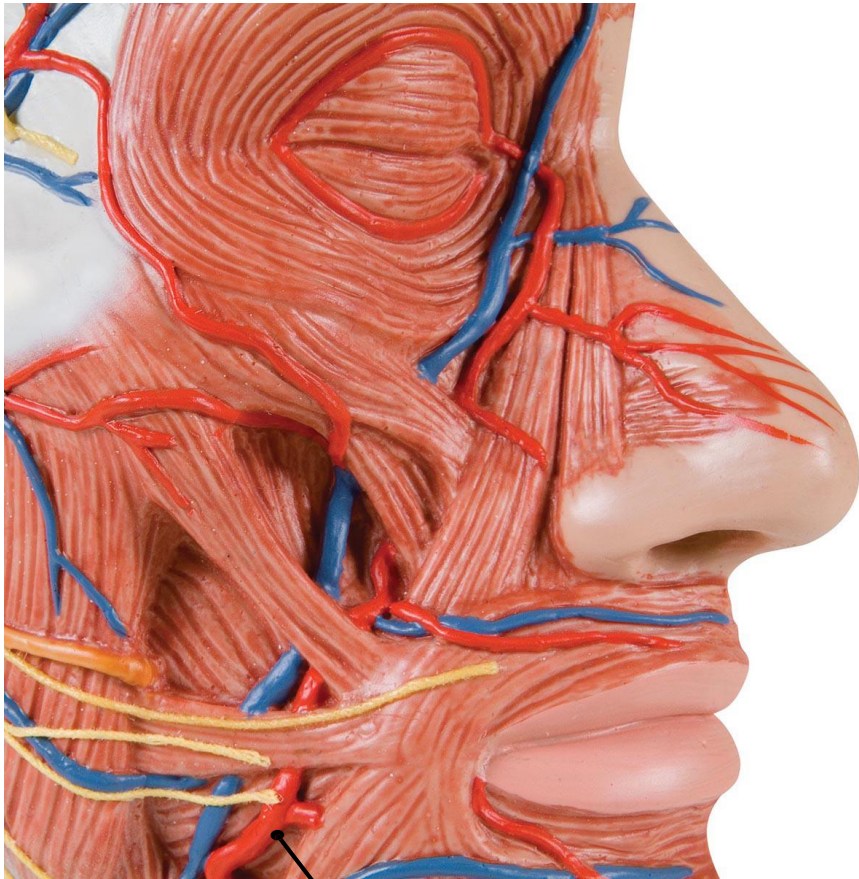
Renal Artery (Left)

Descending Abdominal Aorta

Common Iliac artery  
(Left)



Femoral Artery



Facial Artery