

Anatomy lab 3

Bones of upper limb

LATERAL

MEDIAL

POSTERIOR

ANTERIOR



(a) Superior view

Acromial end

Sternal end

ANTERIOR

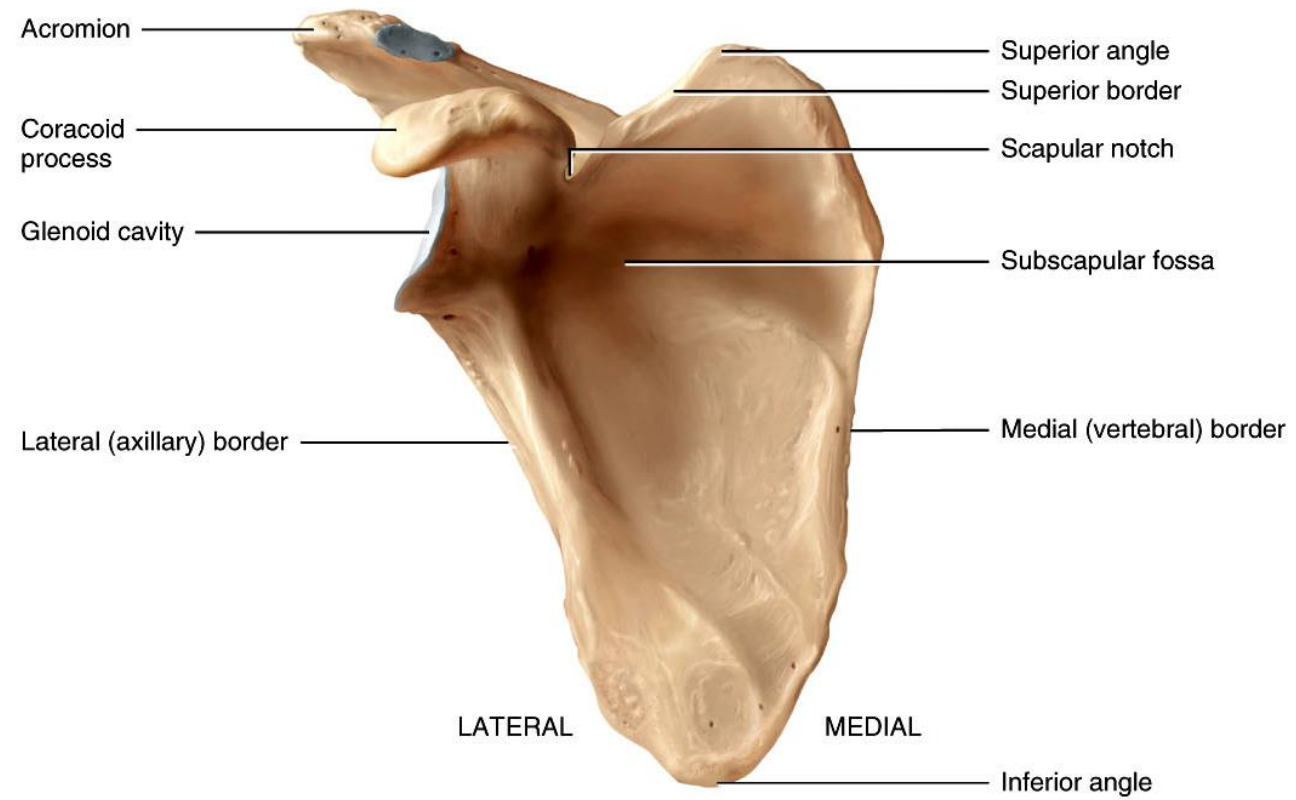
POSTERIOR



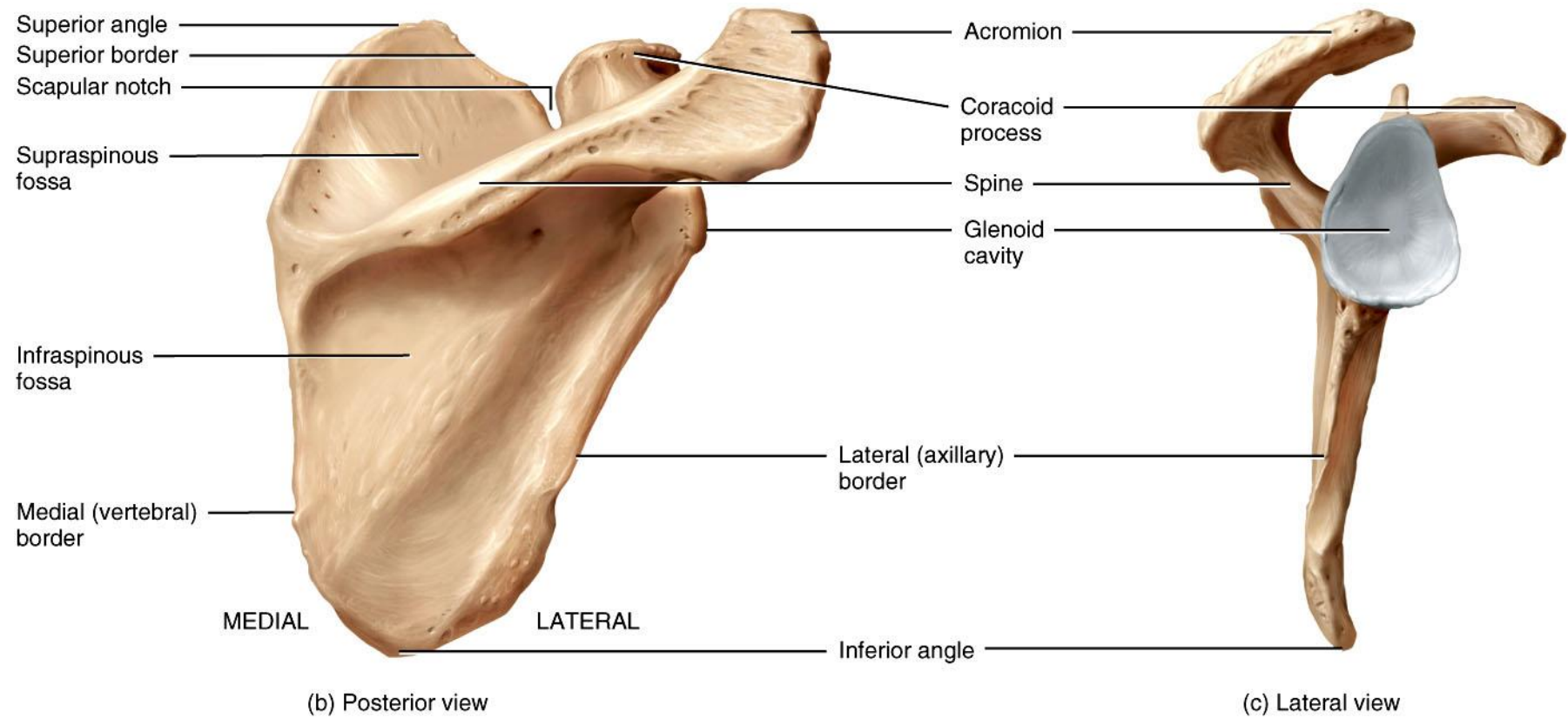
(b) Inferior view

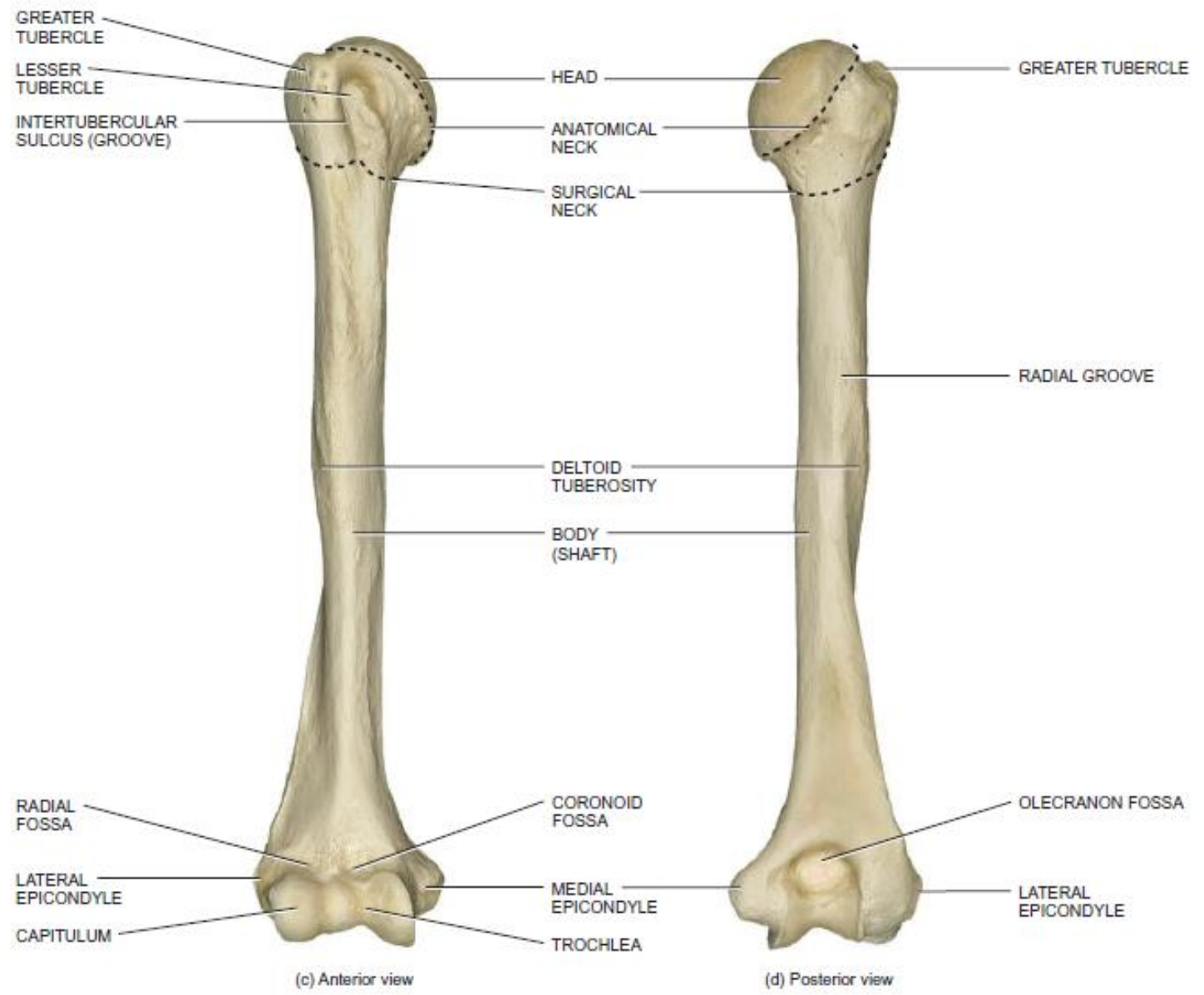
Conoid tubercle

Impression for the costoclavicular ligament



(a) Anterior view





GREATER TUBERCLE
LESSER TUBERCLE
INTERTUBERCULAR SULCUS (GROOVE)

HEAD
ANATOMICAL NECK
SURGICAL NECK

GREATER TUBERCLE

RADIAL GROOVE

DELTOID TUBEROSITY
BODY (SHAFT)

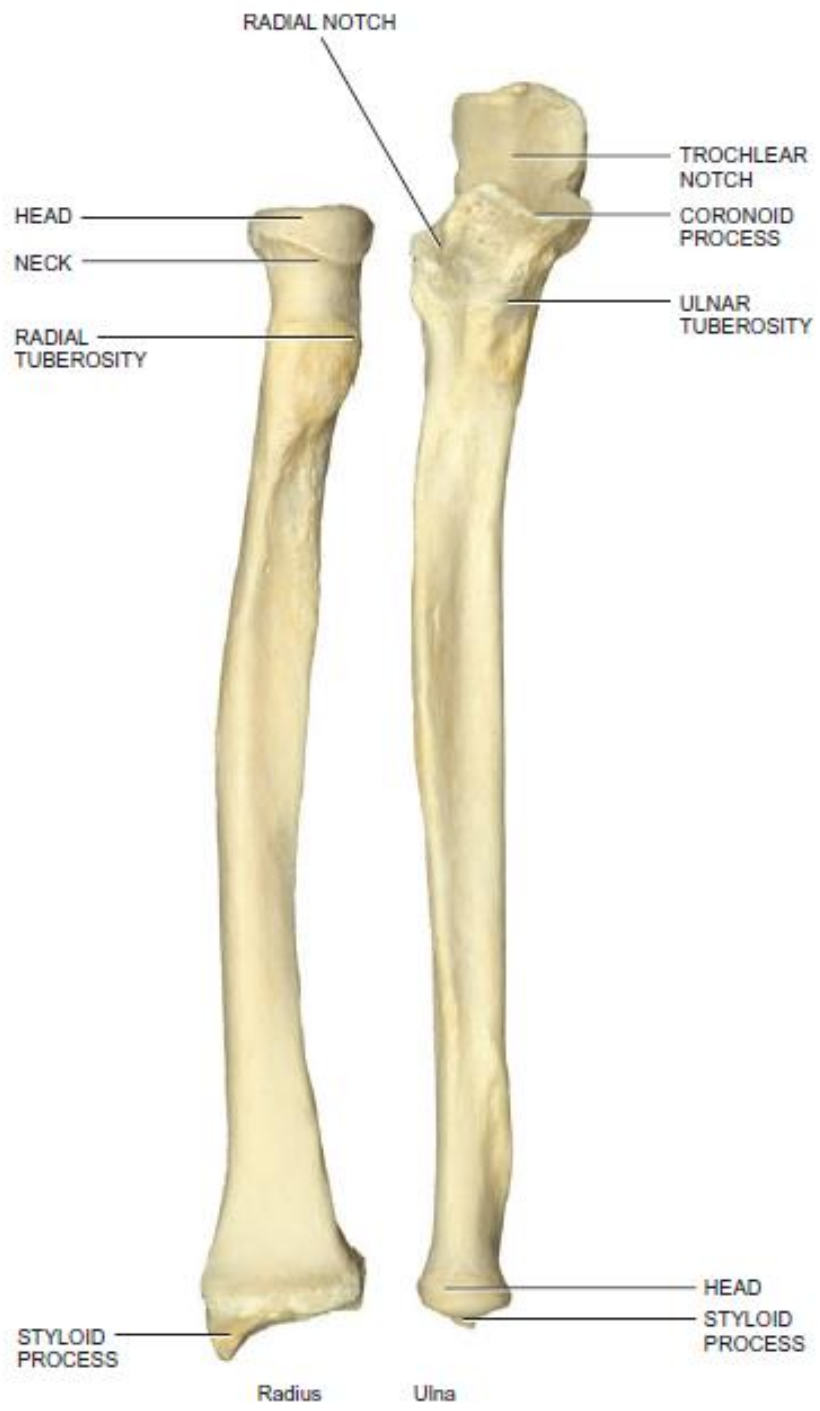
RADIAL FOSSA
LATERAL EPICONDYLE
CAPITULUM

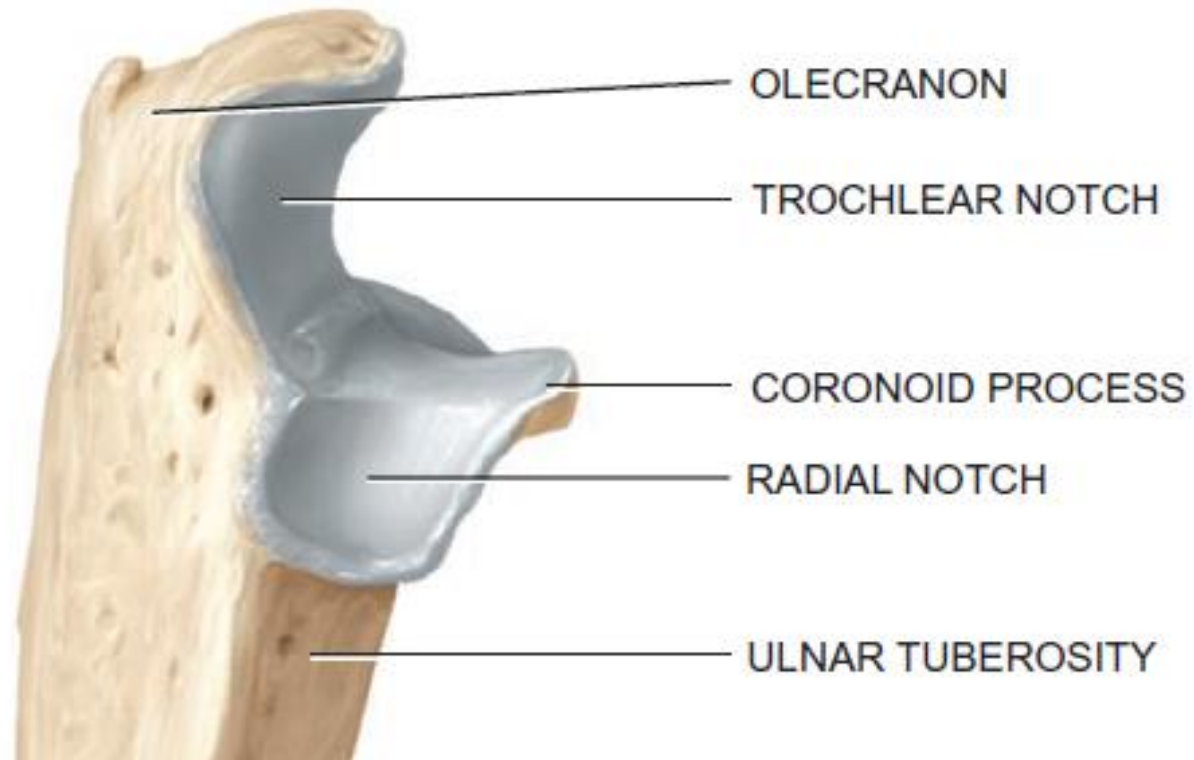
CORONOID FOSSA
MEDIAL EPICONDYLE
TROCHLEA

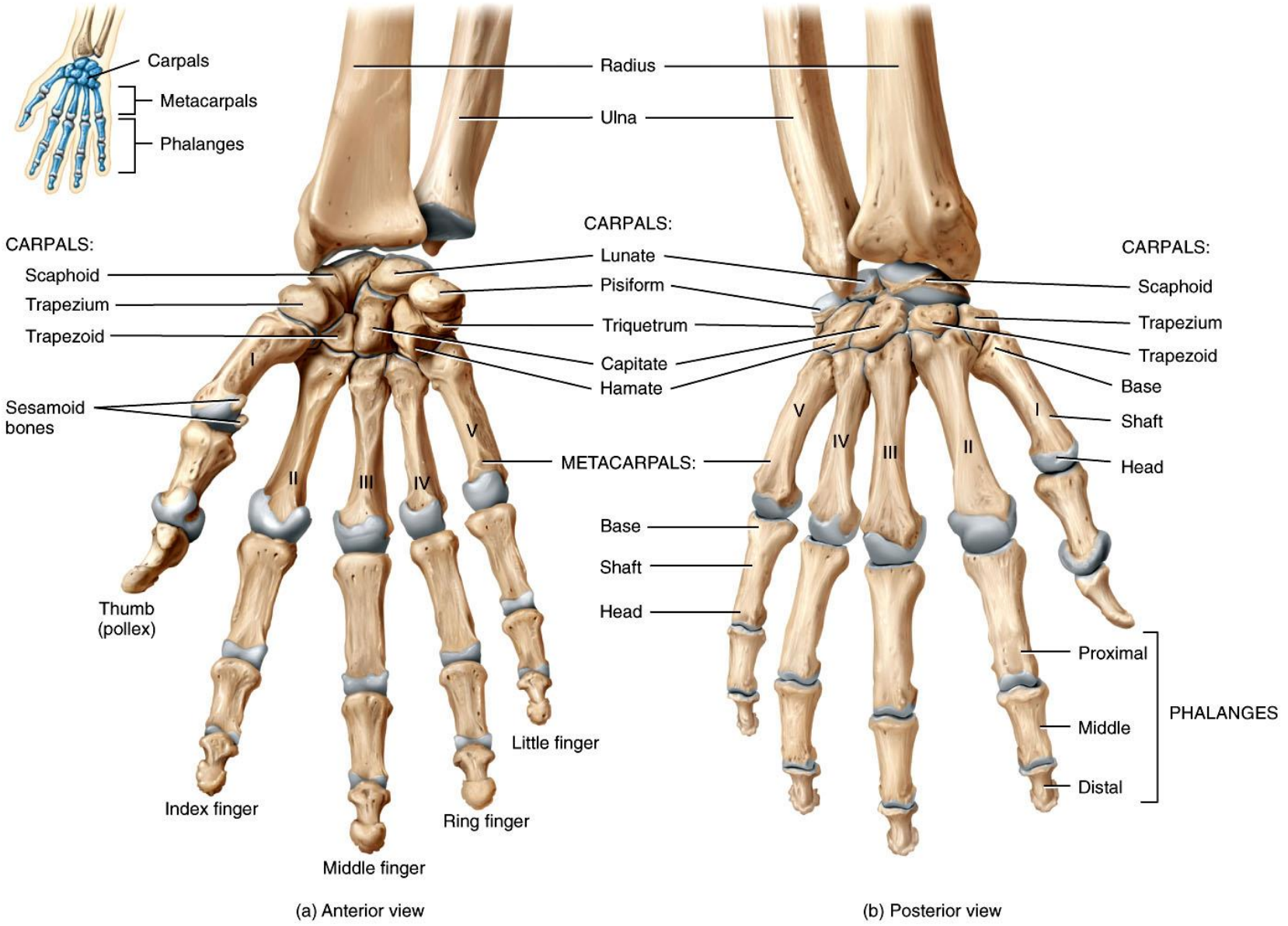
OLECRANON FOSSA
LATERAL EPICONDYLE

(c) Anterior view

(d) Posterior view







(a) Anterior view

(b) Posterior view



