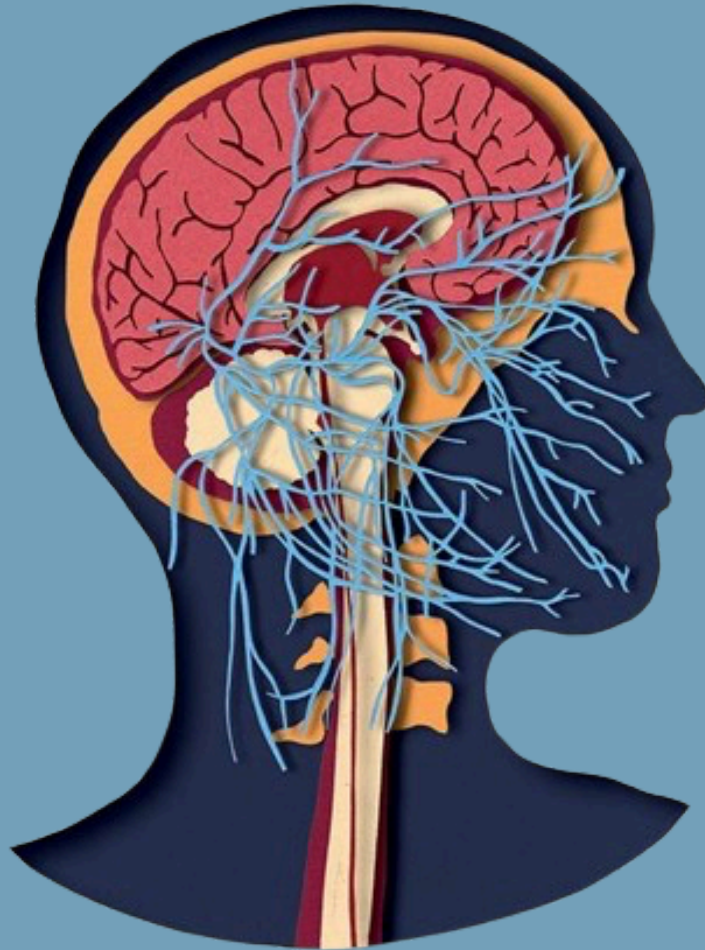

وَقُلْ رَبِّ زِدْنِي عِلْمًا



# PERIPHERAL NERVOUS SYSTEM



SUBJECT : Anatomy

LEC NO. : Lab 2

DONE BY : Batool Alzubaidi

#كَلِينِيكَال\_إِلَا\_شَحْطَة

# PNS

## Practical (2)

الدكتورة حكت كثير و شرحت لانه اللاب انشرح قبل ما ناخذ محاضرات النظري ف عشان تفهمنا و تسهل على حالها شرح النظري بس حكت ما راح تسال على اشى مش متشاور عليه بالصور

Sternomastoid is cut

1- Trunks of the brachial

plexus.

Upper, middle, lower » posterior triangle of the neck

2- Supraclavicular nerves.

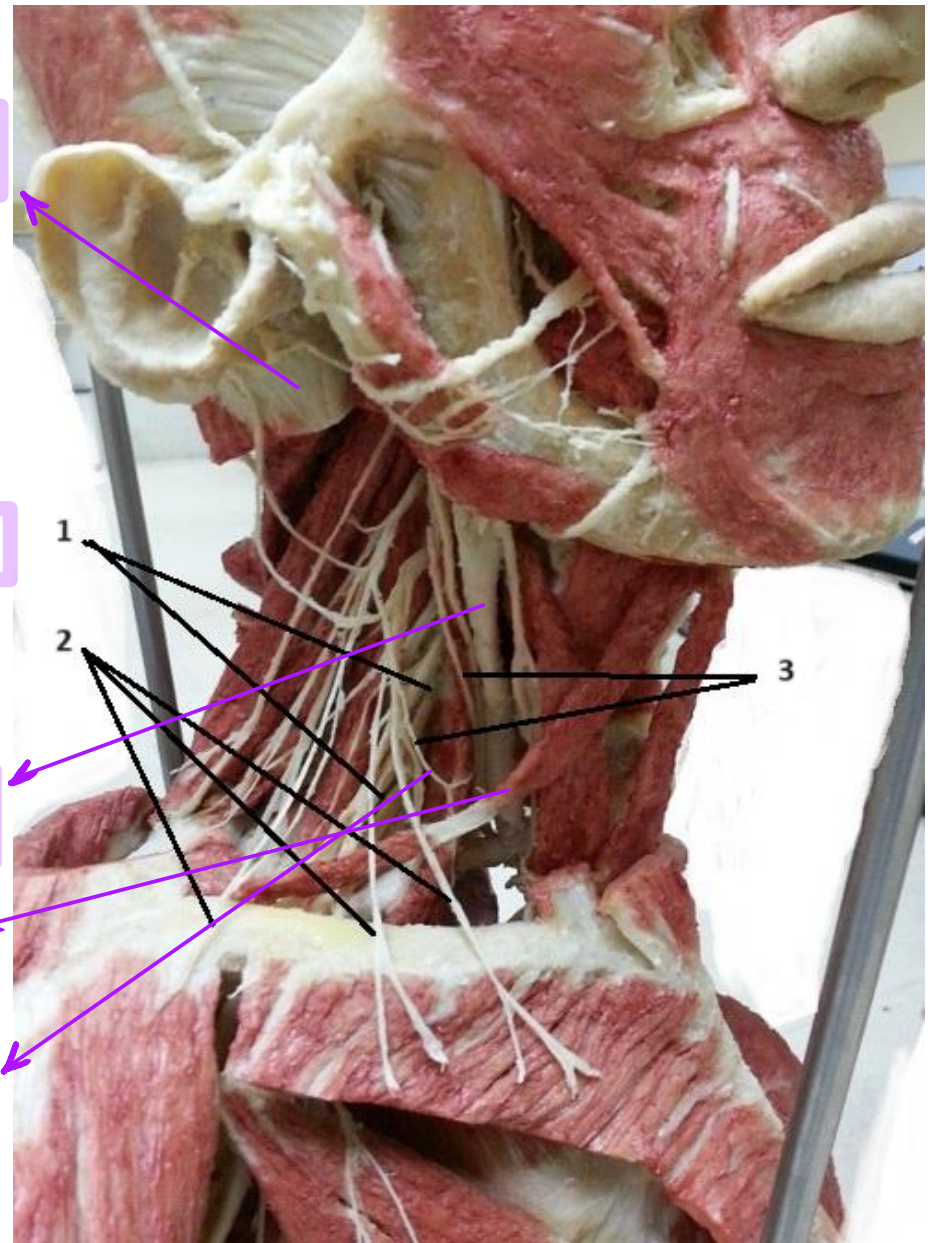
Cutaneous branches of brachial plexus » cross clavicle

3- Roots of ansa cervicalis

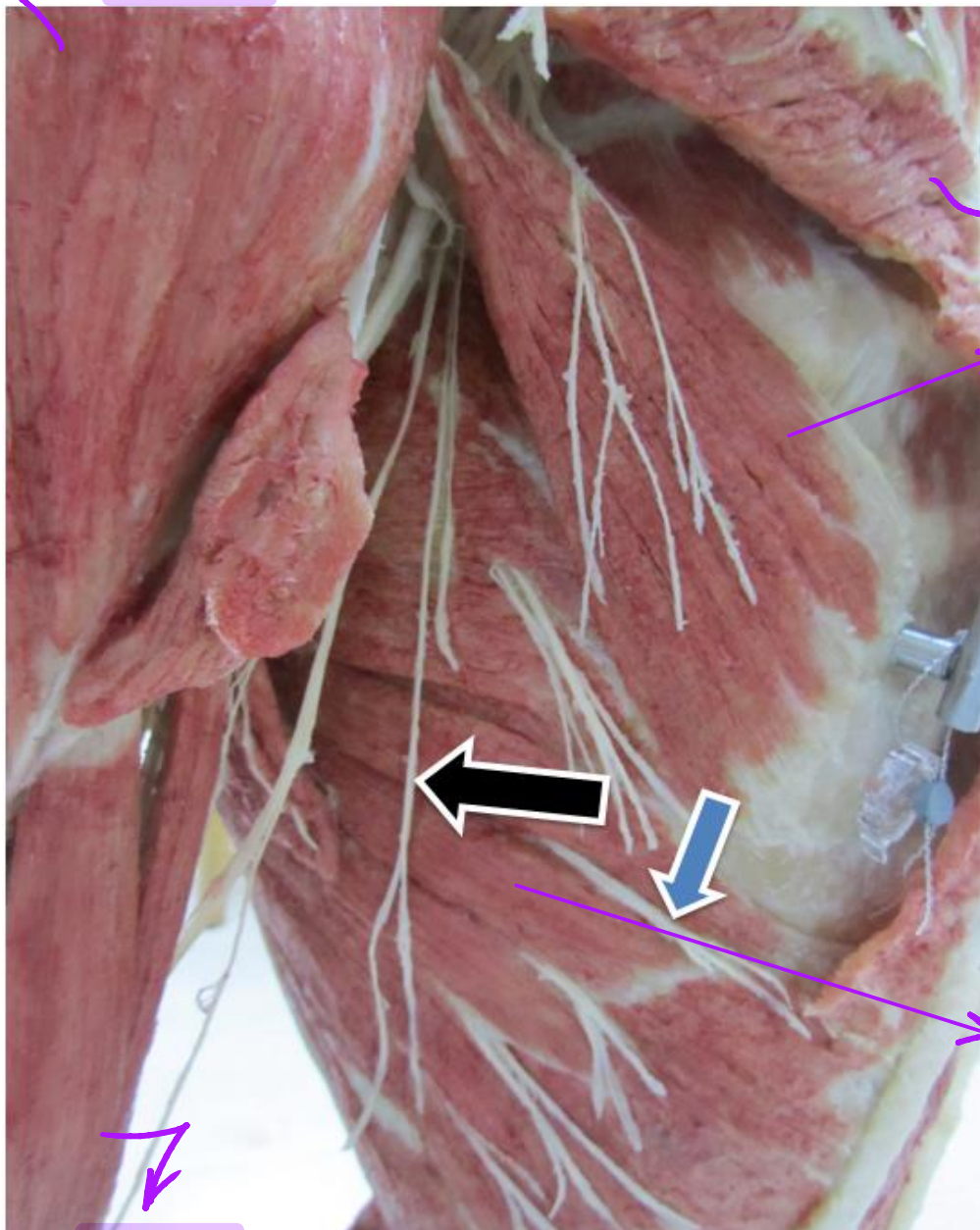
Common carotid artery

Omohyoid muscle

Ansa cervicalis



Deltoid



Pectoralis major is cut

Pectoralis minor

Another name » nerve to serratus anterior

**Long thoracic nerve** (black color arrow).

**Intercostal nerve** (blue color area).

Serratus anterior

Biceps

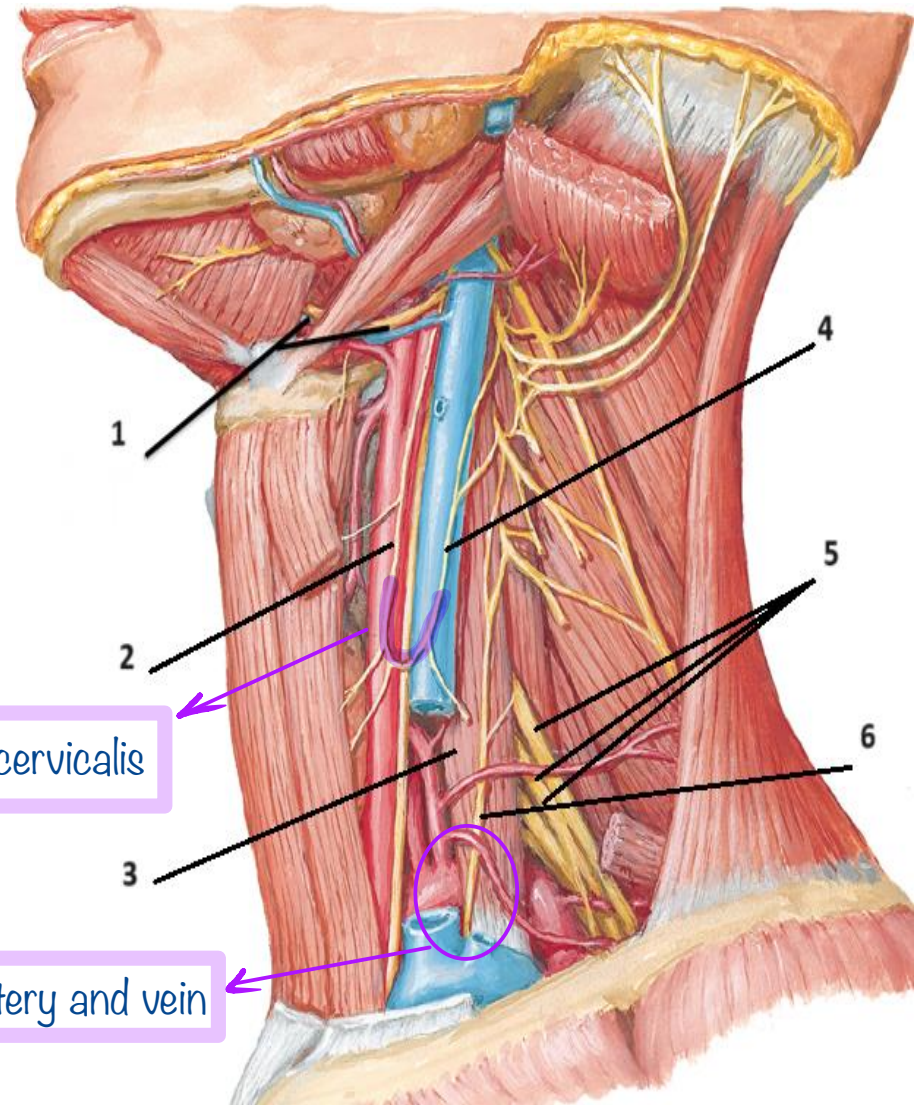


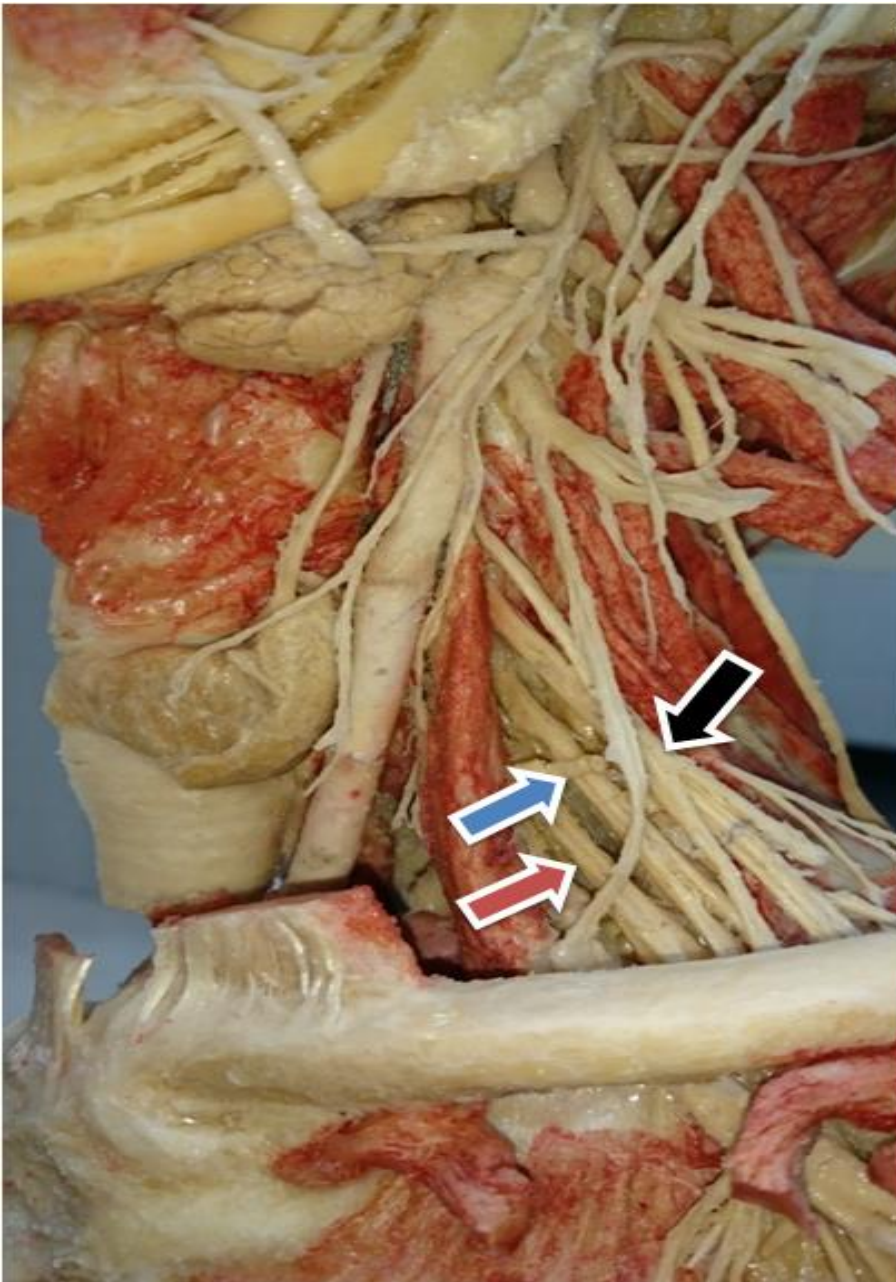
- 1- Hypoglossal nerve.
- 2- Superior root of ansa cervicalis.
- 3- Scalenus anterior.
- 4- Inferior root of ansa cervicalis.
- 5- Trunks of brachial plexus.
- 6- Phrenic nerve. ↗

Descends anterior to scalenus anterior

Loop of Ansa cervicalis

Phrenic nerve descends between subclavian artery and vein





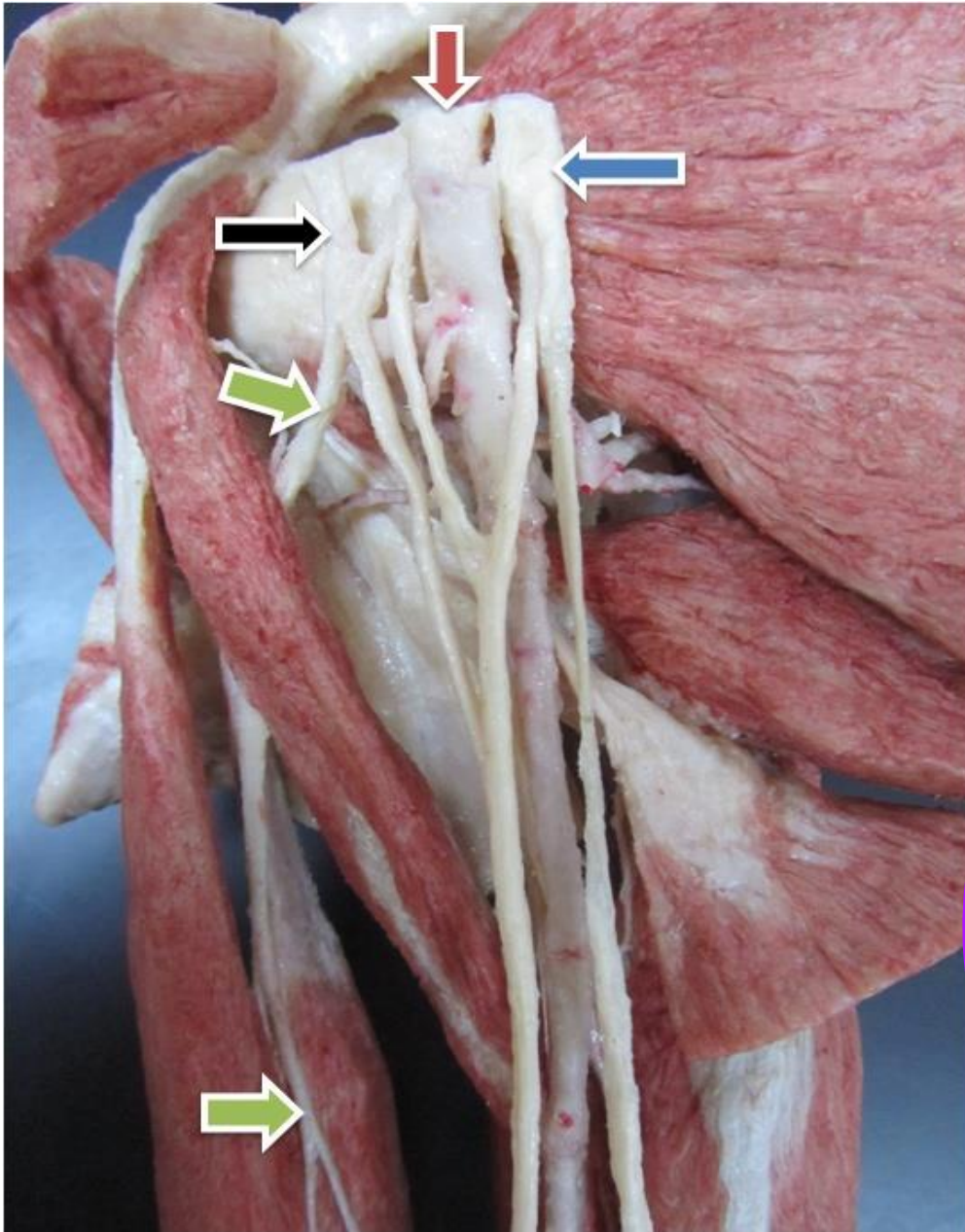
In the posterior triangle of the neck:

**Upper trunk of brachial plexus** (black color arrow).

**Middle trunk of brachial plexus** (blue color arrow).

**Lower trunk of brachial plexus** (red color arrow),





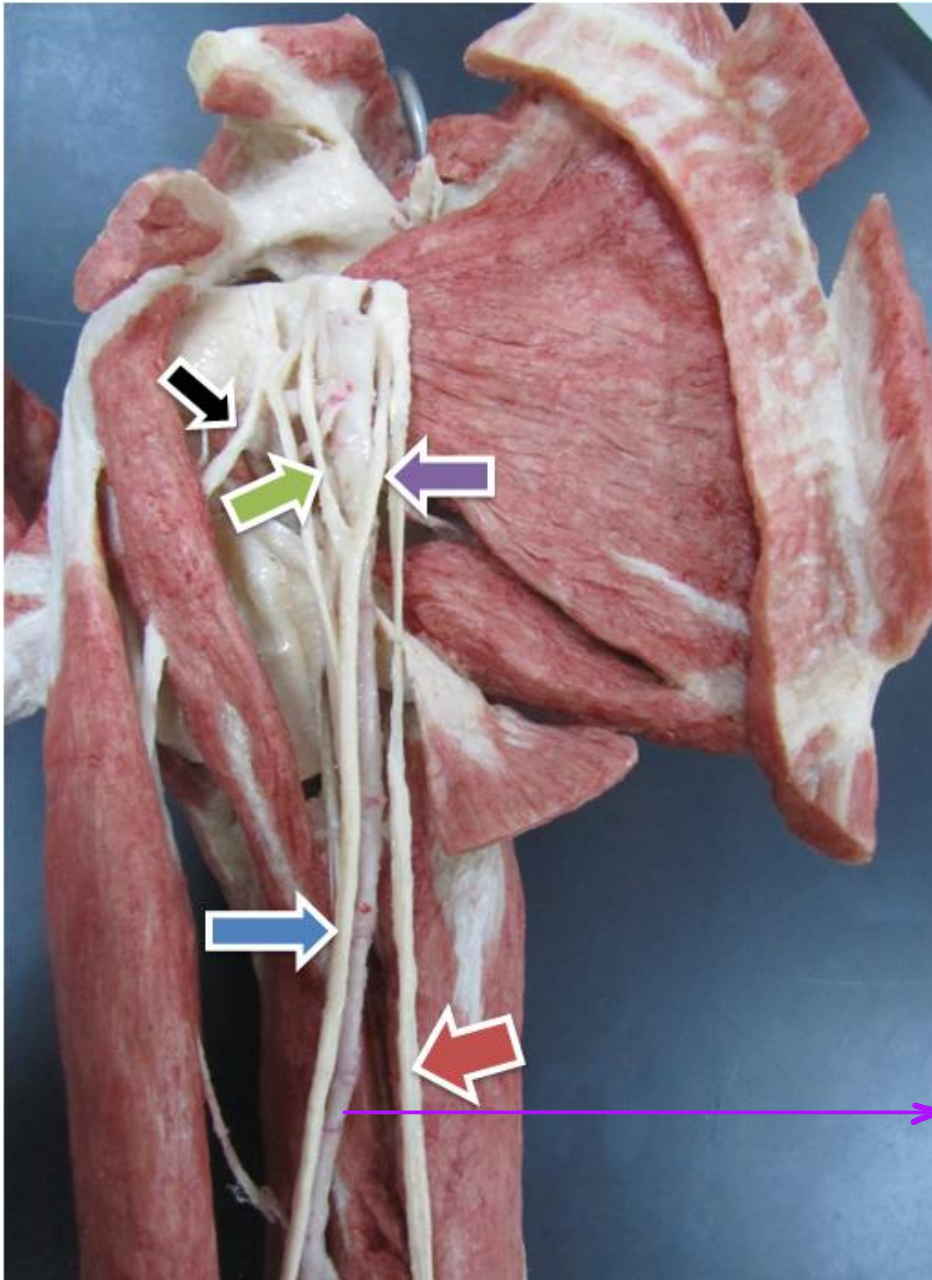
**Lateral cord of brachial plexus**  
(black color arrow).

**Medial cord** (blue color arrow).

**Axillary artery** (red color  
arrow). Pierces coracobrachialis

**Musculo-cutaneous nerve**  
(green color arrows).

At the level of lower border of trees  
major it becomes brachial artery



**Musculocutaneous nerve** (black color arrow),

**Median nerve** (blue color arrow),

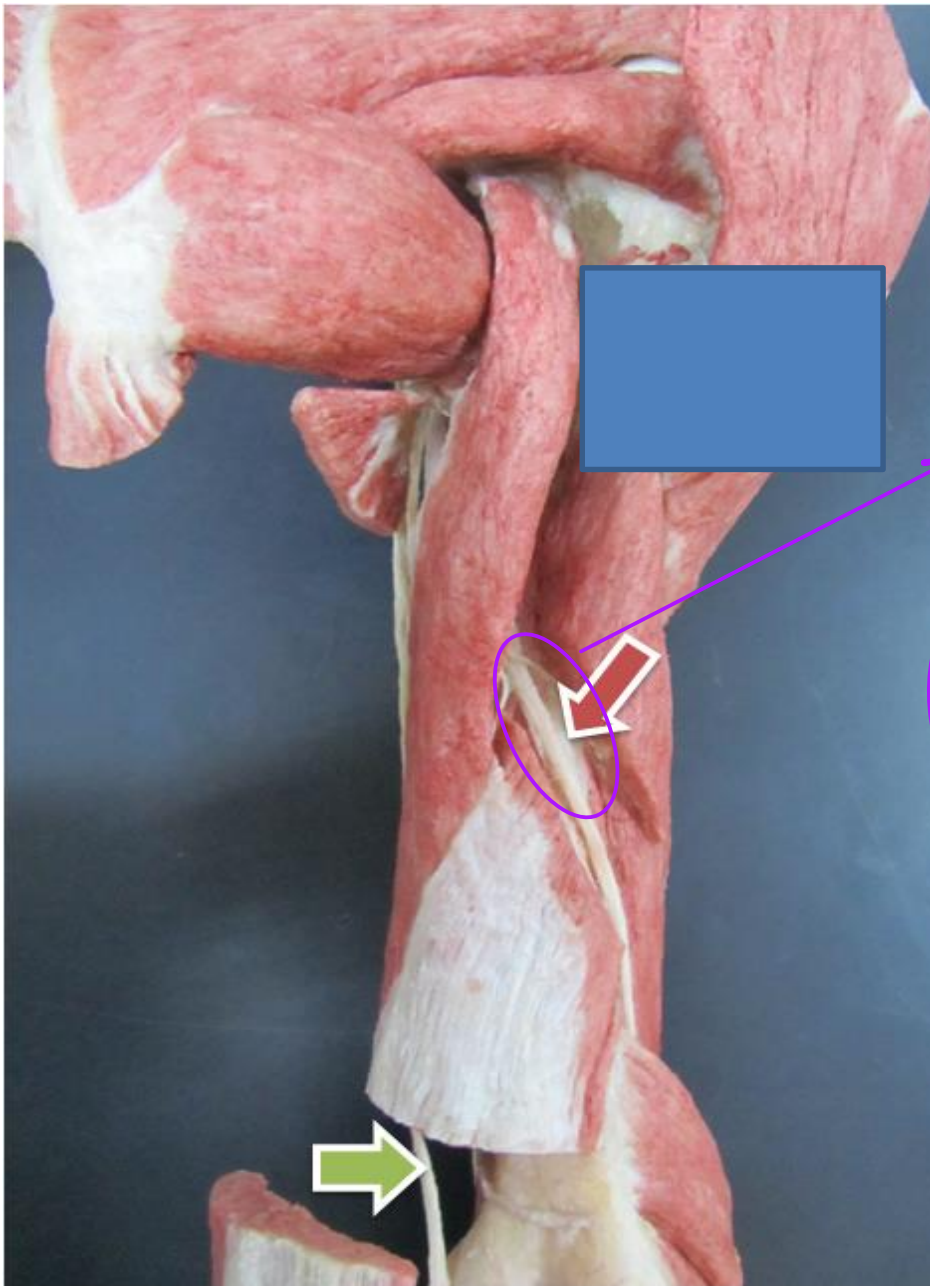
**Ulnar nerve** (red color arrow).

**Lateral root of median nerve** (green color arrow).

**Medial root of median nerve** (purple color arrow).

Brachial artery



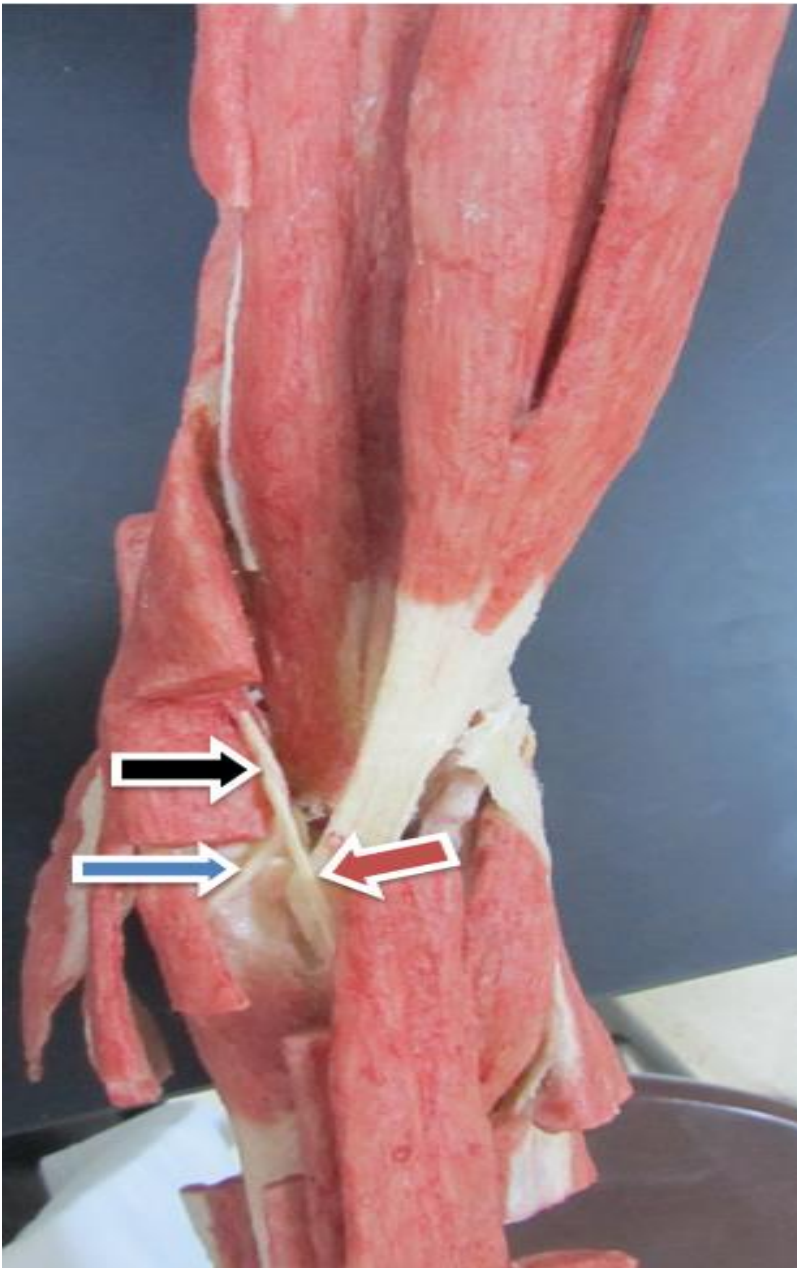


Spiral groove » radial nerve courses in it

**Radial nerve** (red color arrow).

**Ulnar nerve** (green color arrow),

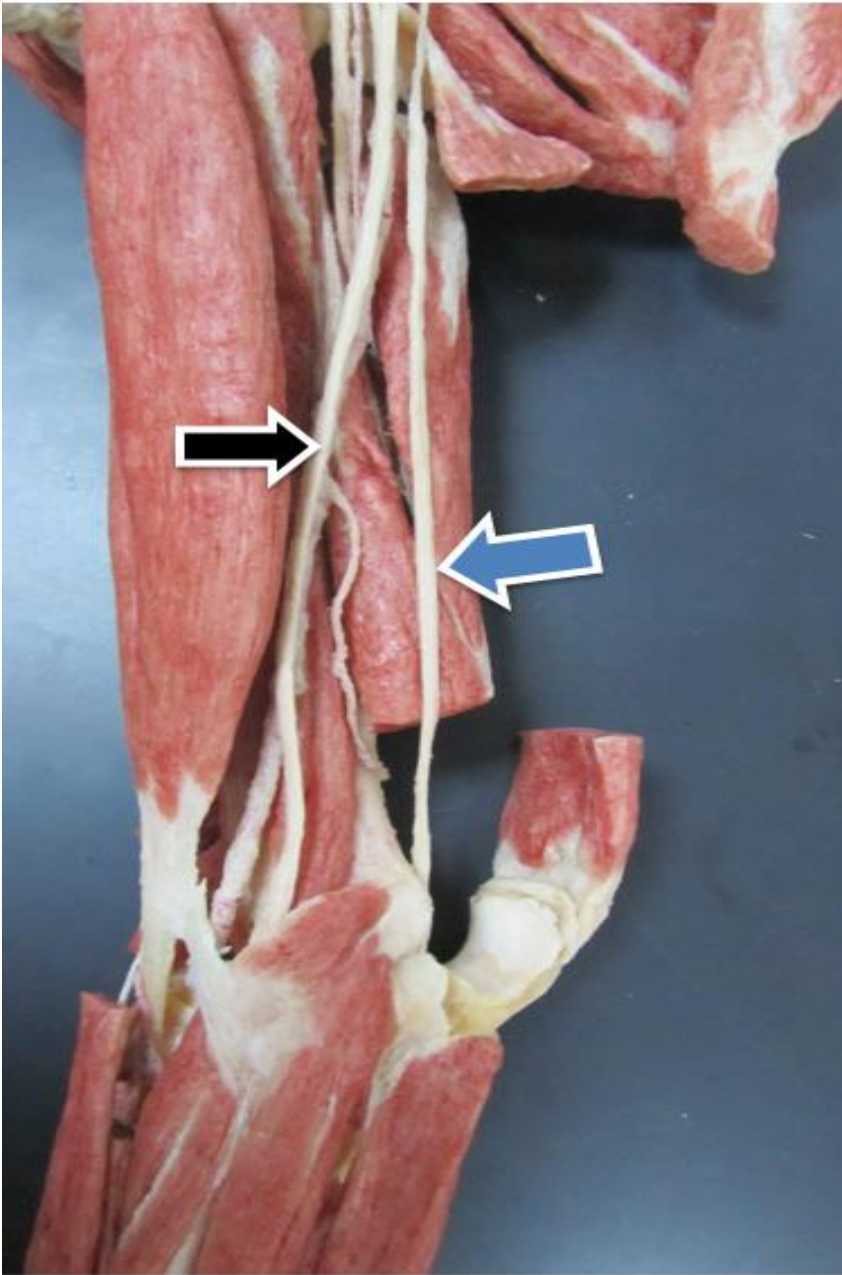
No distribution in arm only in forearm and hand



**Radial nerve (black color arrow).**

**Deep branch of radial nerve (blue color arrow).** Posterior interosseous nerve of radial

**Superficial branch of radial nerve (red color arrow),** Cutaneous branch



**Median nerve** (black color arrow).

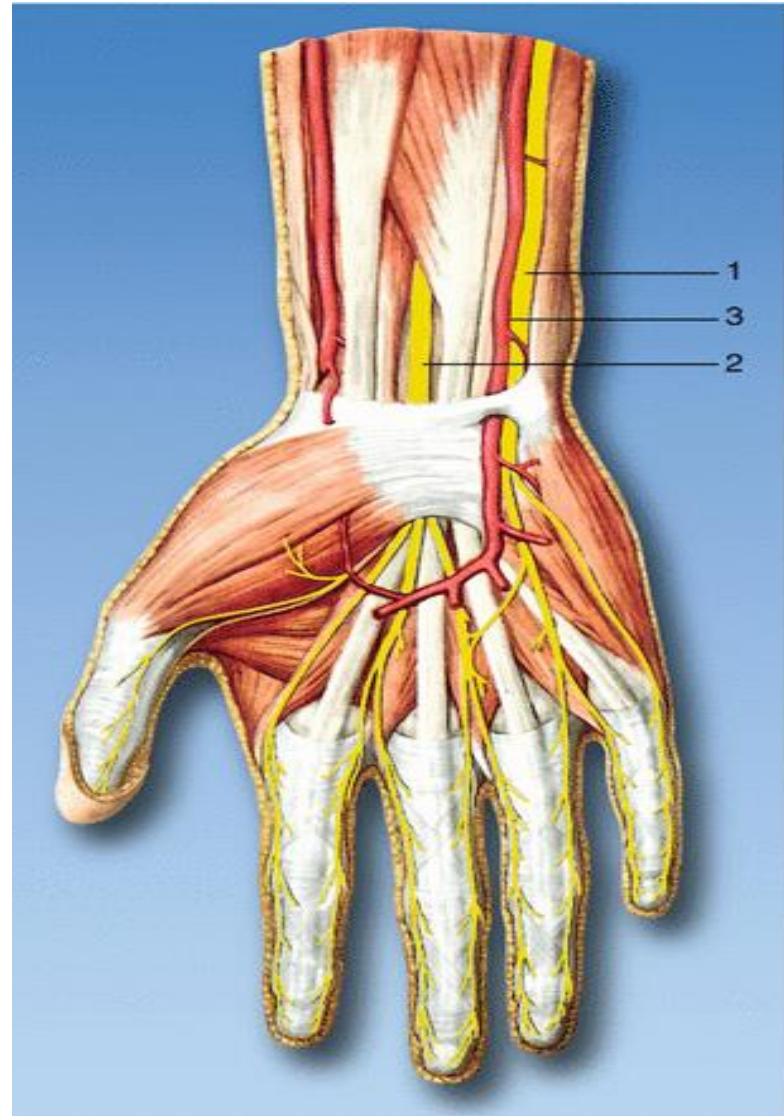
**Ulnar nerve** (blue color arrow).

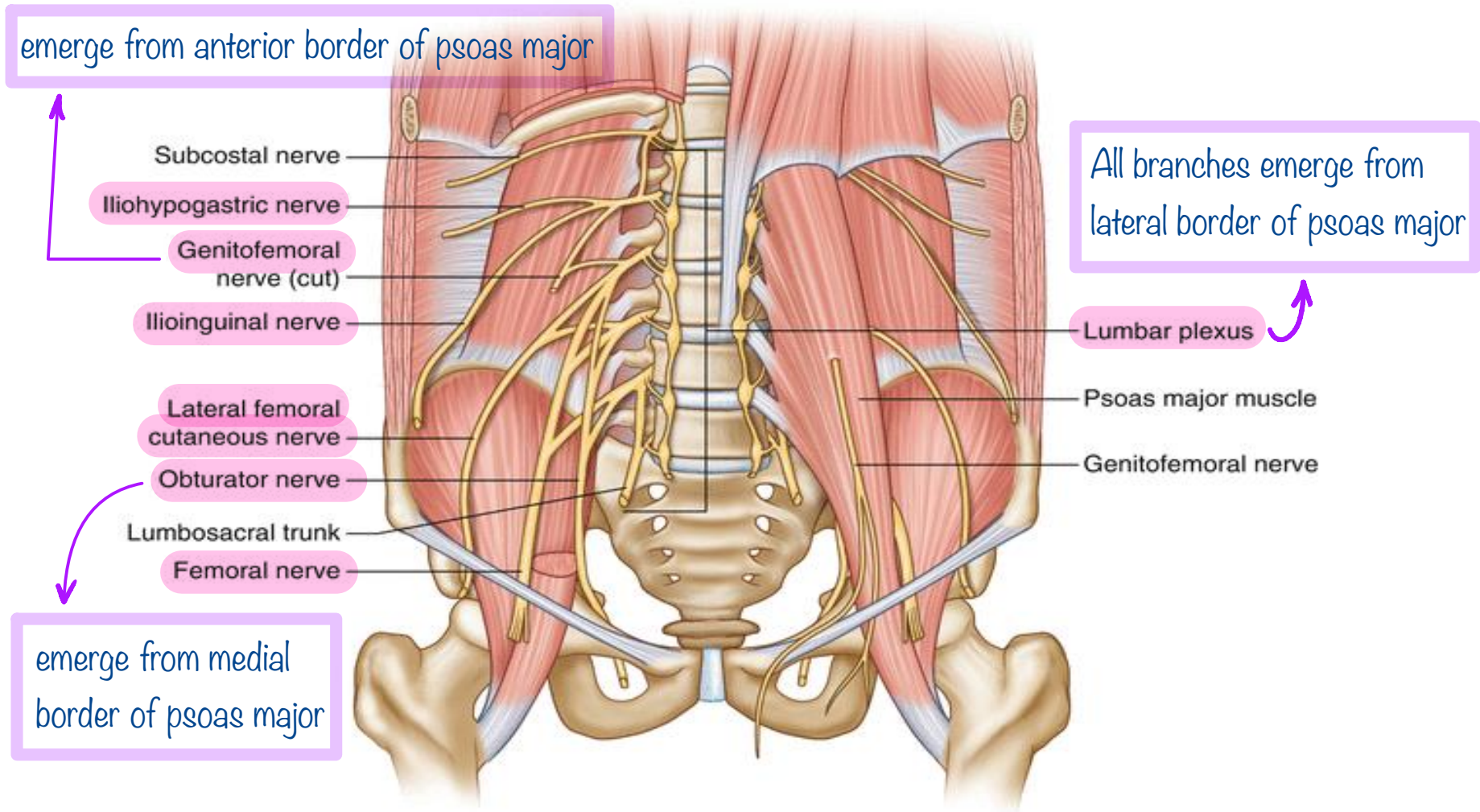


**1- Ulnar nerve.**

**2- Median nerve**

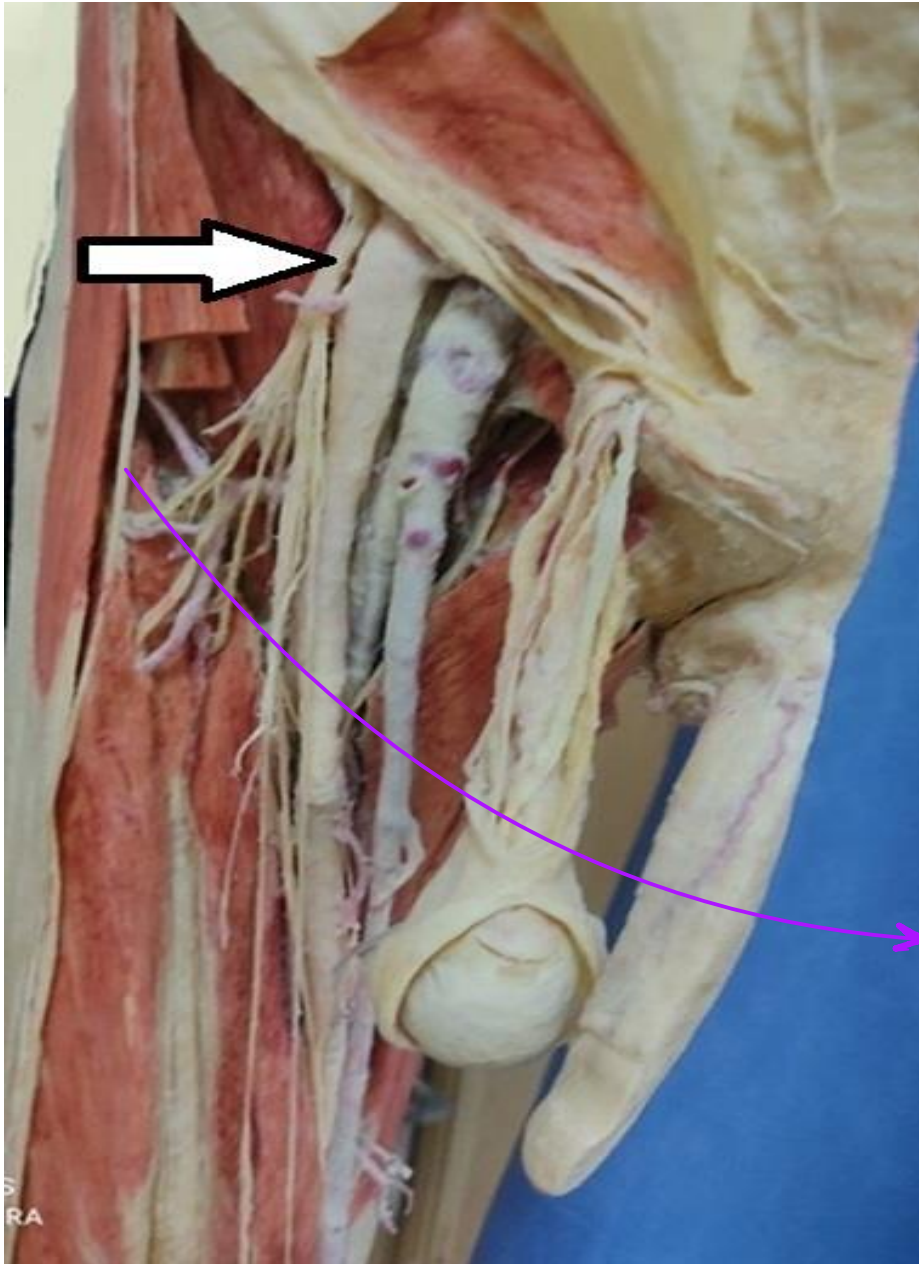
**3- Ulnar artery.**





Nerve associated with “meralgia paresthetica”.

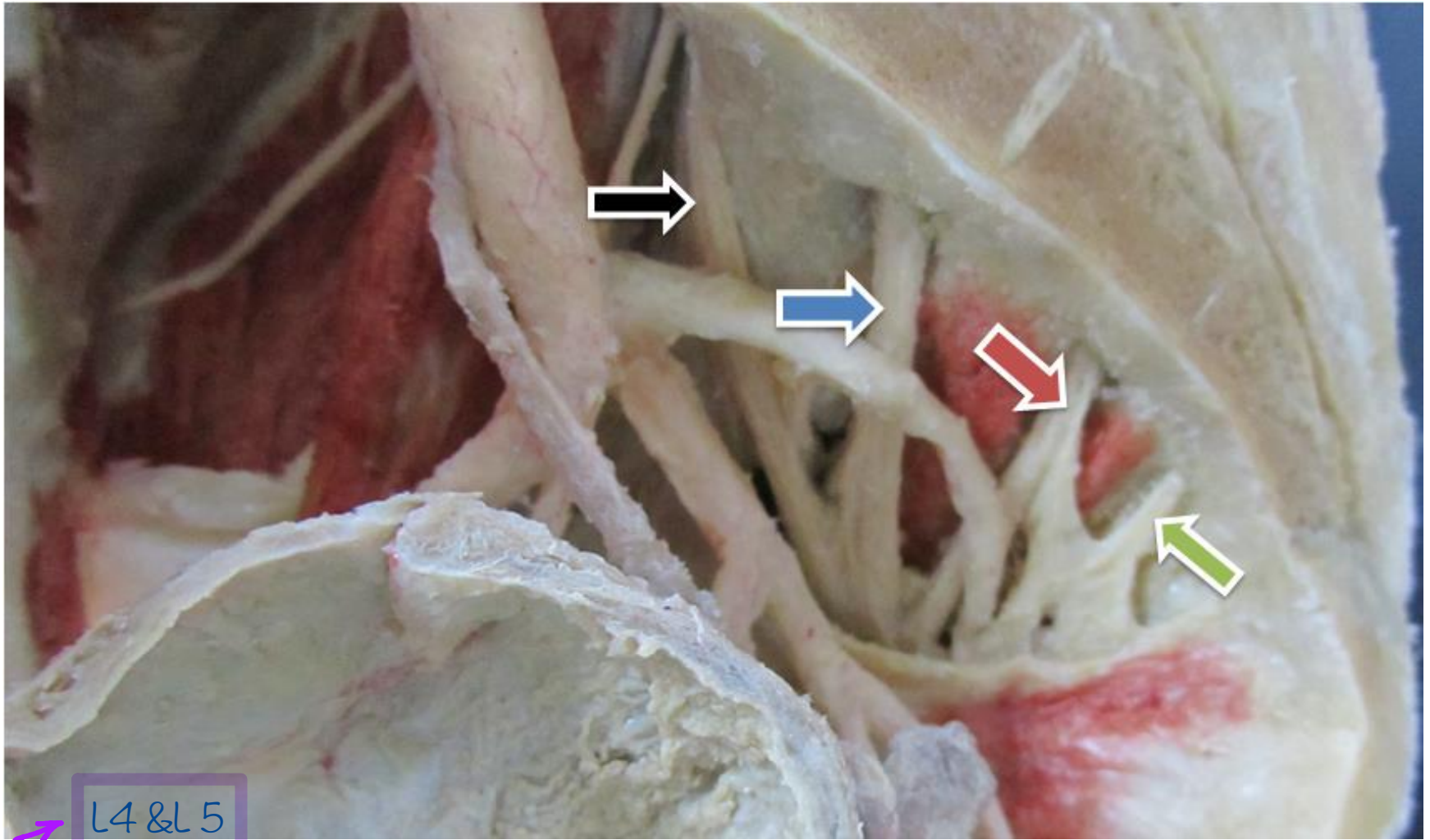
Lateral femoral cutaneous nerve.



**Femoral nerve** (black color arrow).

Lateral cutaneous nerve of the thigh



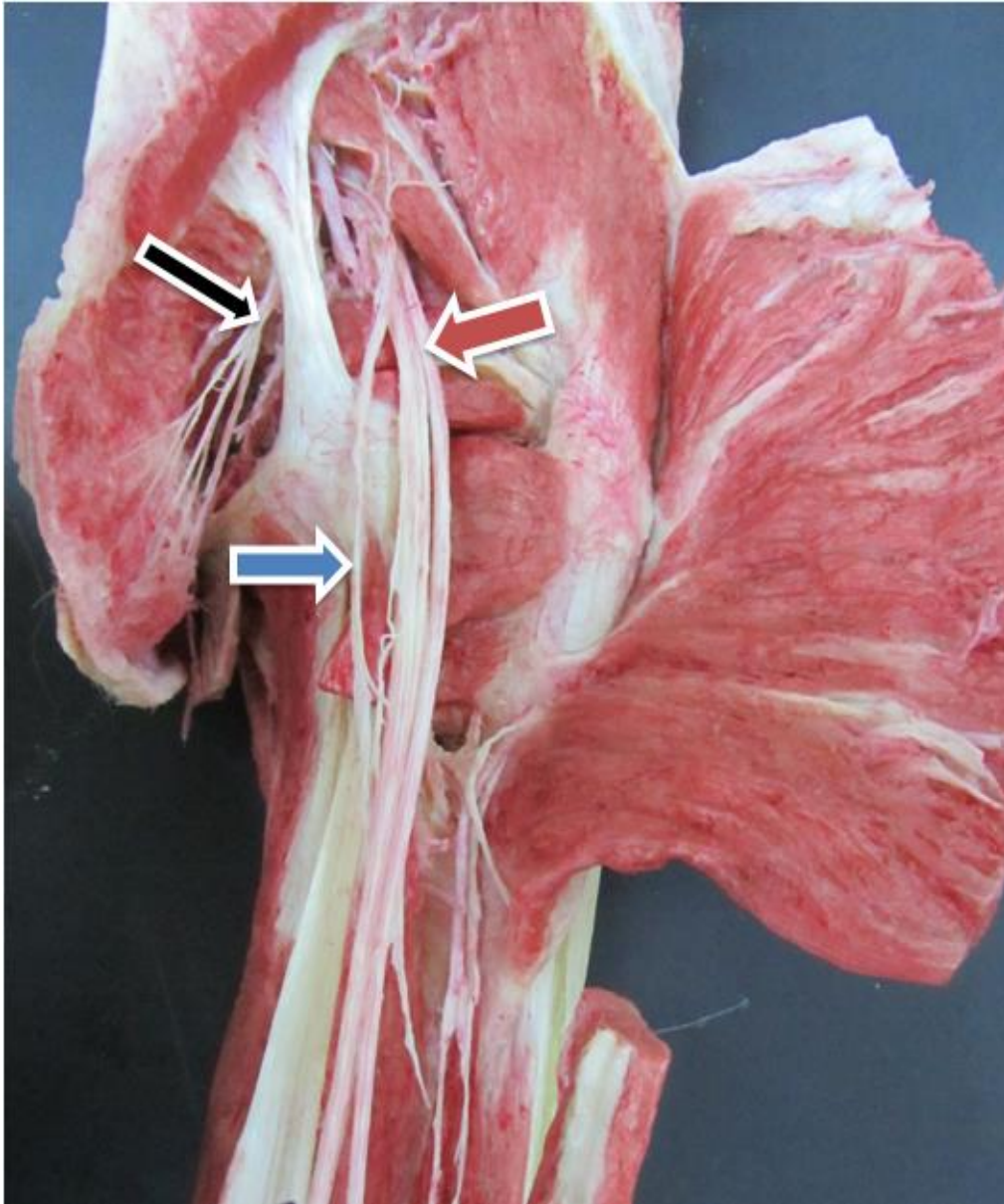


L4 & L5  
Lumbosacral trunk (black color arrow).

S1 (blue color arrow),

S2 (red color arrow),

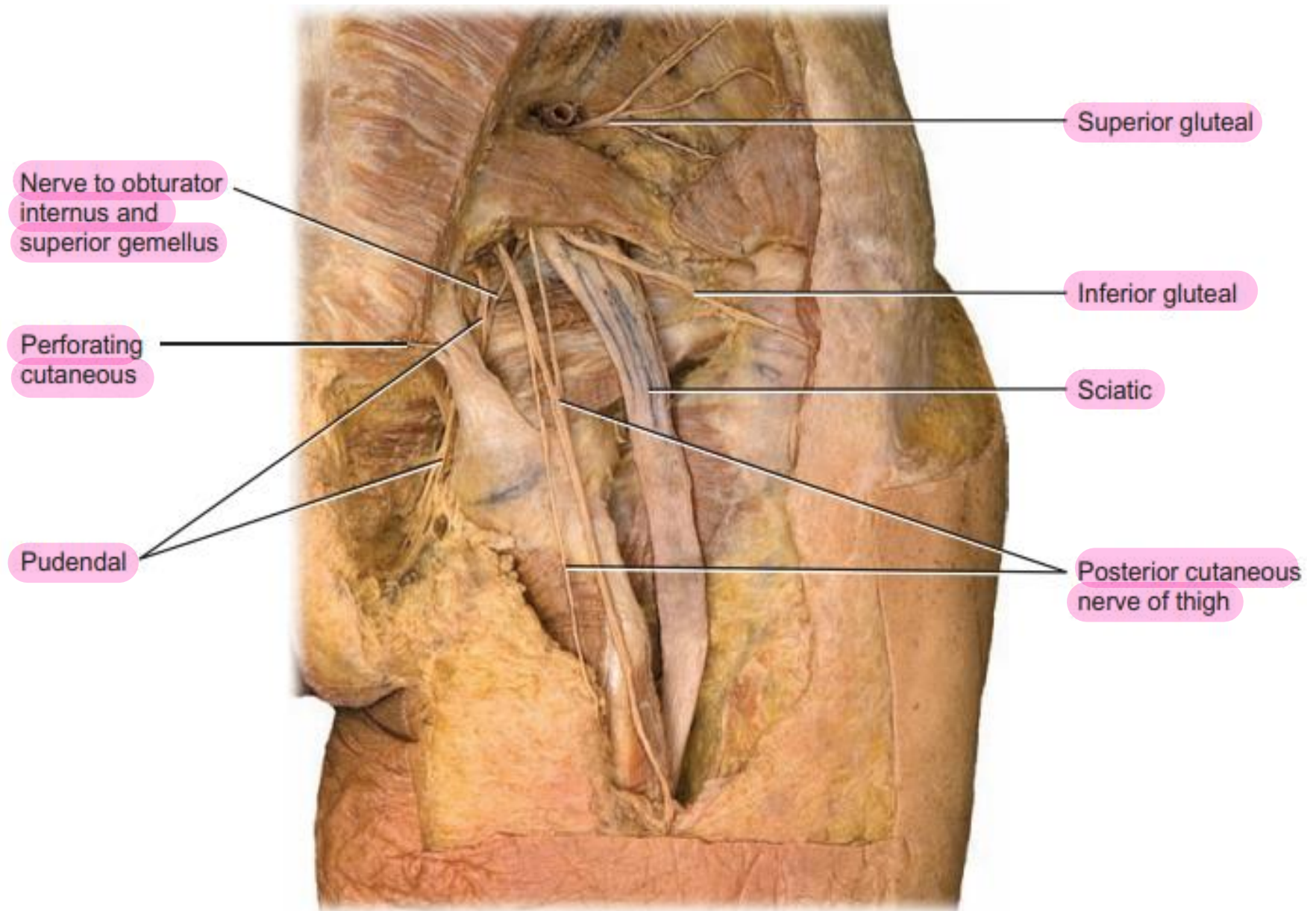
S3 (green color arrow),



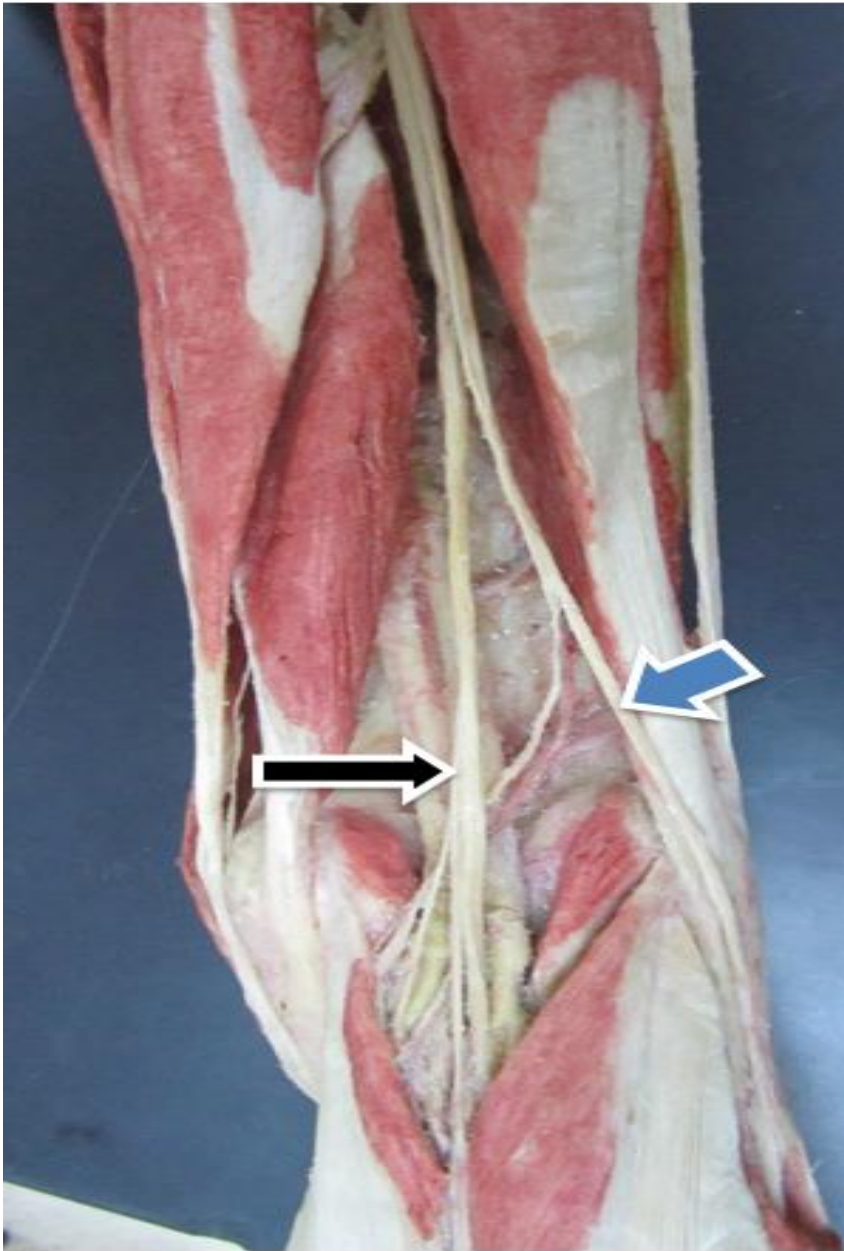
**Pudendal nerve** (black color arrow)

**Posterior femoral cutaneous nerve of the thigh** (blue color arrow),

**Sciatic nerve** (red color arrow),

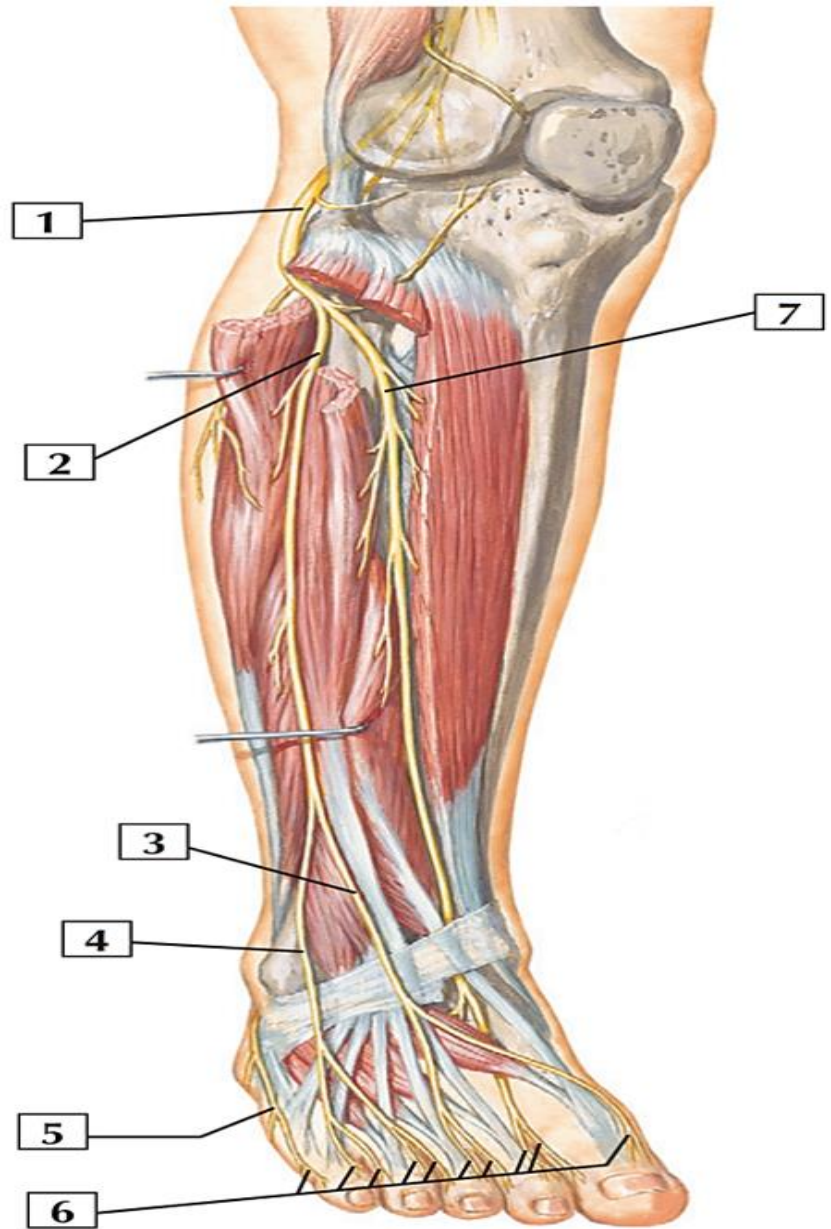






**Tibial nerve (black color arrow),  
Common peroneal nerve (blue  
color arrow).**

- 1- Common peroneal nerve.
- 2- Superficial peroneal nerve.
- 3&4 Dorsal cutaneous nerves.
- 5- Lateral dorsal cutaneous nerve of sural nerve.
- 6- Dorsal digital nerves.
- 7- Deep peroneal nerve.



*Thank  
you!*