النادي الطبي

ANATOMY

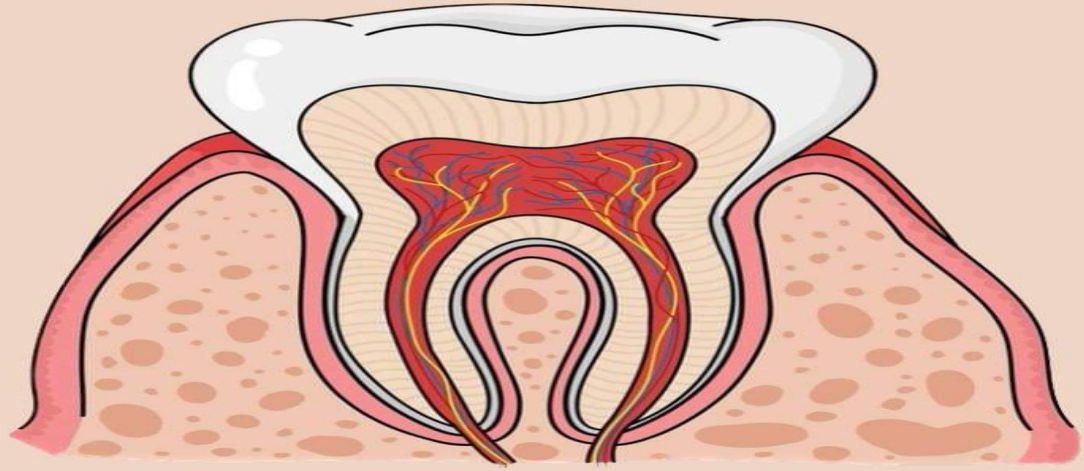

LEC NO. : 15

DONE BY : Nour Al-amoush.

وَقُل رَّبِّ زِدْنِي عِلْمًا

Anatomy & Embryology

Cardiovascular system (Part 2)

Dr. Heba Ali

Heba_ali@hu.edu.jo

Heba_ali@staff.hu.edu.jo

Quick recap.....

CVS 1 مراجعة لل

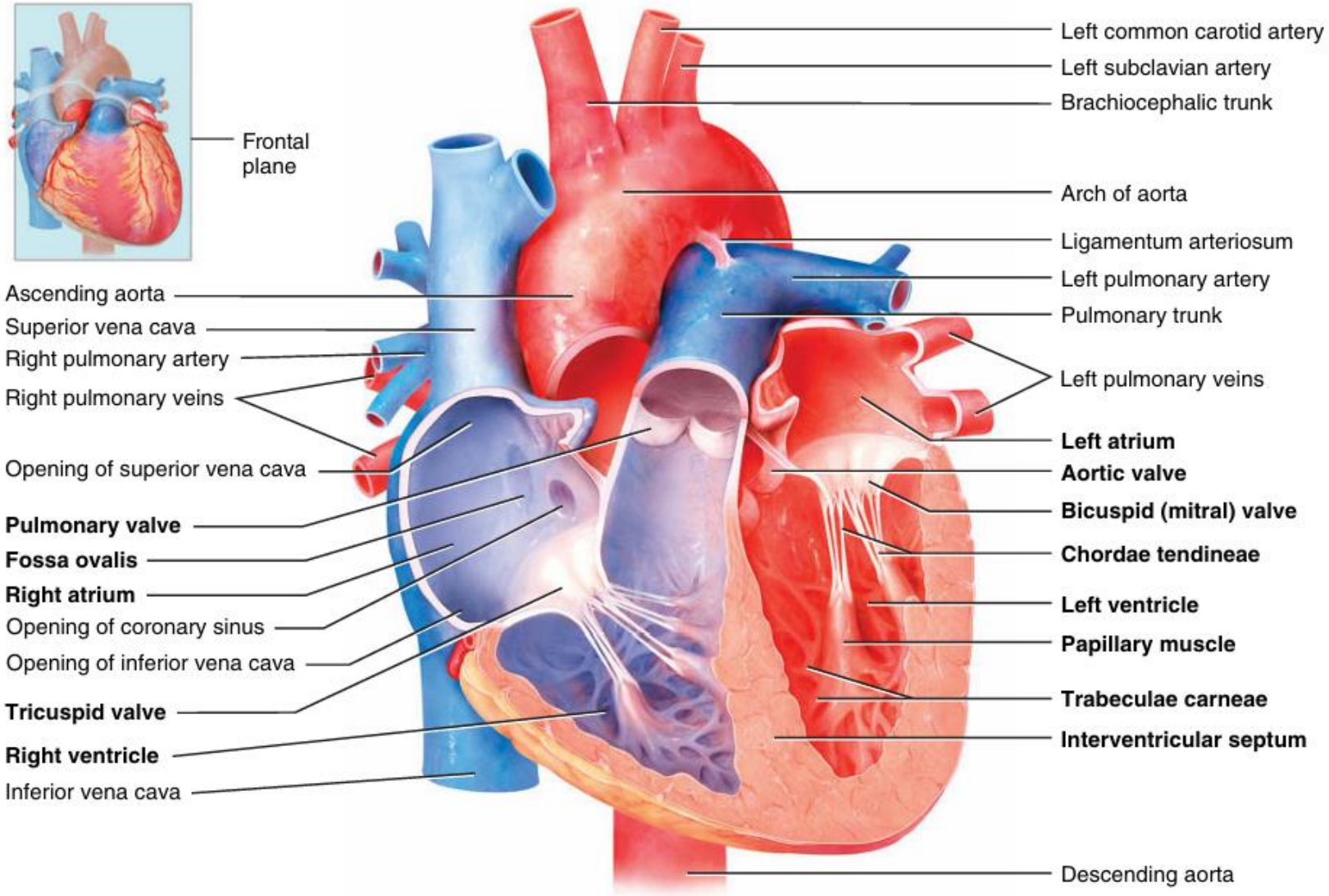

(a) Anterior view of frontal section showing internal anatomy

الأوعية الدّموية

Types of blood vessels

- 5-7 litres of blood
- 60,000 miles of vessels

- **Arteries** الشرايين
- **Capillaries** (or in some tissues **sinusoids**) the smallest of blood vessels, الشعيرات الدموية
- **Veins** الأوردة

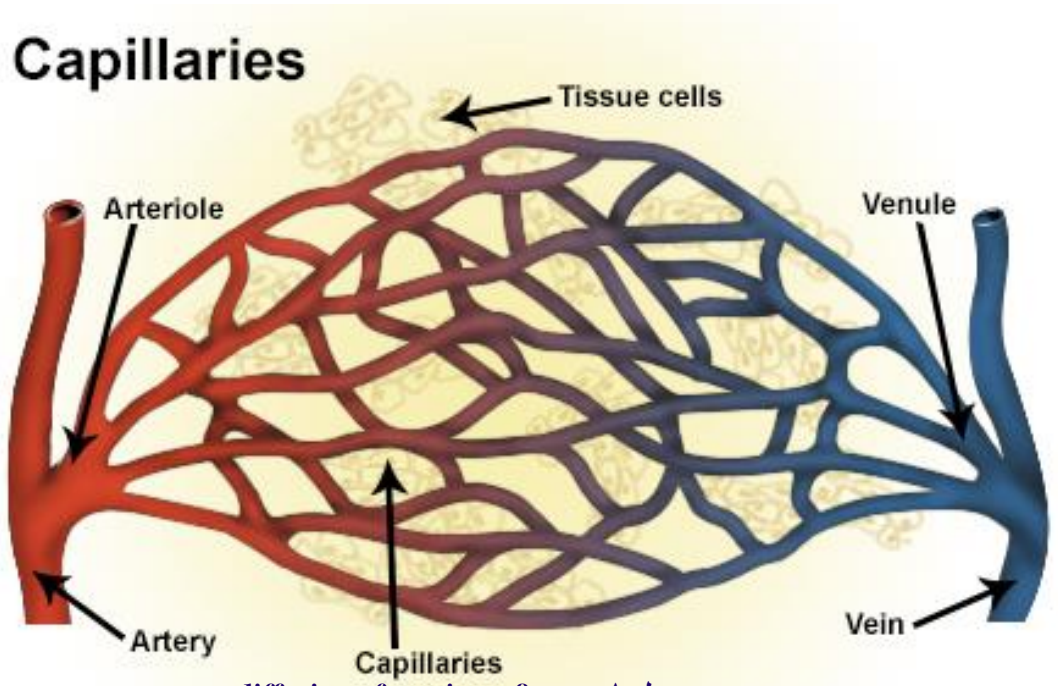

بصير عليها diffusion of nutrients & gases و
مكونة من simple layer of cells

Gas and nutrients exchange occur at the capillaries

Artery vs Vein → مهم جدًا

Artery	Vein
Carry **oxygenated** blood Except: **pulmonary artery** → non-oxygenated	Carry **non-oxygenated** blood Except: **pulmonary vein** oxygenated
Carry blood **away** from the heart	Carry blood **towards** the heart
No valves → حمامات	Have valves
Narrow lumen, thick wall ضيّق سميك	wide lumen, thin wall واسع رفيع
Walls are rich with smooth muscles >>>**non-compressible** غير قابل للضغط	Walls are poor with smooth muscles >>>**compressible** لو ضغطته بحيرله . Collapse

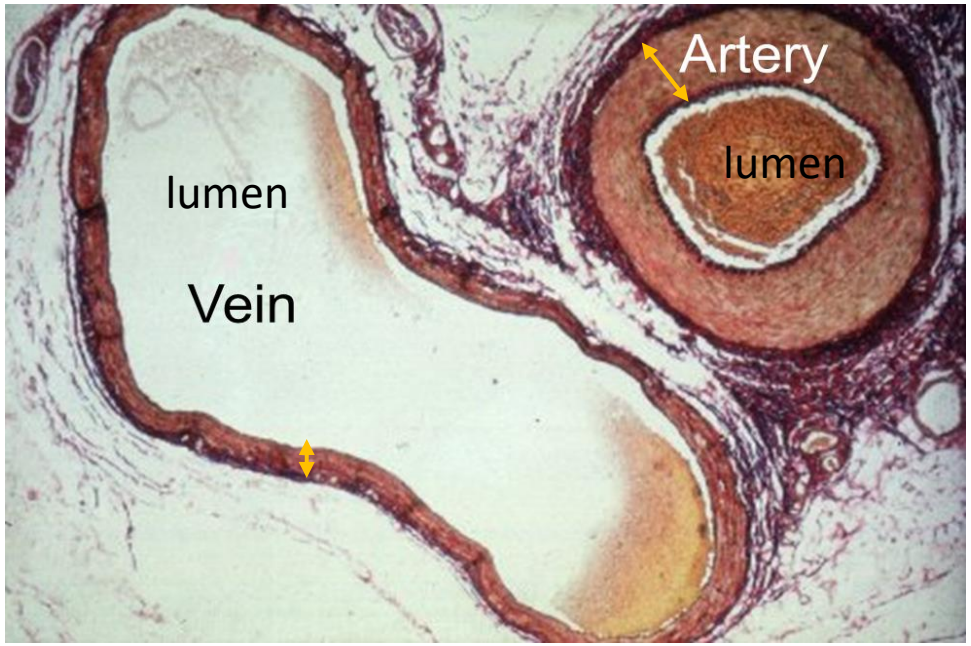

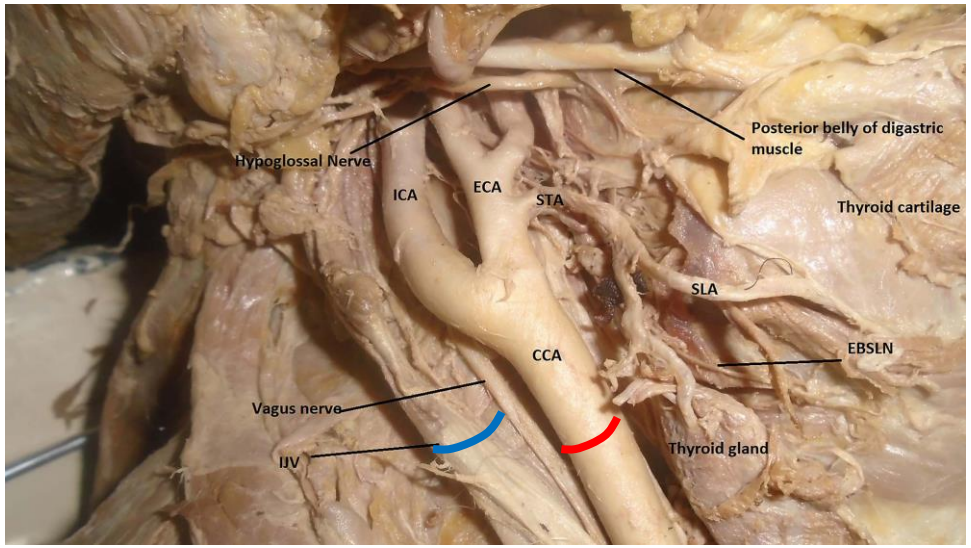

Venous valves are important in moving blood toward the heart against the force of gravity.

مهمة خاصةً في legs انه بتحرك الدم لفوق لجهة القلب بحيث انه ما يرجع لتحت
بالاضافة لحركة skeletal muscles الموجودة ب (calf muscles) posterior compartment of the legs
لهيك هاد سبب انه يلي يسافروا مسافات طويلة بضلهم يتمشوا لانه بكونوا معرّضين لحدوث الجلطات ف بمشوا عشان
يتحرك الدم.

- **Capillaries**, the smallest and most numerous of the blood vessels, form the connection between the vessels that carry blood away from the heart (arteries) and the vessels that return blood to the heart (veins).
- The primary function of capillaries is the exchange of materials between the blood and tissue cells.

بهاي الحالة ما بمر الدم ب capillaries

- **Direct Arterio-venous anastomoses** is a direct connection between small arteries and small veins in certain tissues with **NO** capillary section between them (completely bypassing the capillary bed)
  - Regulation of blood flow
  - Regulation of the body temperature

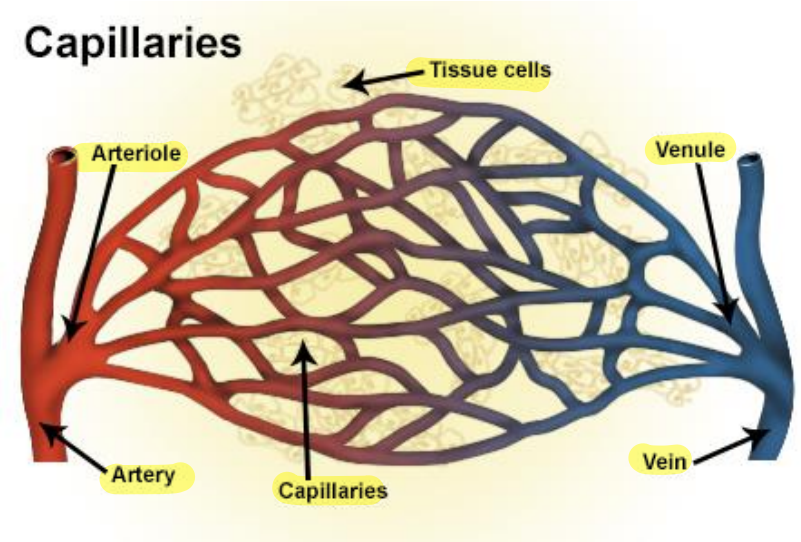

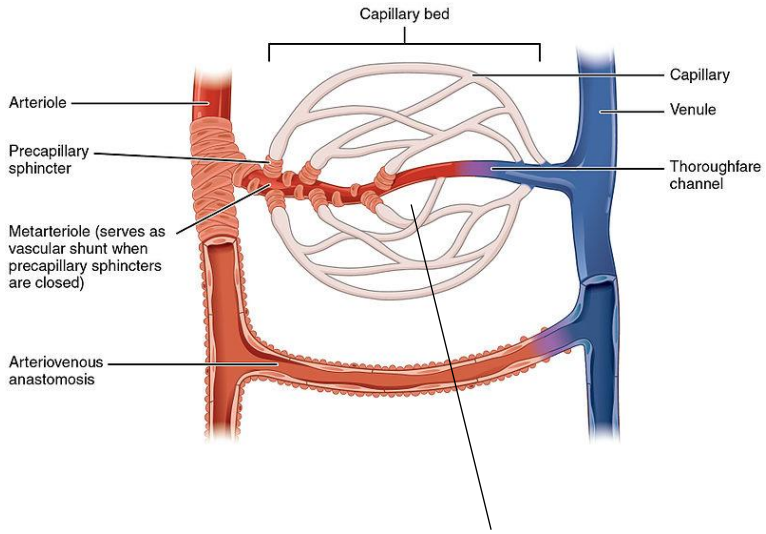

Arterio-venous anastomosis

There are 2 main circulations :
Systematic & pulmonary circulation

Pulmonary circulation

دائمًا بتعود للـ lungs

- First described by the muslim physician Ibn Al-Nafees → حويلي رسمها أول مرّة

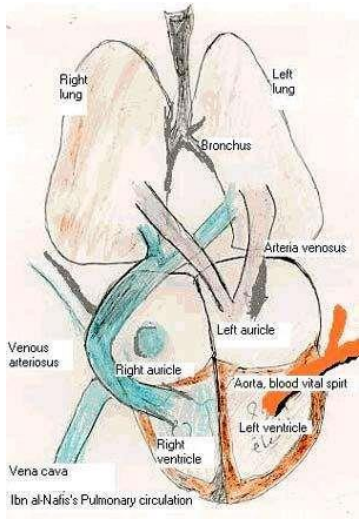



- Blood leaves **right ventricle** to the lungs through **pulmonary arteries** → no O_2 and returns back to the heart through **pulmonary veins**. O_2

باختصار يلي بصير :
الدم يلي جاي من superior & inferior vena cava و دخل ب RT atrium رح يروح للRT ventricle و منها بروح للpulmonary trunk و بعدها للPulmonary artery و منها للlungs هناك بصيرله oxygenation بعدين برجع للLT atrium و منها للLT ventricle و بعدها بكمل ب systemic circulation

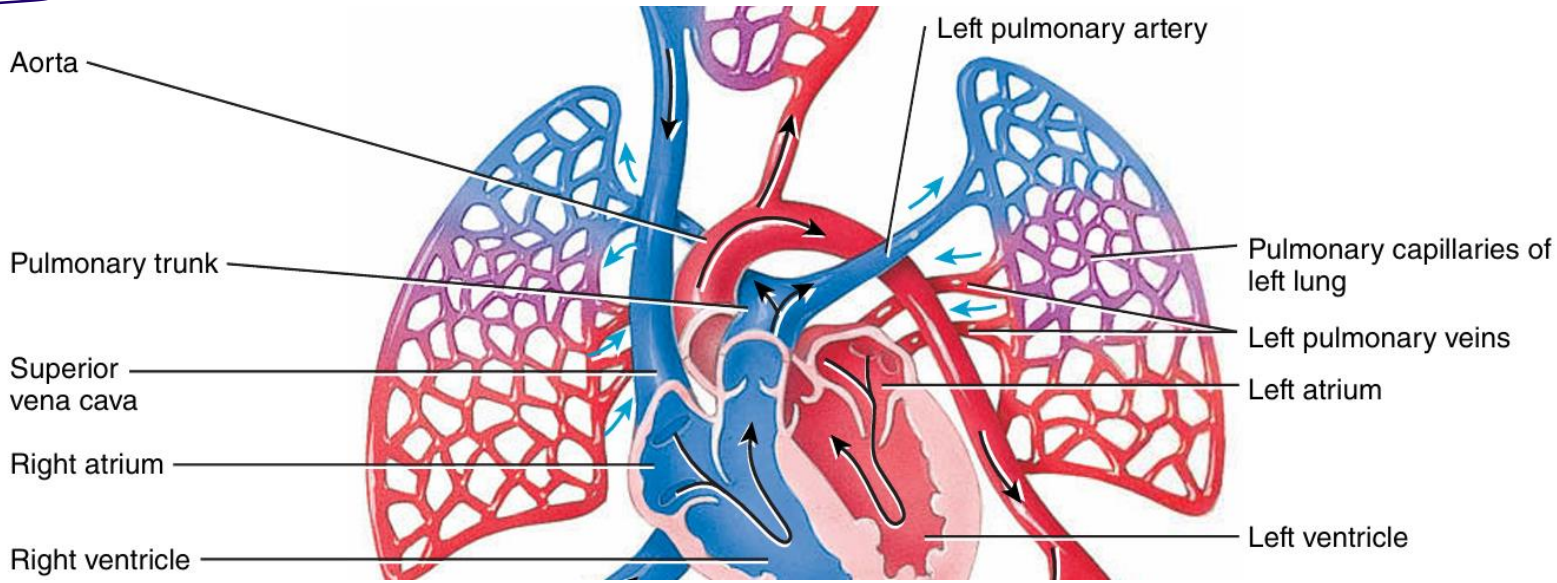

هاي بتكون اكبر و تشغل كل اجزاء الجسم

Systemic circulation

- Blood leaves **left ventricle** through aorta to all tissues of the body.

  بتغذي lower & upper limbs & pelvis & abdominal region &thorax

- Includes all arteries and arterioles that carry oxygenated blood from the left ventricle to systemic capillaries, plus the veins and venules that return deoxygenated blood to the right atrium after flowing through capillaries in the body organs.

يعني بتودّي الدم يلي فيه اكسجين لكل الجسم عن طريق arteries يلي طالعة LT ventricle
و بتاخد الدم يلي ما في اكسجين من كل الجسم عن طريق veins لتوصلها لل RT atrium عشان ترجع للlungs و اخليه في اكسجين و هكذا

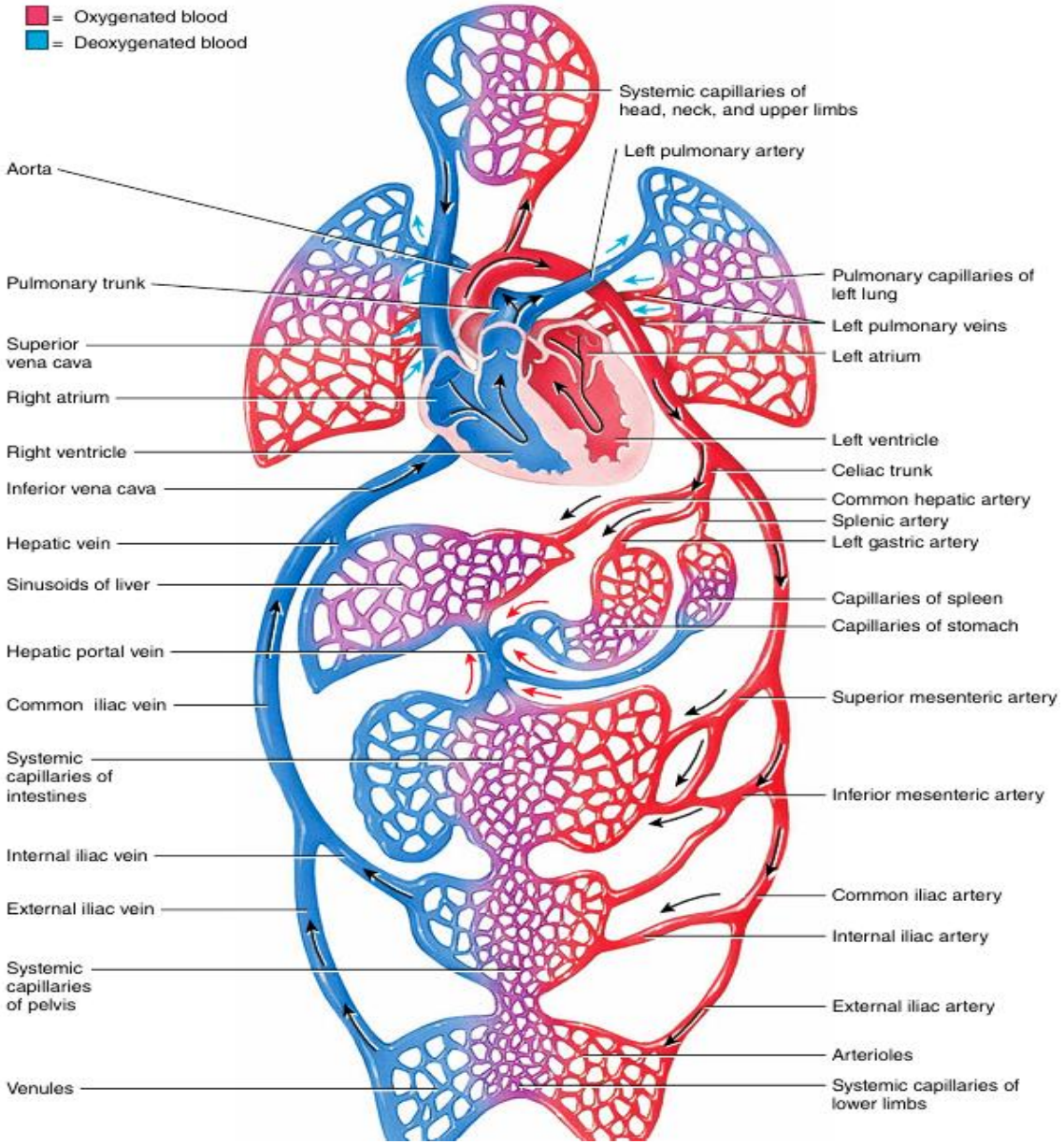

The main blood vessels in the human body

في عنا كتيير غير الموجودين بس احنا مطالبين باللي موجودين بالسلايدات

lungs

1. **Pulmonary trunk** arises from right ventricle and carries de-oxygenated blood to the lungs.

   Blue → No O_2
   Red → O_2

2. **Aorta** consists of four segments:

   زي اشي رافع القلب

   - **Ascending aorta** طالع من القلب و اله 2 branches يلي هما coronary arteries (الشرايين التاجية)
   - **Arch of aorta**
   - **Descending thoracic aorta** → in Thorax
   - **Descending abdominal aorta** → in abdomin

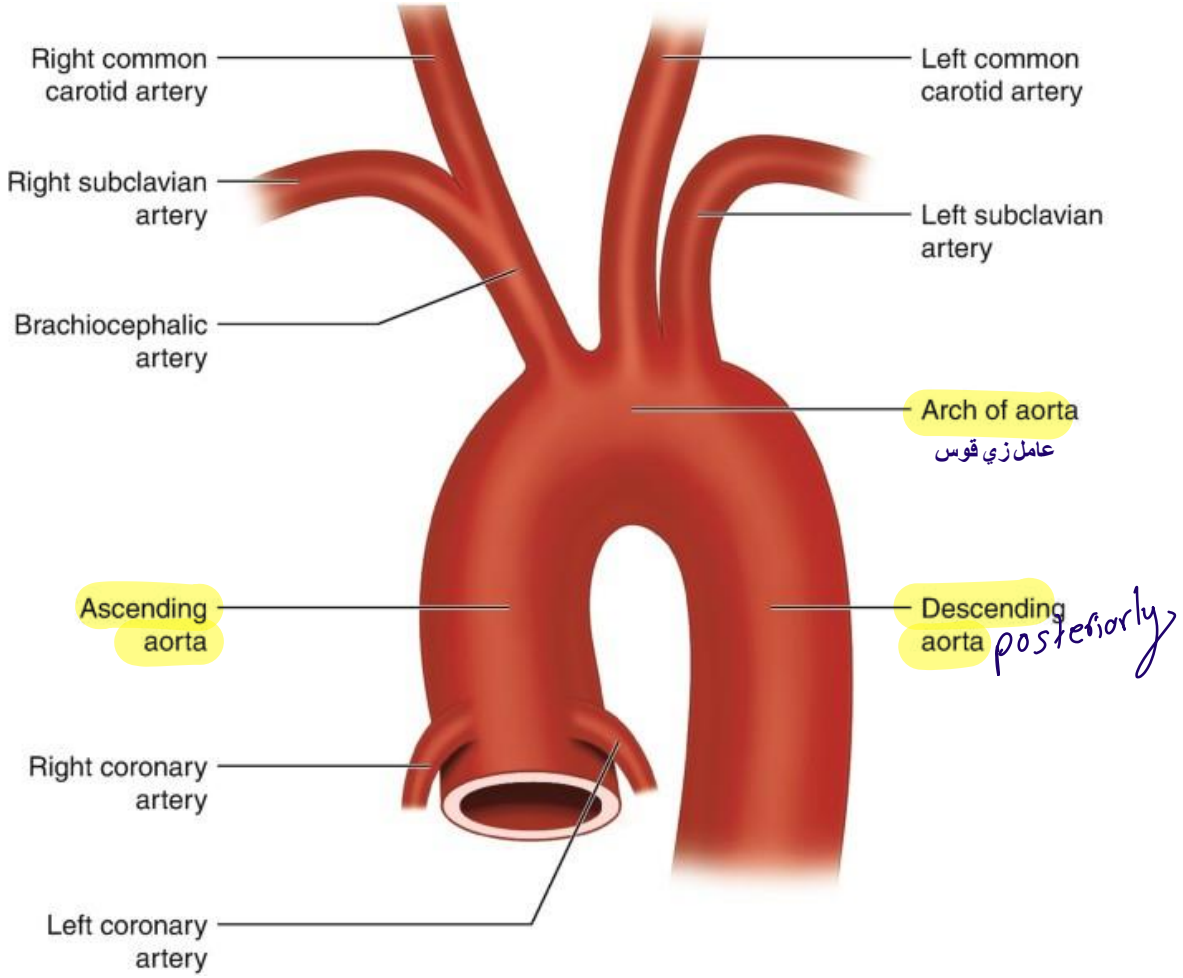

Segments of the aorta

1. Ascending aorta (about 5cm in length, lies within the **fibrous pericardium**, passes upward to the right). → heart + diaphagram

- Branches:
  - **Right coronary artery**
  - **Left coronary artery**

الشرايين التاجية.

تذكروا انه القلب موجود في middle of Mediastinum

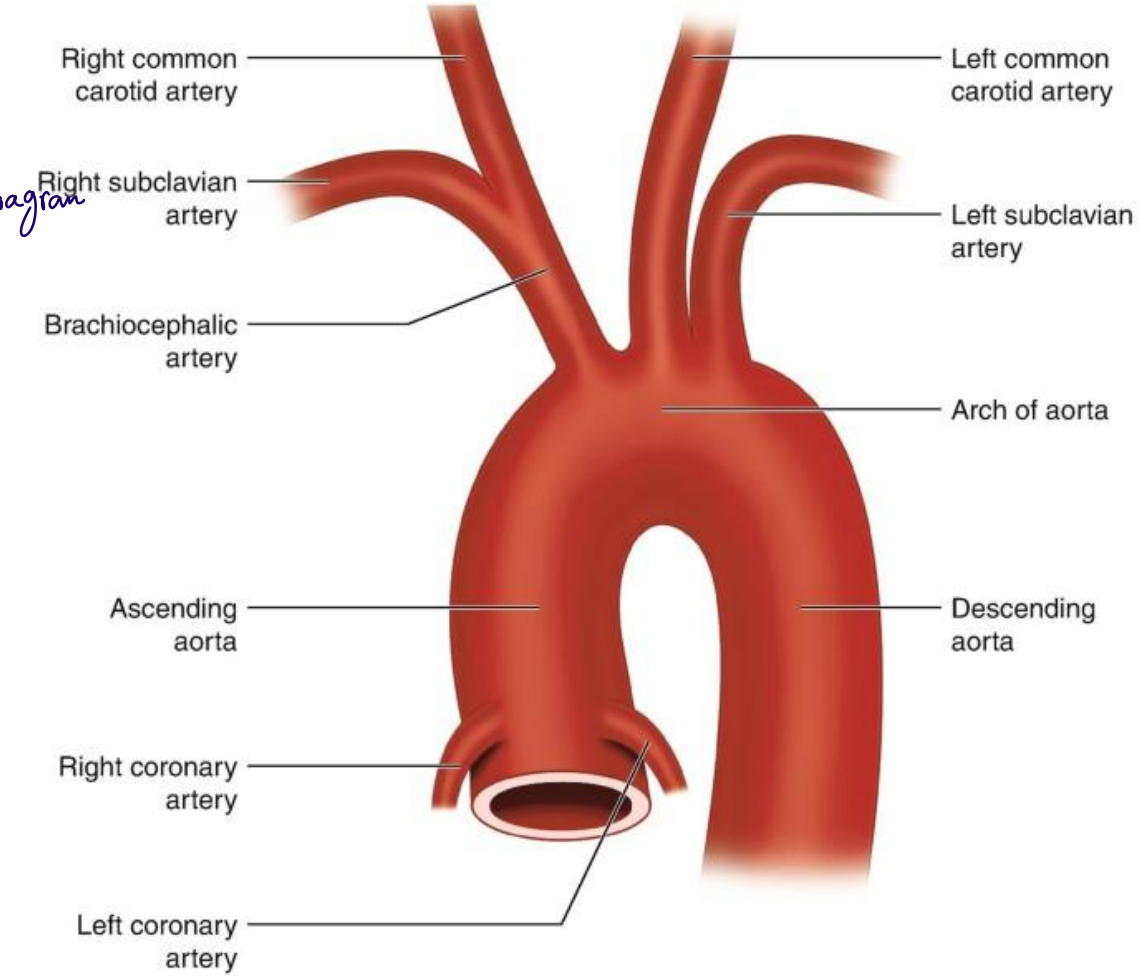

2. Arch of aorta, continues from the ascending aorta and lies mainly within the **superior mediastinum**

مهمين جداً Branches

Mediastinum is a part of IVC

Branches:

1. Left subclavian artery → To the upper limbs

2. Left common carotid artery → neck region

(Right) upper limbs + head + neck

3. Brachiocephalic artery (or brachiocephalic trunk) is the largest branch in diameter.

   Divides into:

   - Right subclavian artery
   - Right common carotid artery

   not directly branches to upper limbs

The arch of aorta is anterior to the oesophagus and the trachea

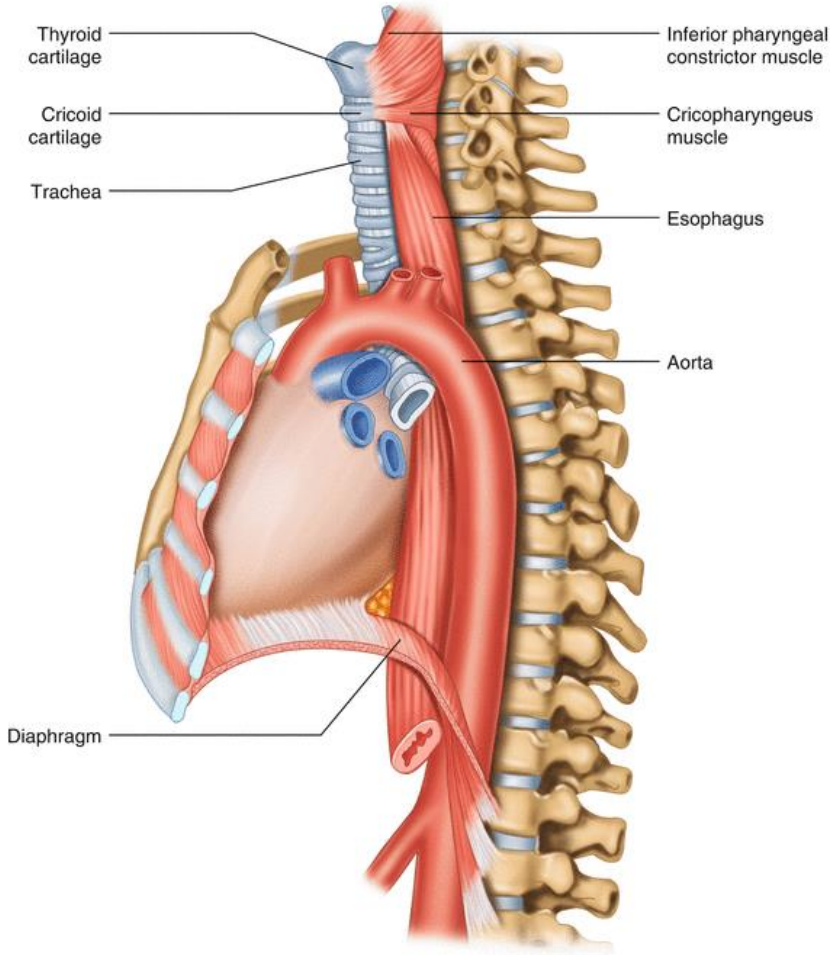

Subclavian arteries: RT + LT indirect

The right subclavian artery is a branch of the brachiocephalic trunk, while the **left subclavian** is a direct branch of the aortic arch.

Scalene: anterior + middle + posterior
Anterior + middle > بطلع منهم subclavian artery & vein

Subclavian artery is divided into three segments: To supply muscles.

1. First part from its origin to the **medial border of scalenus anterior**;
2. Second part **posterior to scalenus anterior.**
3. Third part from the **lateral margin of scalenus anterior to the outer border of the first rib**

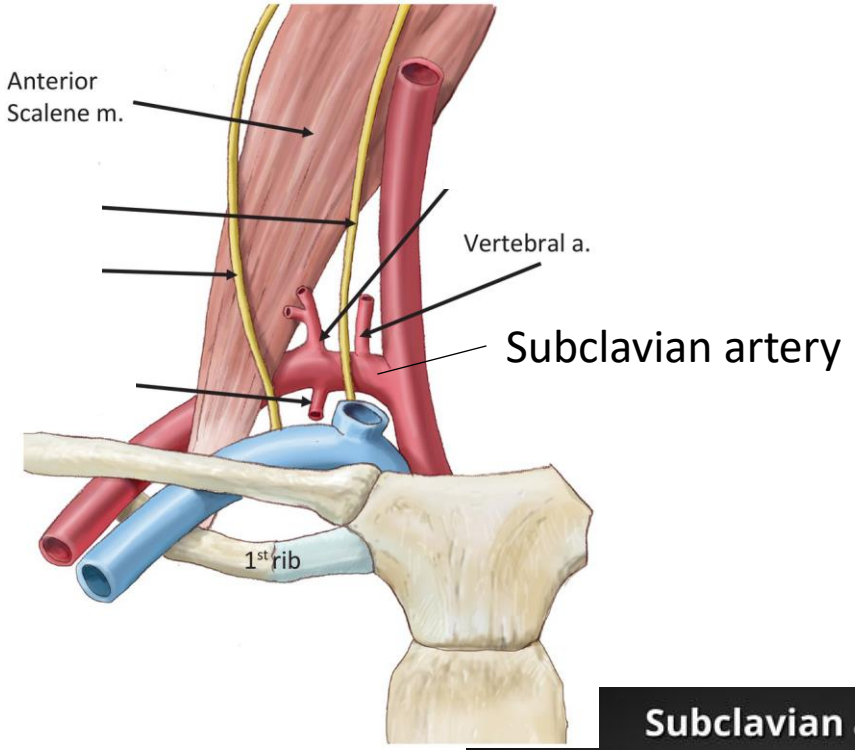

منطقة الابط

Axillary artery

هلا lateral side بصير اسمه شريان اخر لانه صار بمنطقة مختلفة و اللي هي axilla (منطقة الابط) بصير اسمه axillary و هو عبارة عن artery continuation of subclavian artery

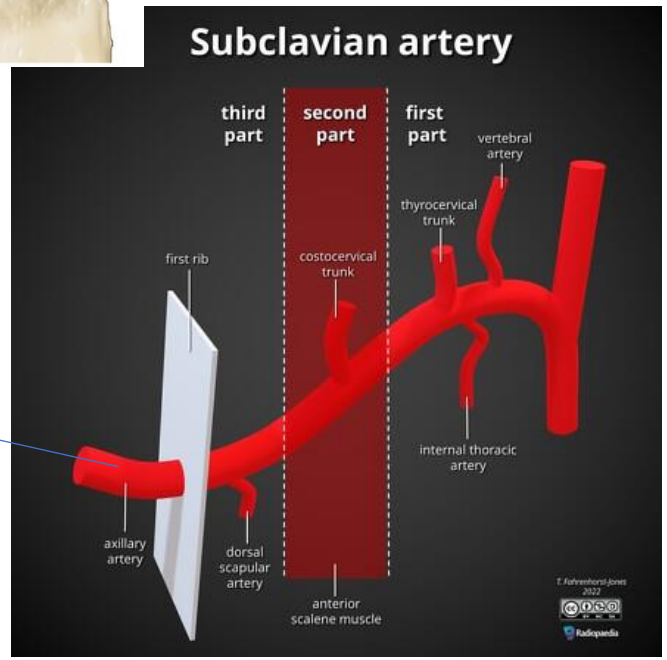

The right common carotid has only a **cervical part** whereas the left common carotid has **cervical and thoracic parts**.

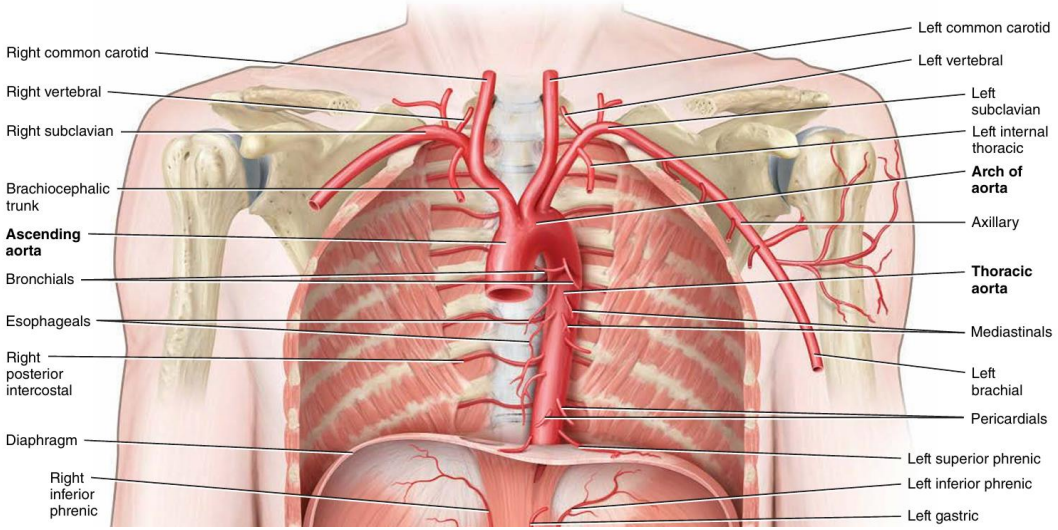

Common carotid artery divides into:

1. External carotid artery which supplies the **face and neck**.
2. Internal carotid artery which provides main arterial blood supply to the **brain**.

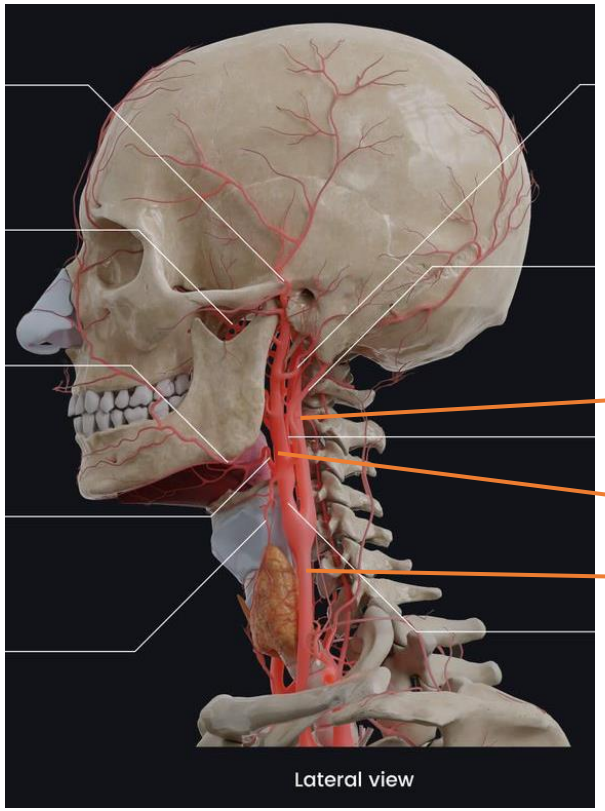

Internal carotid artery

External carotid artery

common carotid artery

Facial artery is a branch of the **external carotid artery**, it has **tortuous route** along the nasolabial fold towards the medial angle of the eye. This is important as muscles and organs of the face are **very movable**

متعرّج

ليش متعرج؟ لانه عنا عضلات بالوجه و هاي بتكون مش مستقيمة ف عشان هيك الشريان بكون متعرج ليتحرك مع العضلات

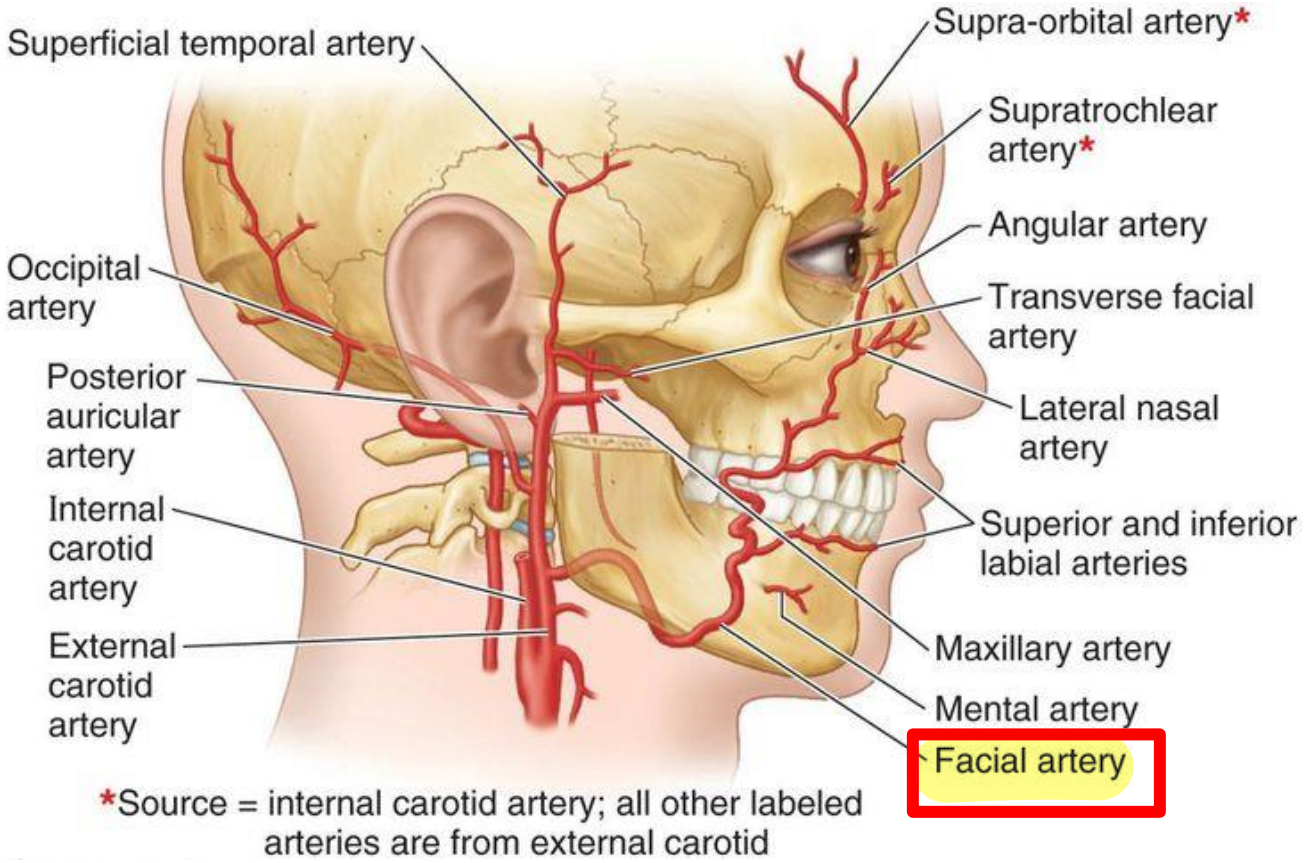

The axillary artery, a continuation of the subclavian artery, begins at the outer border of the first rib and ends at the inferior border of teres major, where it becomes the **brachial artery**. موجود ب Arm

The brachial artery is a continuation of the axillary artery. It begins at the inferior border of the tendon of teres major and ends about a centimetre distal to the elbow joint (at the level of the neck of the radius) by dividing into the radial and ulnar arteries.

Radius → laterally

Radial artery is at the lateral side of forearm while the **ulnar artery** **is at the medial side.**

ulna → medially

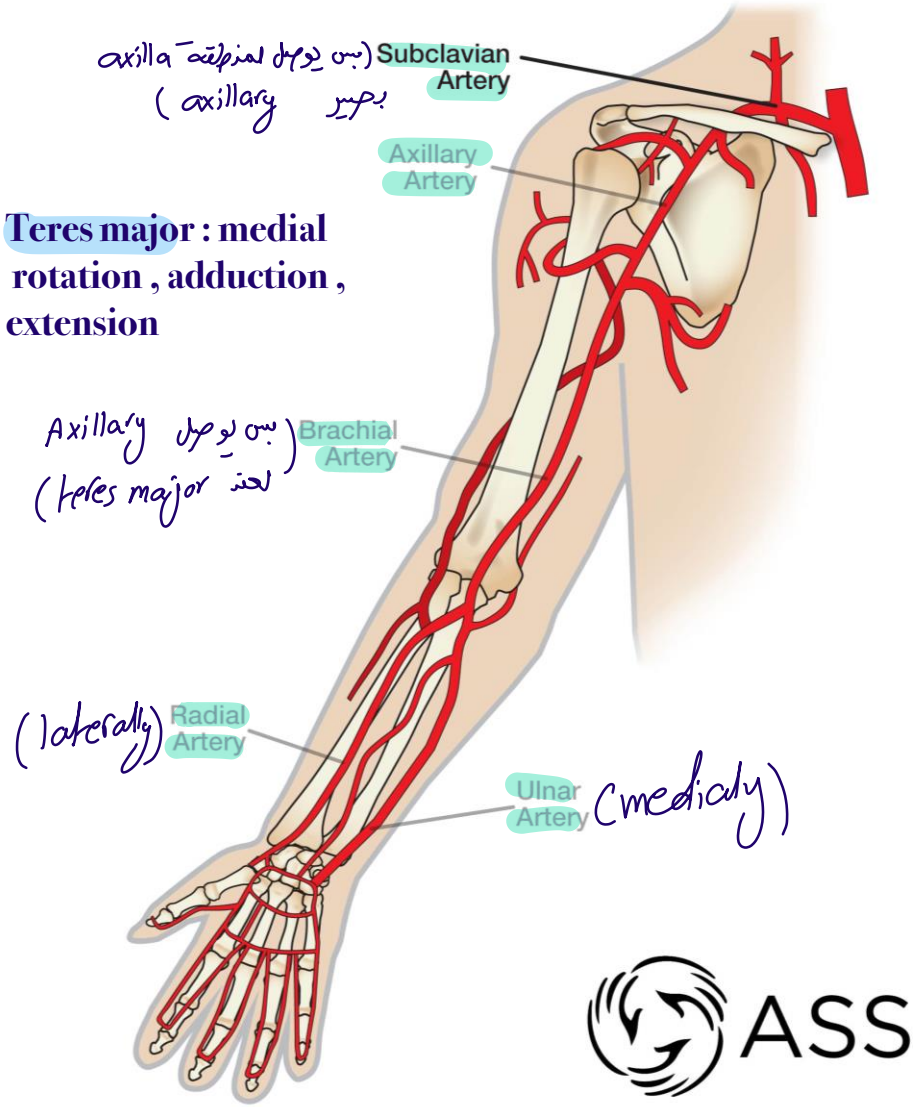

ASS

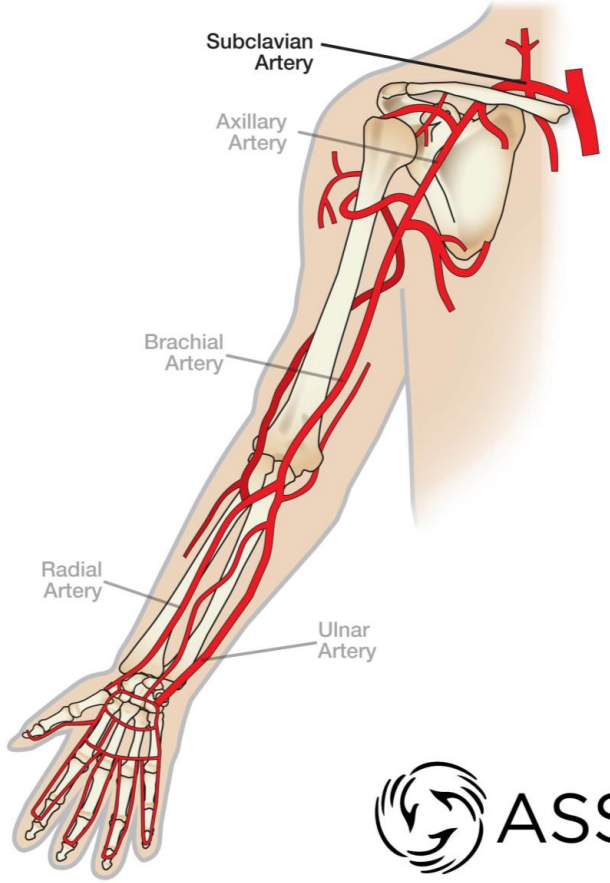

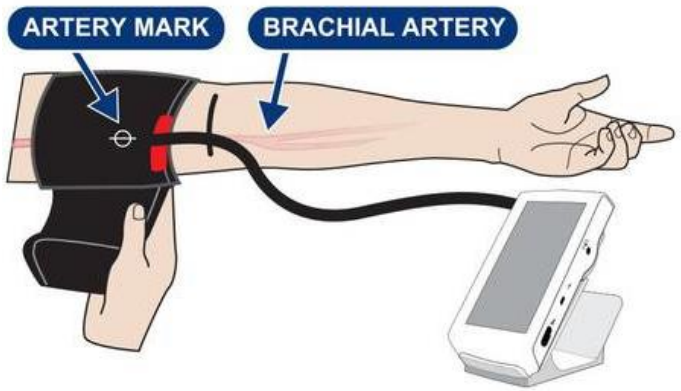

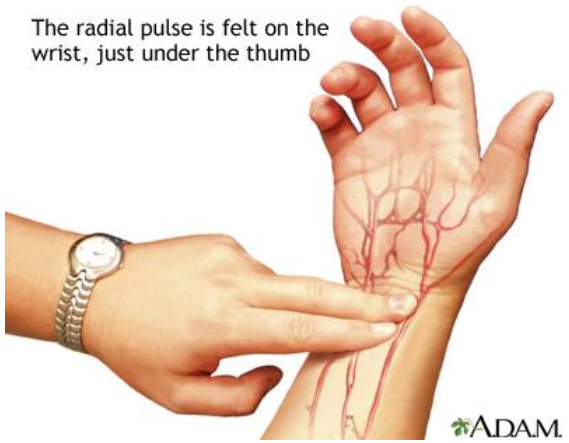

ASS

- **Brachial artery** is the artery used to measure your blood pressure medial to the tendon of biceps brachii. → يستخدم لقياس الضغط

at wrist

The radial pulse is easily felt by the tip of the index and third fingers just lateral to the tendon of the flexors carpi radialis

above the diaphagram.

3. Descending thoracic (Thorax) aorta, lies within the posterior mediastinum.

Extends between T4-T12.

Main branches are divided into:

Visceral branches: الأحشاء

1. Pericardial branches
2. Bronchial arteries
3. Oesophageal arteries to esophagus
4. Mediastinal arteries

Parietal branches: راحة الجدار

1. Intercostal arteries
2. Superior phrenic

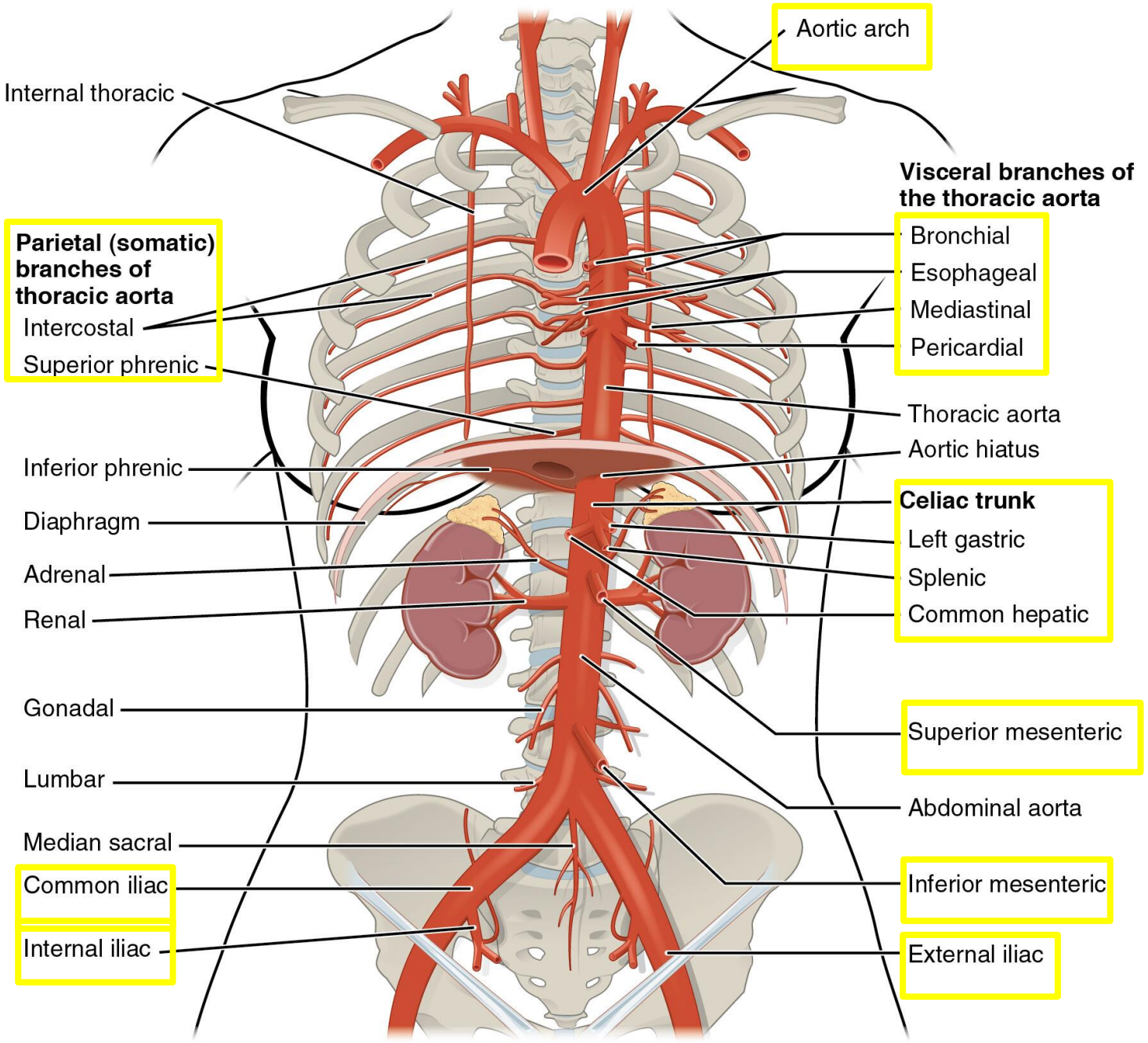

4. Descending abdominal aorta, starts at T12 and ends at L4, main branches are:

- Unpaired (single) branches that arise from the anterior aspect: To the intestine, stomach, ---
  1. Celiac trunk
  2. Superior mesenteric artery
  3. Inferior mesenteric artery

- Paired branches arise from the lateral aspect (RT + LT)
  1. Renal arteries → To the kidneys)
  2. Adrenal arteries
  3. Gonadal arteries → To ovaries + Testes
  4. Four lumbar arteries

- Terminal branches (two common iliac arteries) هون عند النهاية

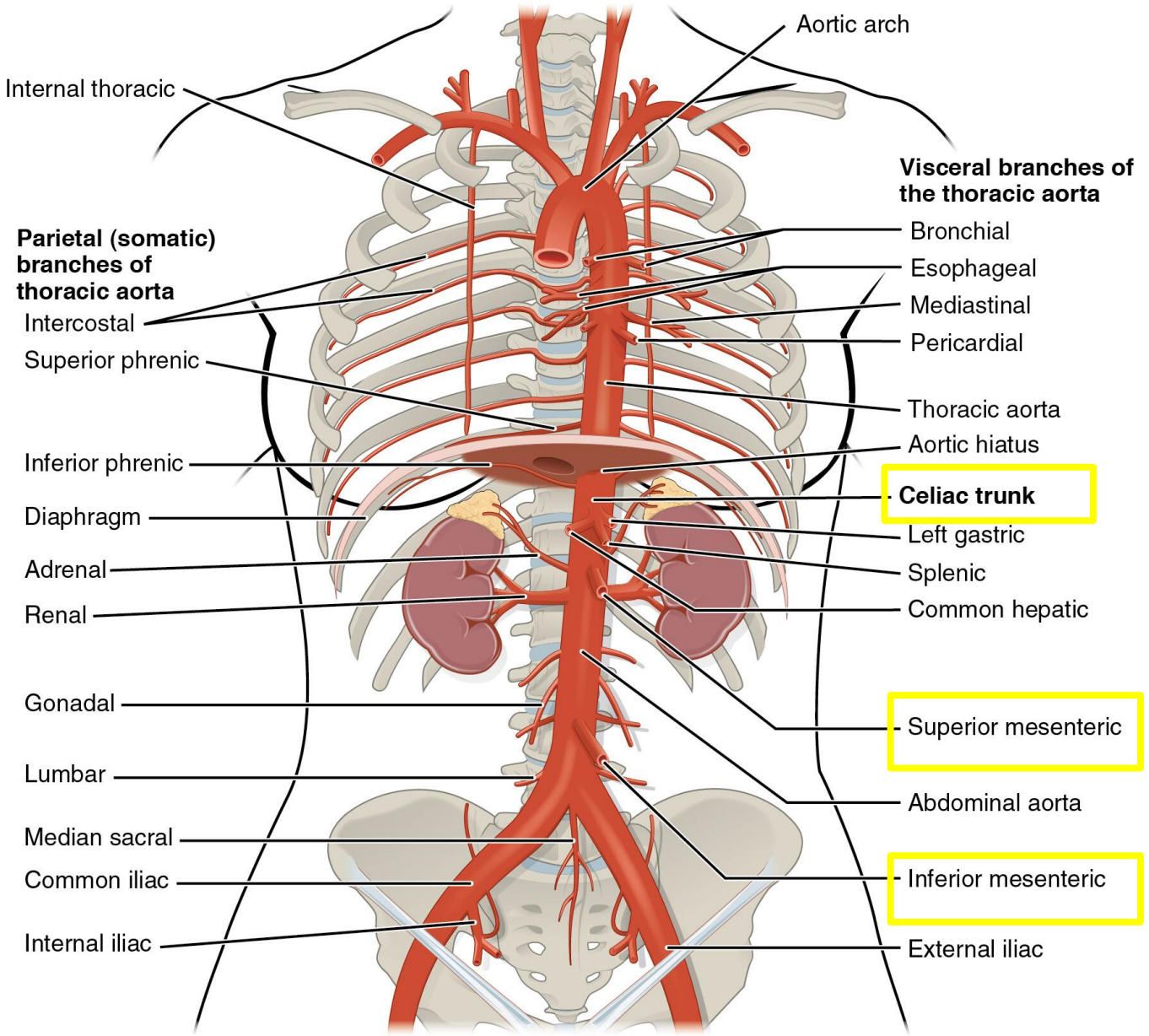

iliac arteries

internal → supply to pelvic organs

external → بكمل من ورا بجدين بصيرين femoral artery (نفسه بس تغيرت المنطقة).

Arterial supply to the lower limb

pelvis

The femoral artery is a continuation of the **external iliac artery** and provides the principal arterial supply to the lower limb. It begins posterior to the inguinal ligament, midway between the anterior superior iliac spine and the pubic symphysis, descends in **the femoral triangle**, enters and passes through the adductor canal, and becomes the **popliteal artery** as it passes through an opening in adductor magnus.

* باختصار هاد يلي بهمنا بس اقرأوا الباقي احتياط

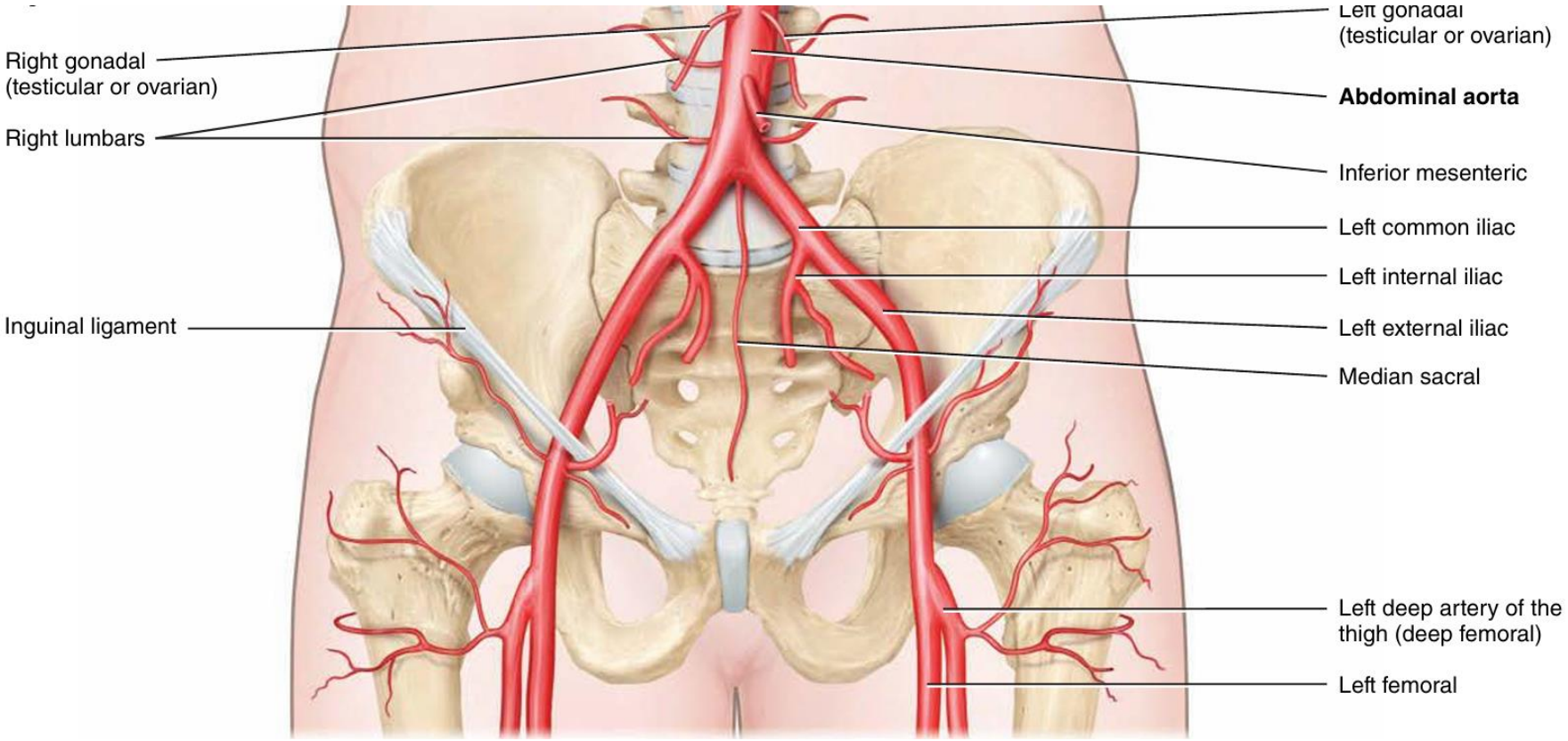

Arterial supply to the lower limb

مش عالجة
اشوفها

- **Popliteal artery** is the continuation of the **femoral artery** and crosses the popliteal fossa. It descends laterally from the opening in adductor magnus to the femoral intercondylar fossa.
- It gives two branches; **<u>the anterior and posterior tibial arteries.</u>**

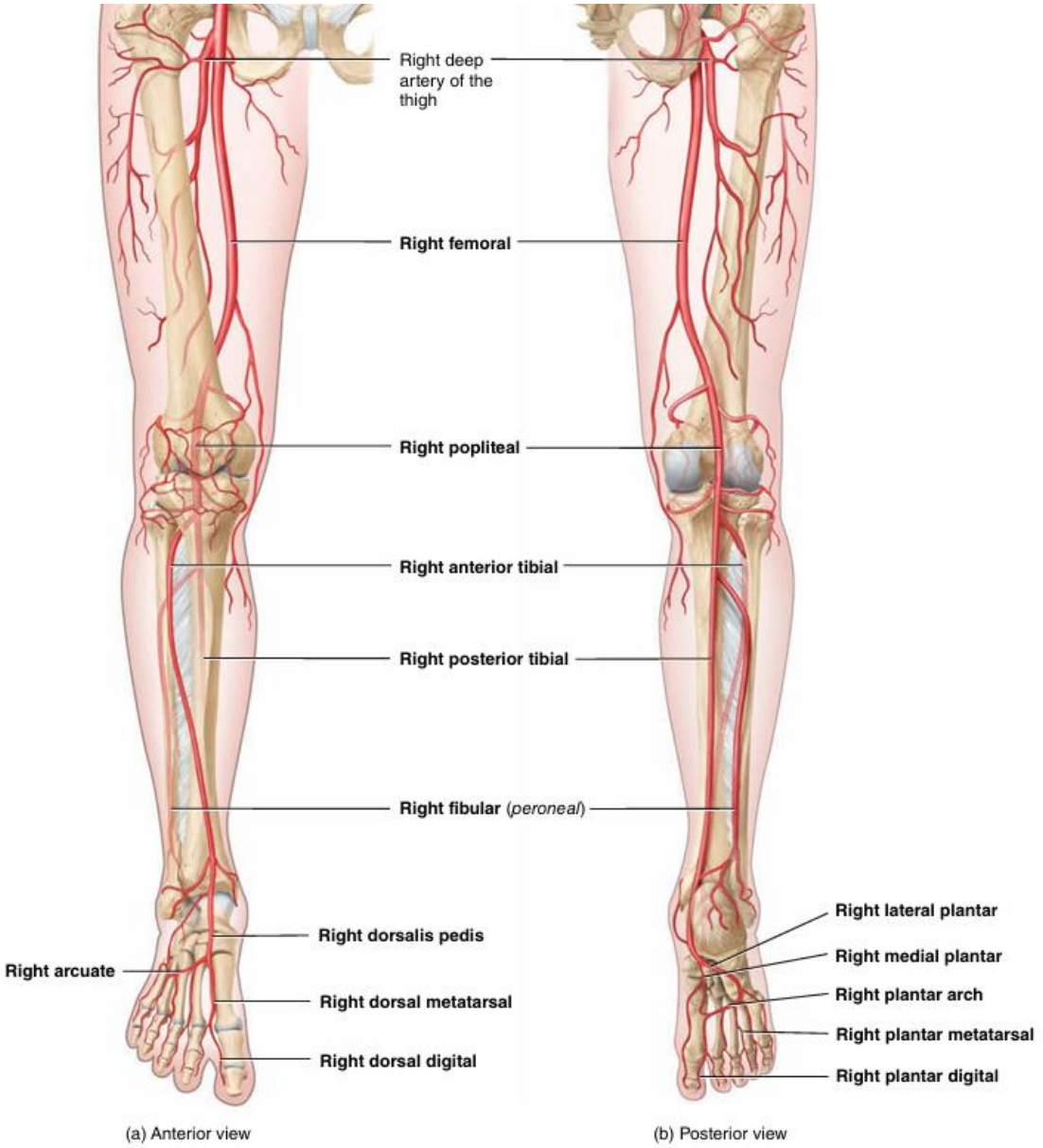

Collateral circulation

- Is a connection or (anastomosis) between the branches of adjacent arteries
- Back-up blood supply in case of blockages.
- **Exists mainly around joints**

in upper + lower limbs

mostly here

عشان هيك لو صار في كسر بالفخذ او بالايد مرات ممكن يروح الشريان يلي بغذي المنطقة

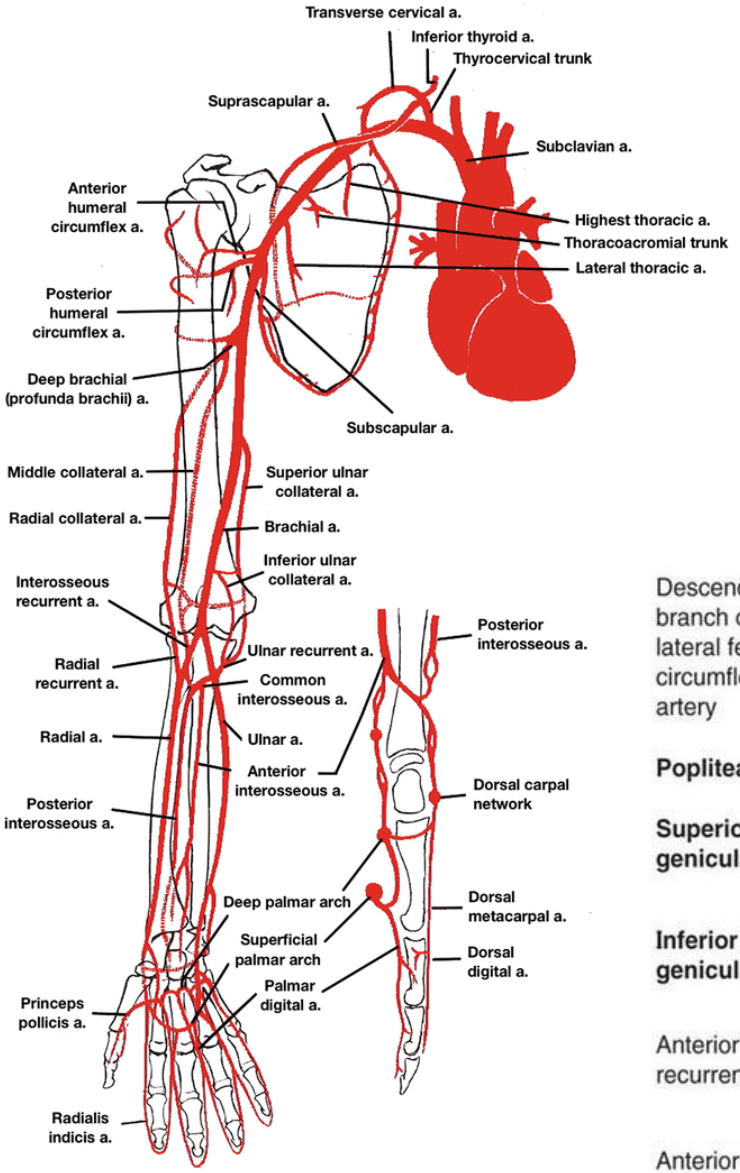

Trochanteric Anastomosis

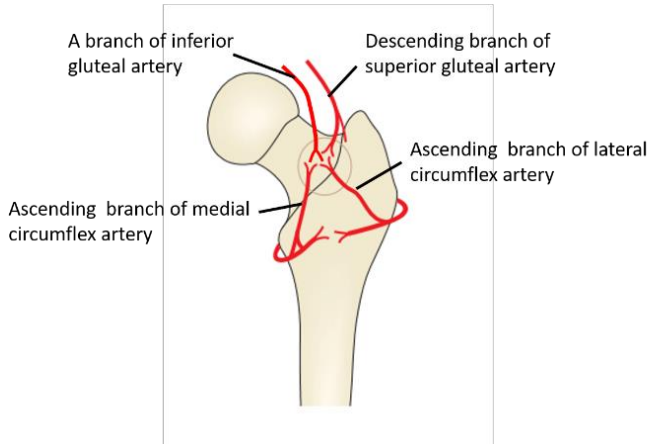

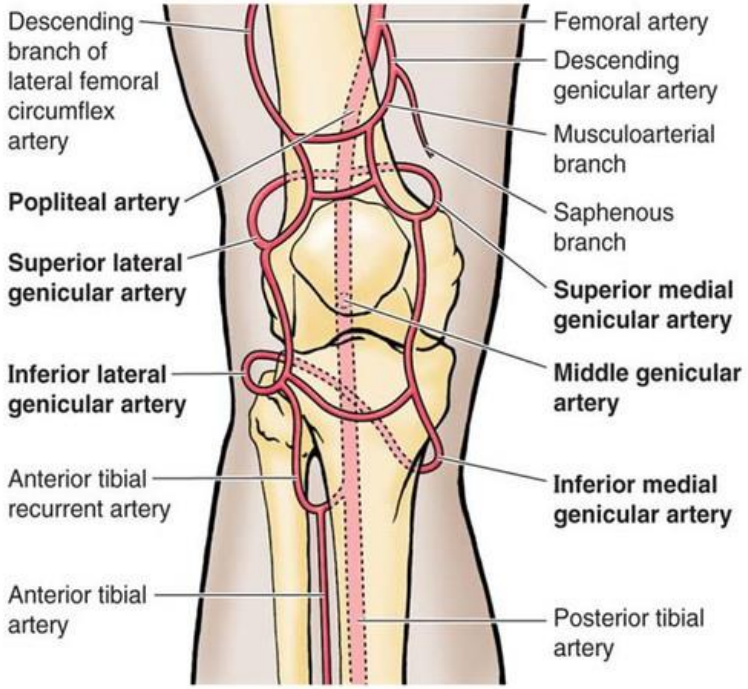

Anterior view

Venous drainage of the body

نفس اسماء الشرايين في عنا اوردة بس في طبعًا exceptions

- Deoxygenated blood returns to the heart via 3 main veins: the **superior and inferior venae cavae** and the **coronary sinus.**

pressure of veins < pressure of arteries

← تصيل لو صار منهم إصابة ما بتجلط تزيف كبير على arteries

- There are two types of veins:

مهم جدًا في سحب الدم

1. **Superficial veins**: beneath the skin

مرافقين لل arteries

2. **Deep veins** : accompany the arteries, some arteries have wo accompanying veins called v=ena comitans; one vein at each side of the artery.

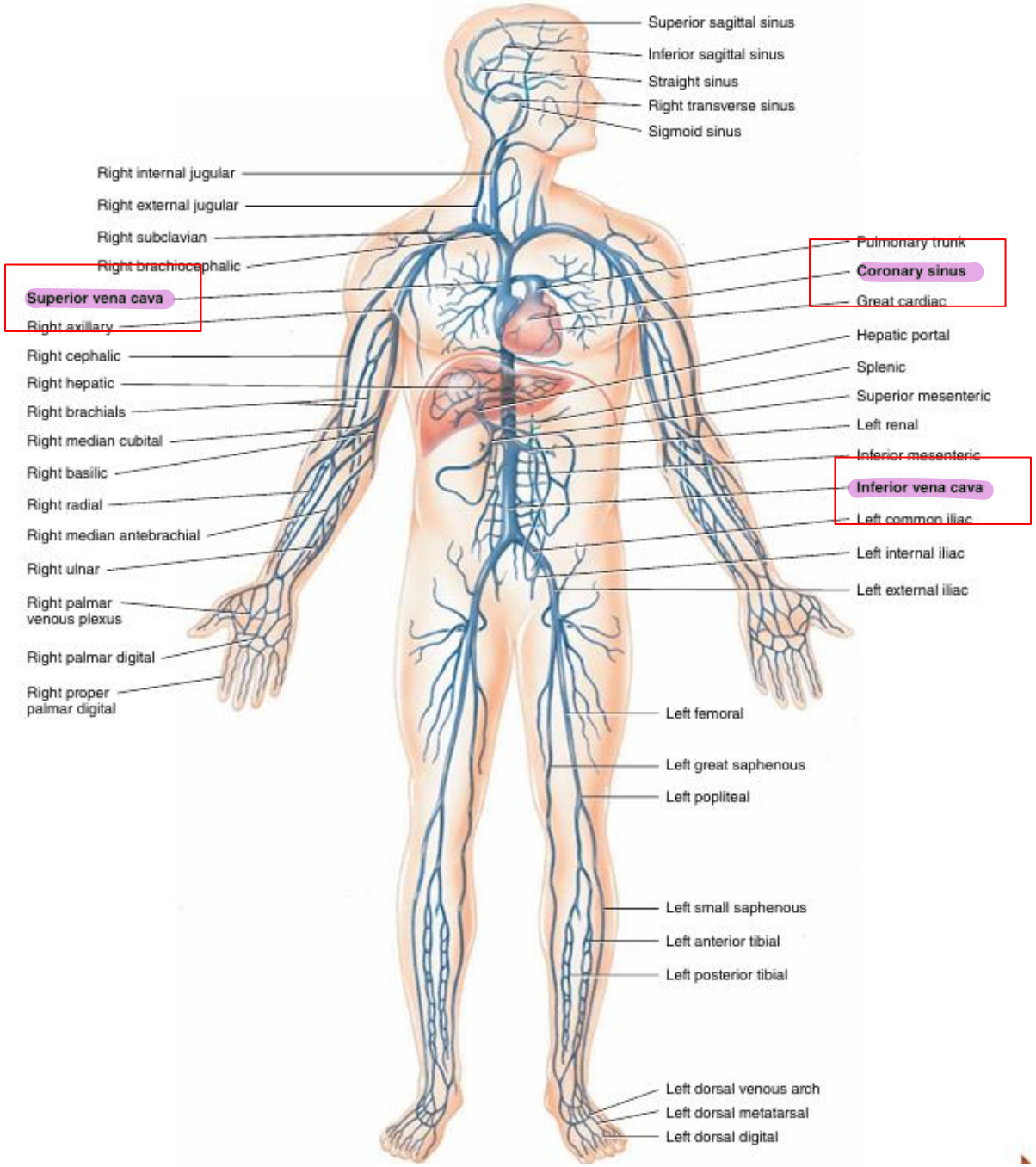

Large venous vessels

- **Superior vena cava** upper limbs

Returns blood to the heart from the tissues **above** the respiratory diaphragm. Formed by the junction of the **left and right brachiocephalic veins.**

- **Inferior vena cava** lower limbs + pelvis + abdomin

Returns blood to the heart from tissues **below** the respiratory diaphragm..

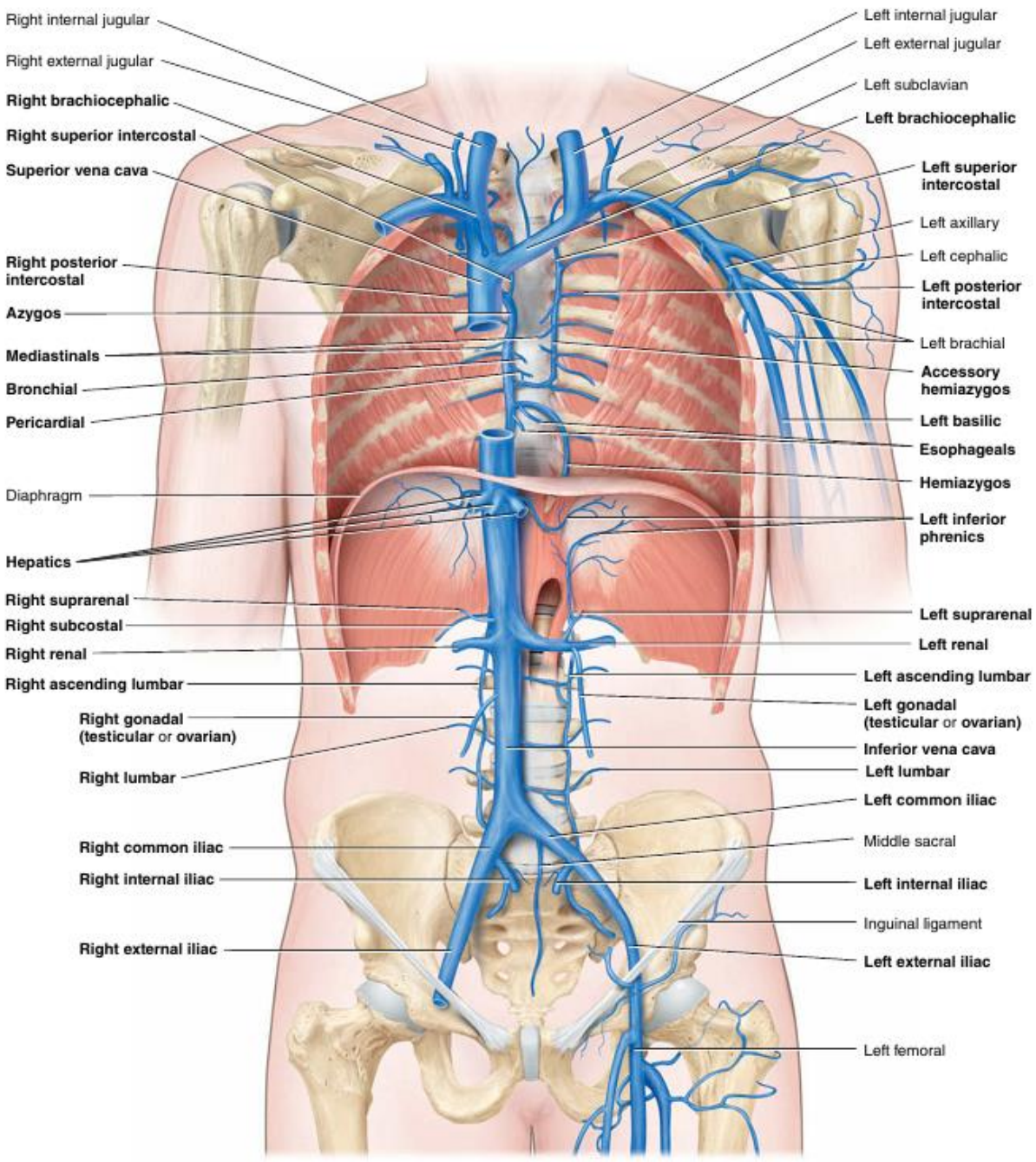

Venous drainage of the upper limb, head and neck

ليش ما عندها صمامات ؟ لانه انا
بدي الدم ينزل بفعل الجاذبية ف
هاي الصمامات رح تمنعهم

هما نوع من veins بكونوا
specialised مكونة من
single layer of cells و
مغطية بغشاء السحايا

- **Dural venous sinuses** are **valveless**
- All drain into the **internal jugular vein** → jugular foramen in skull
- Internal jugular vein joins **subclavian vein** to form **brachiocephalic vein**

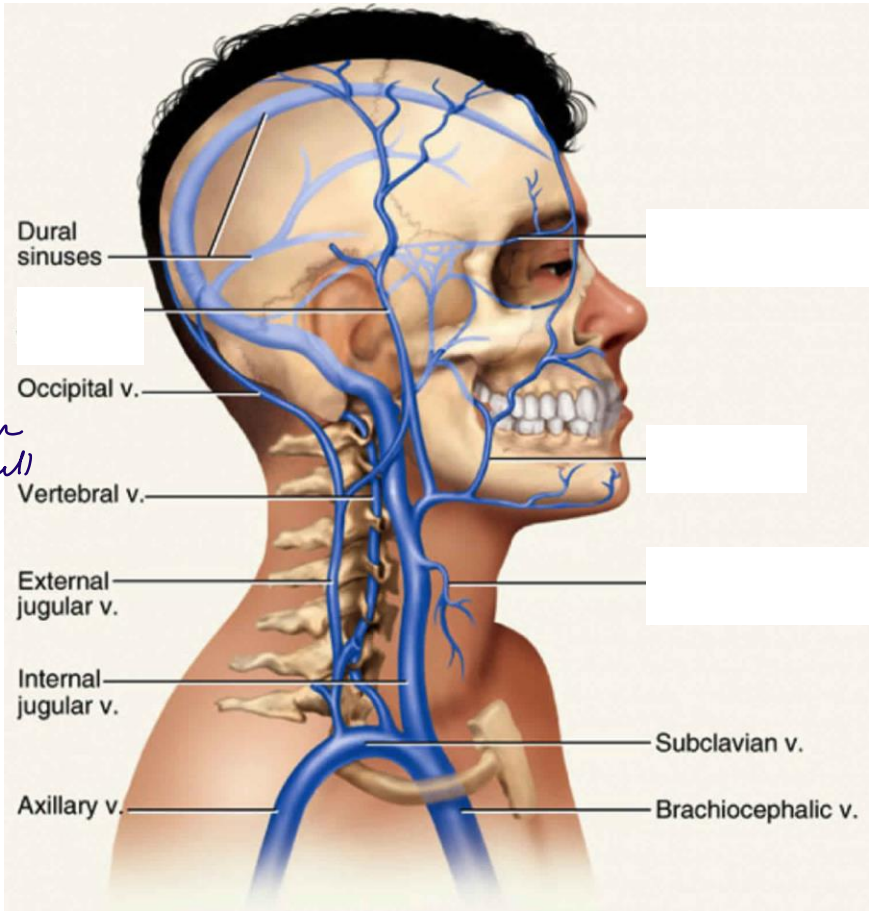

Veins of the head and neck

Venous drainage of the upper limb

They are superficial veins.

- **Cephalic veins** begin on the **lateral** aspect of dorsal venous arch

- **Basilic veins** begin on the **medial** aspects of dorsal venous arch.
- Connected to the cephalic veins anterior to the elbow by the **median cubital veins**

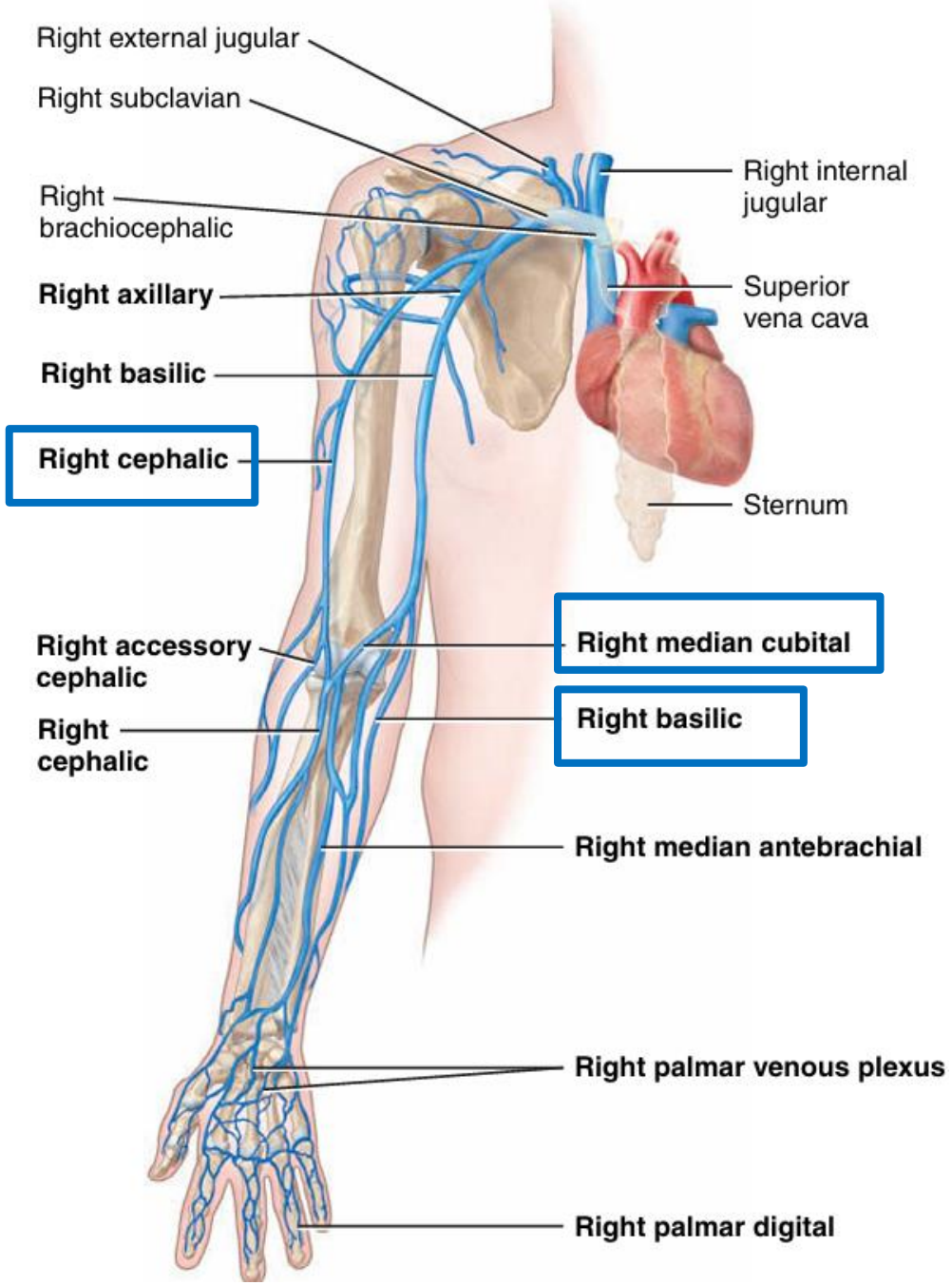

لما بنسحب دم بنور عليه .

The median cubital vein is the most superficial vein in the body and connects the cephalic and basilic veins.

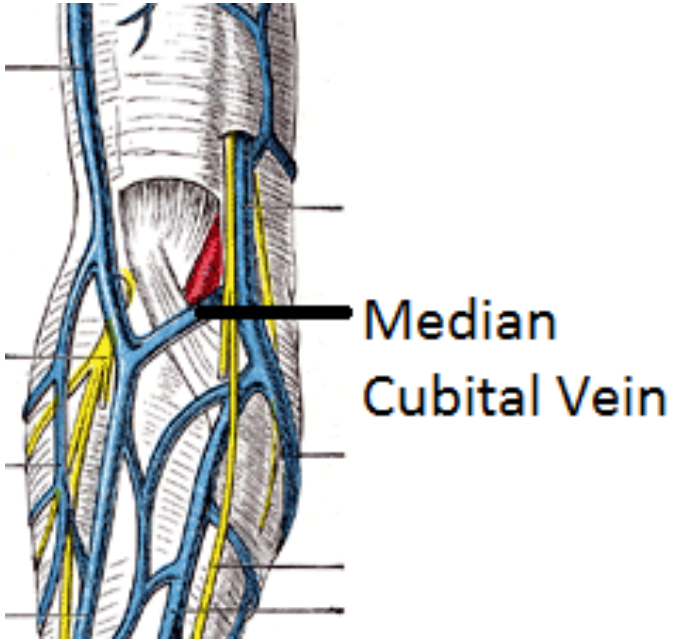

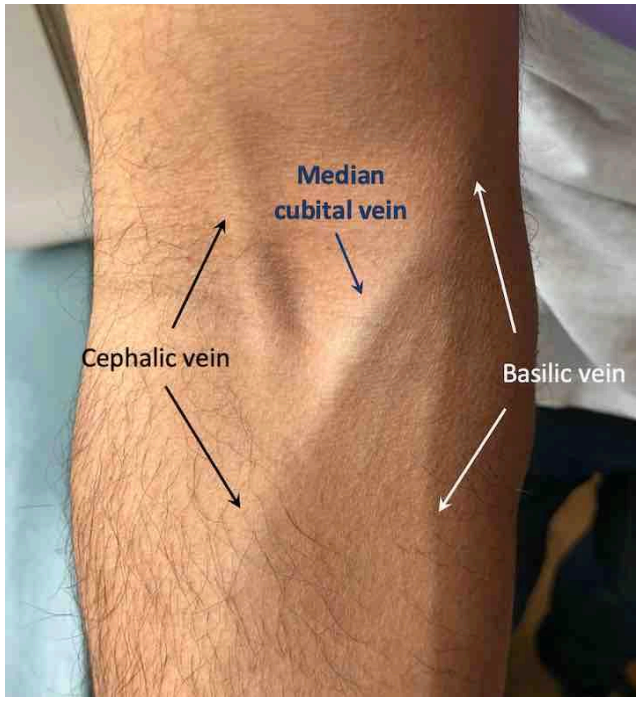

Venous drainage of the lower limb

All veins of the lower limbs have valves.

Great saphenous veins are the longest veins in the body Pass **anterior to the medial malleolus** of the tibia and then superiorly along the **medial** aspect of the leg and thigh

Tibia

Small saphenous veins begin at the **lateral** aspect of the dorsal venous arches of the foot; pass **posterior to the lateral malleolus** of the fibula

Fibula

Clinical notes: Related to Great

- More likely to be subject to **Varicose veins** than other veins in the lower limbs.
- Prolonged administration of intravenous fluids.
- Coronary artery bypass grafting عمليات تصحيح المسار لما يسكر واحد من Coronary artery

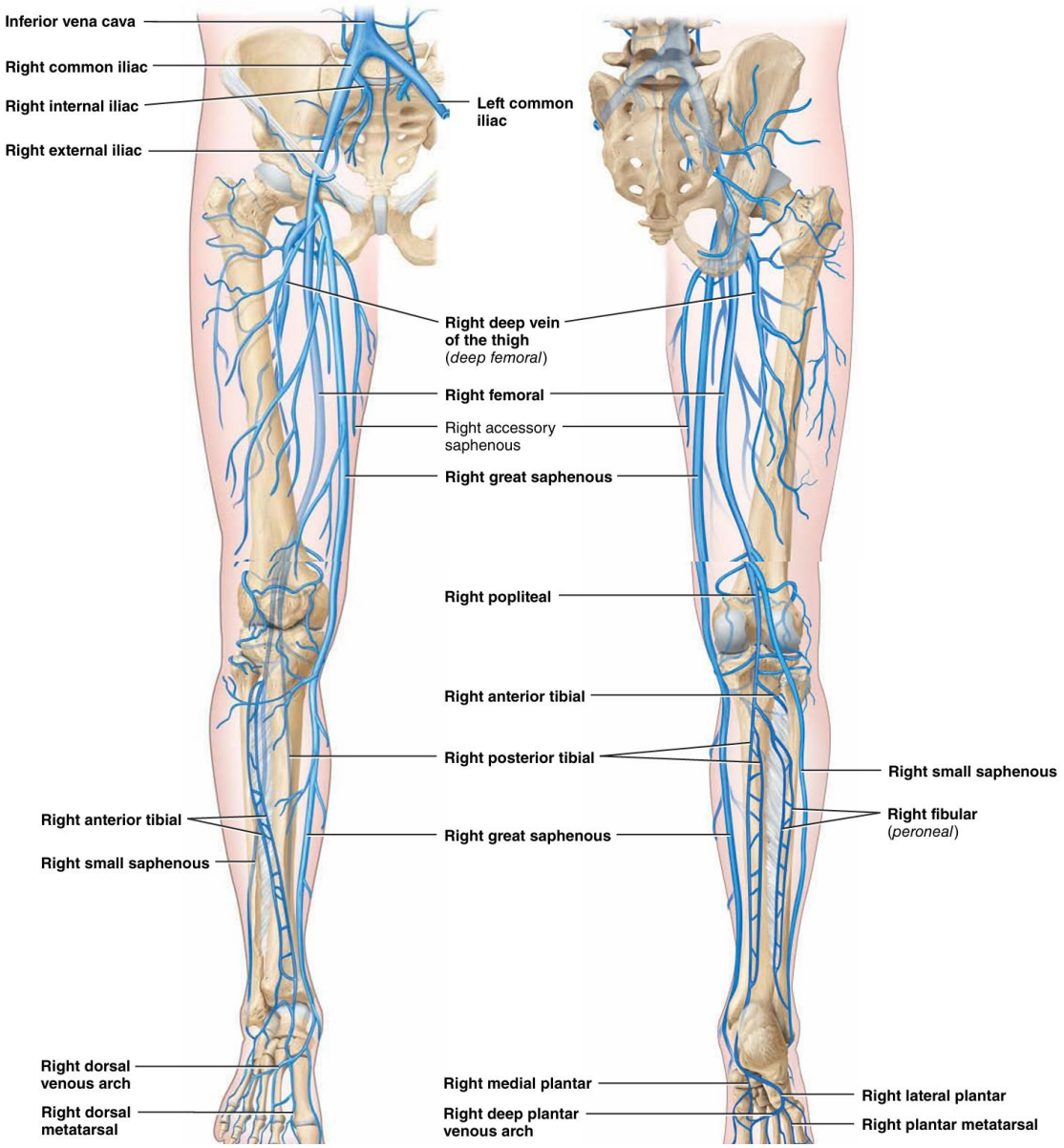

السبب الاخر لانه الاوردة لونها ازرق هو الطول الموجي ف اللون الازرق هو اكثر اشي ببين

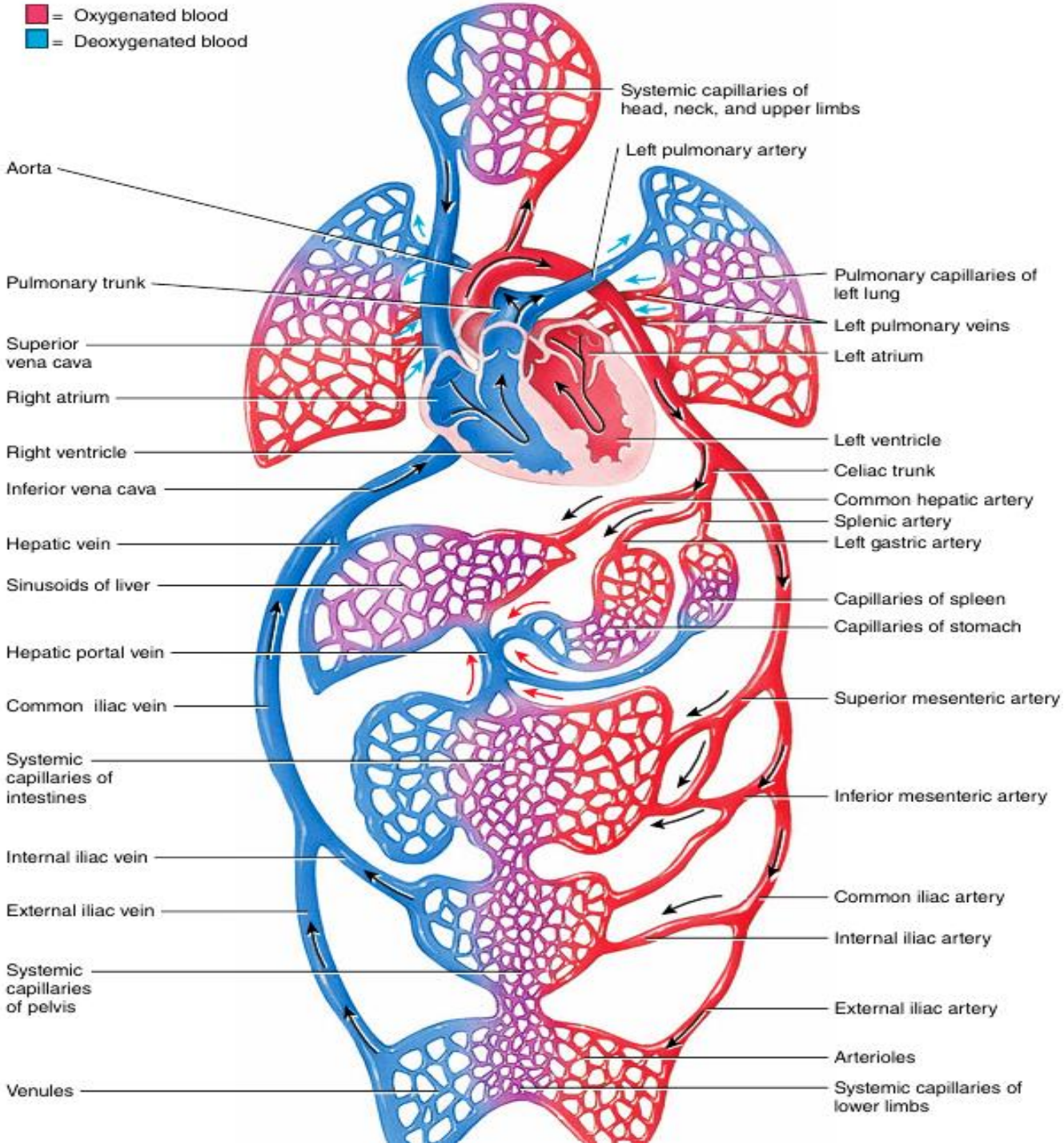
= Oxygenated blood
= Deoxygenated blood
Systemic capillaries of head, neck, and upper limbs
Left pulmonary artery
Aorta
Pulmonary trunk
Pulmonary capillaries of left lung
Left pulmonary veins
Superior vena cava
Left atrium
Right atrium
Left ventricle
Right ventricle
Celiac trunk
Inferior vena cava
Common hepatic artery
Splenic artery
Hepatic vein
Left gastric artery
Sinusoids of liver
Capillaries of spleen
Capillaries of stomach
Hepatic portal vein
Superior mesenteric artery
Common iliac vein
Systemic capillaries of intestines
Inferior mesenteric artery
Internal iliac vein
Common iliac artery
External iliac vein
Internal iliac artery
Systemic capillaries of pelvis
External iliac artery
Arterioles
Venules
Systemic capillaries of lower limbs

المحاضرة L

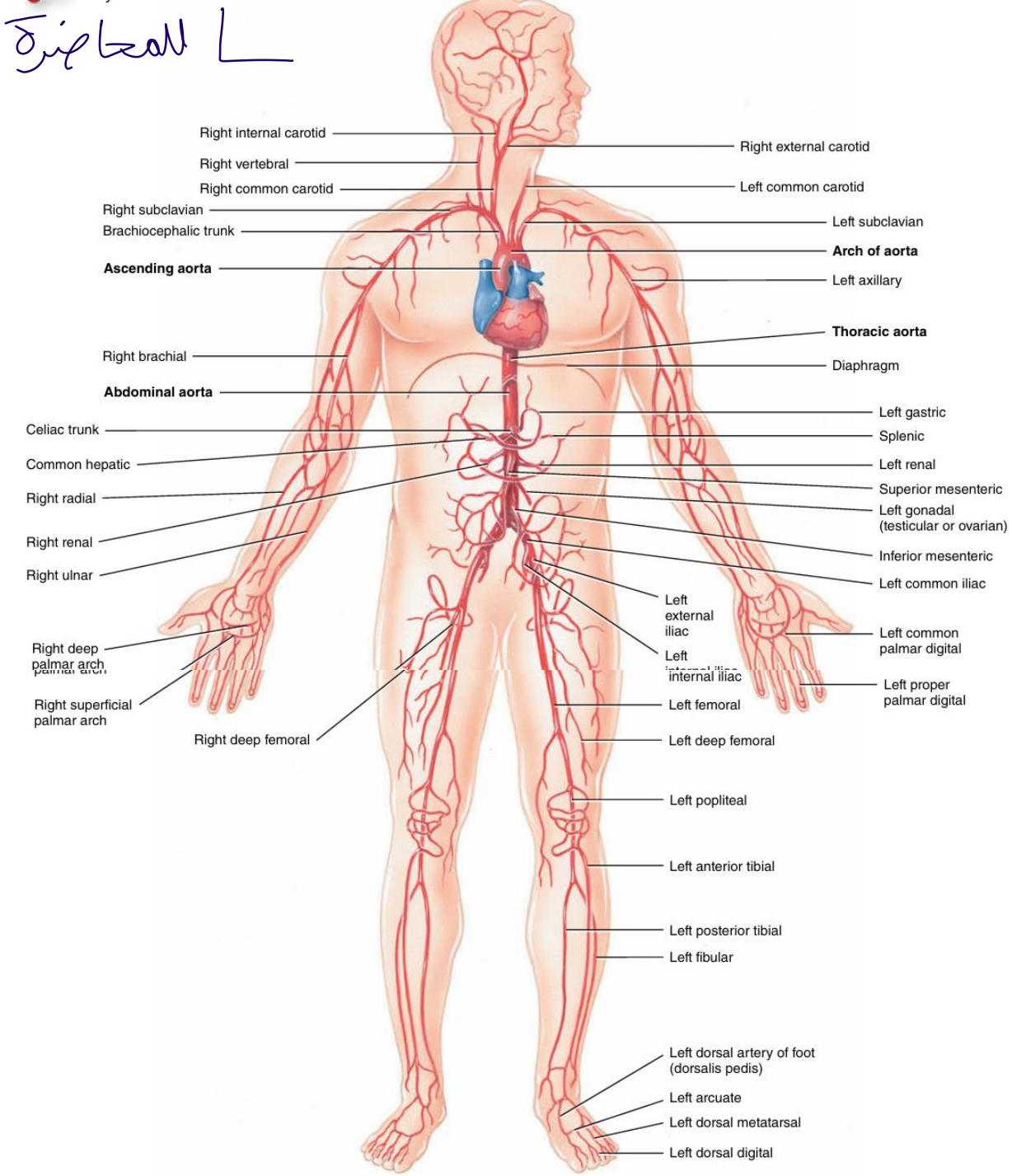
Right internal carotid
Right vertebral
Right common carotid
Right subclavian
Brachiocephalic trunk
Ascending aorta
Right brachial
Abdominal aorta
Celiac trunk
Common hepatic
Right radial
Right renal
Right ulnar
Right deep palmar arch
Right superficial palmar arch
Right deep femoral
Right external carotid
Left common carotid
Left subclavian
Arch of aorta
Left axillary
Thoracic aorta
Diaphragm
Left gastric
Splenic
Left renal
Superior mesenteric
Left gonadal (testicular or ovarian)
Inferior mesenteric
Left common iliac
Left external iliac
Left internal iliac
Left common palmar digital
Left proper palmar digital
Left femoral
Left deep femoral
Left popliteal
Left anterior tibial
Left posterior tibial
Left fibular
Left dorsal artery of foot (dorsalis pedis)
Left arcuate
Left dorsal metatarsal
Left dorsal digital

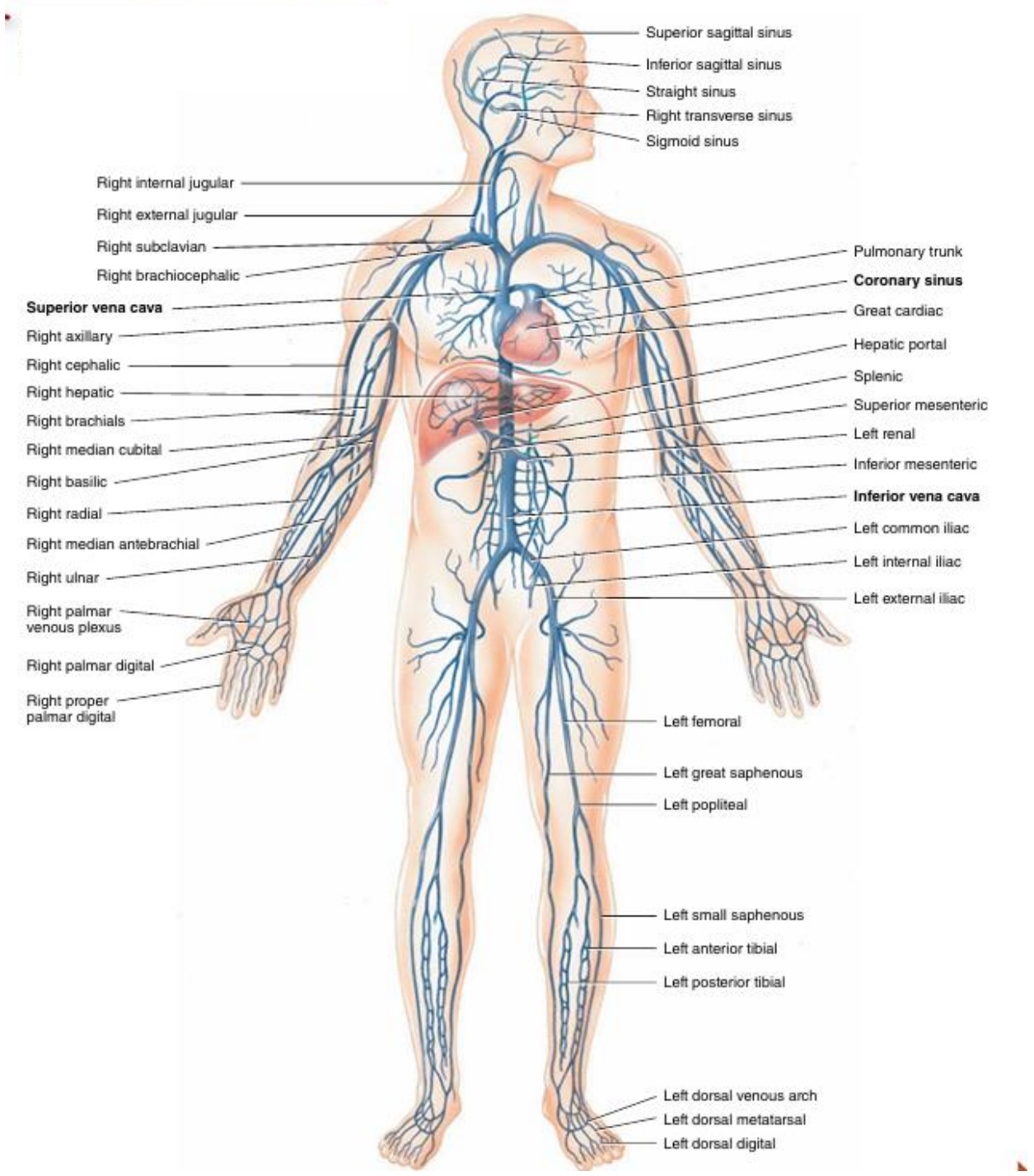
Superior sagittal sinus
Inferior sagittal sinus
Straight sinus
Right transverse sinus
Sigmoid sinus
Right internal jugular
Right external jugular
Right subclavian
Right brachiocephalic
Superior vena cava
Right axillary
Right cephalic
Right hepatic
Right brachials
Right median cubital
Right basilic
Right radial
Right median antebrachial
Right ulnar
Right palmar venous plexus
Right palmar digital
Right proper palmar digital
Pulmonary trunk
Coronary sinus
Great cardiac
Hepatic portal
Splenic
Superior mesenteric
Left renal
Inferior mesenteric
Inferior vena cava
Left common iliac
Left internal iliac
Left external iliac
Left femoral
Left great saphenous
Left popliteal
Left small saphenous
Left anterior tibial
Left posterior tibial
Left dorsal venous arch
Left dorsal metatarsal
Left dorsal digital

- Thank you!