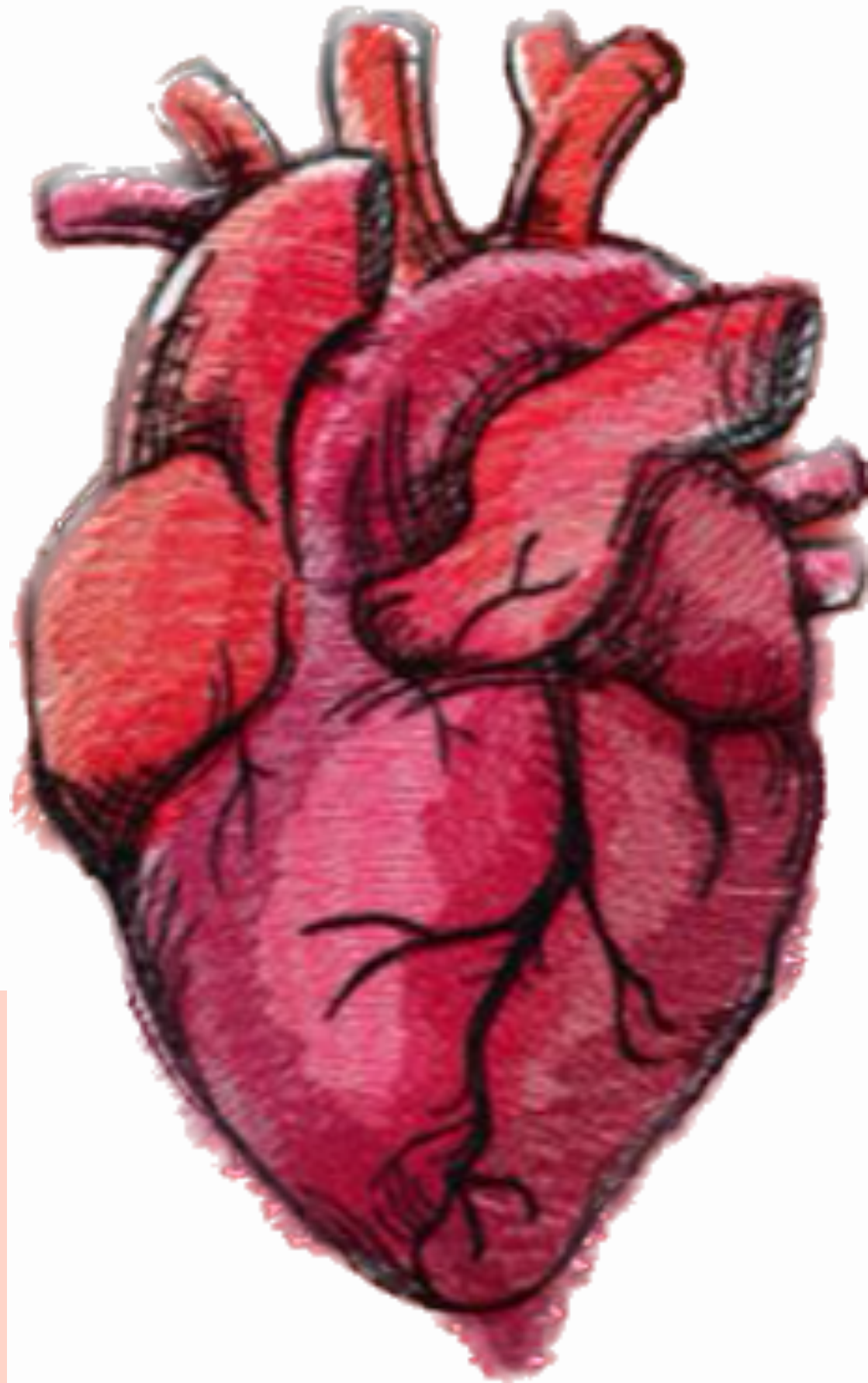

CARDIOVASCULAR SYSTEM

SUBJECT : Anatomy

LEC NO. : Lab 1

DONE BY : Mahmoud Al Qusairi

وَقُلْ رَبِّ زِدْنِي عِلْمًا



SCAN ME!

Practical (1)
Anatomy of Heart

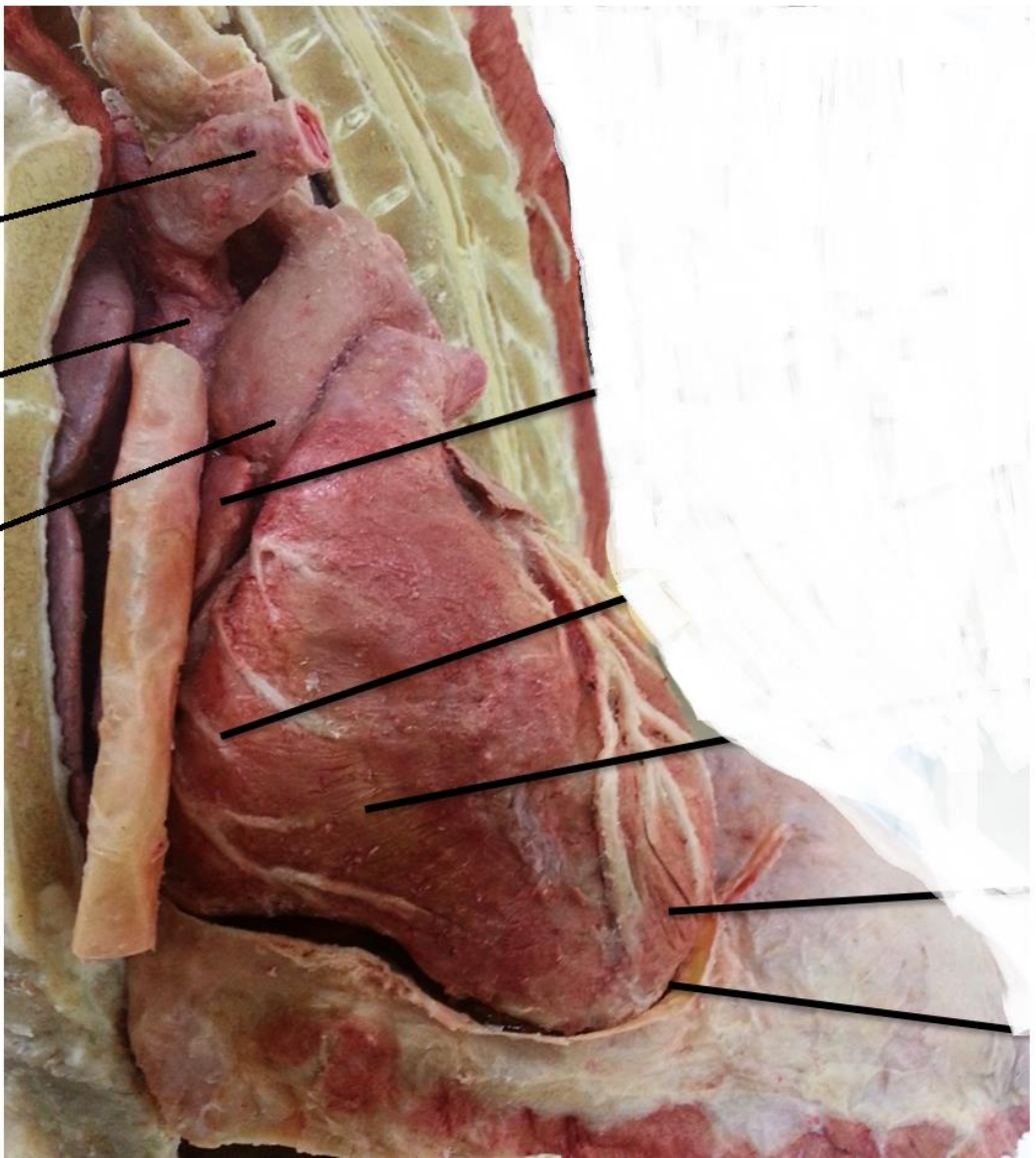Dr. Amany Swilam

← هذا Branch من SVC

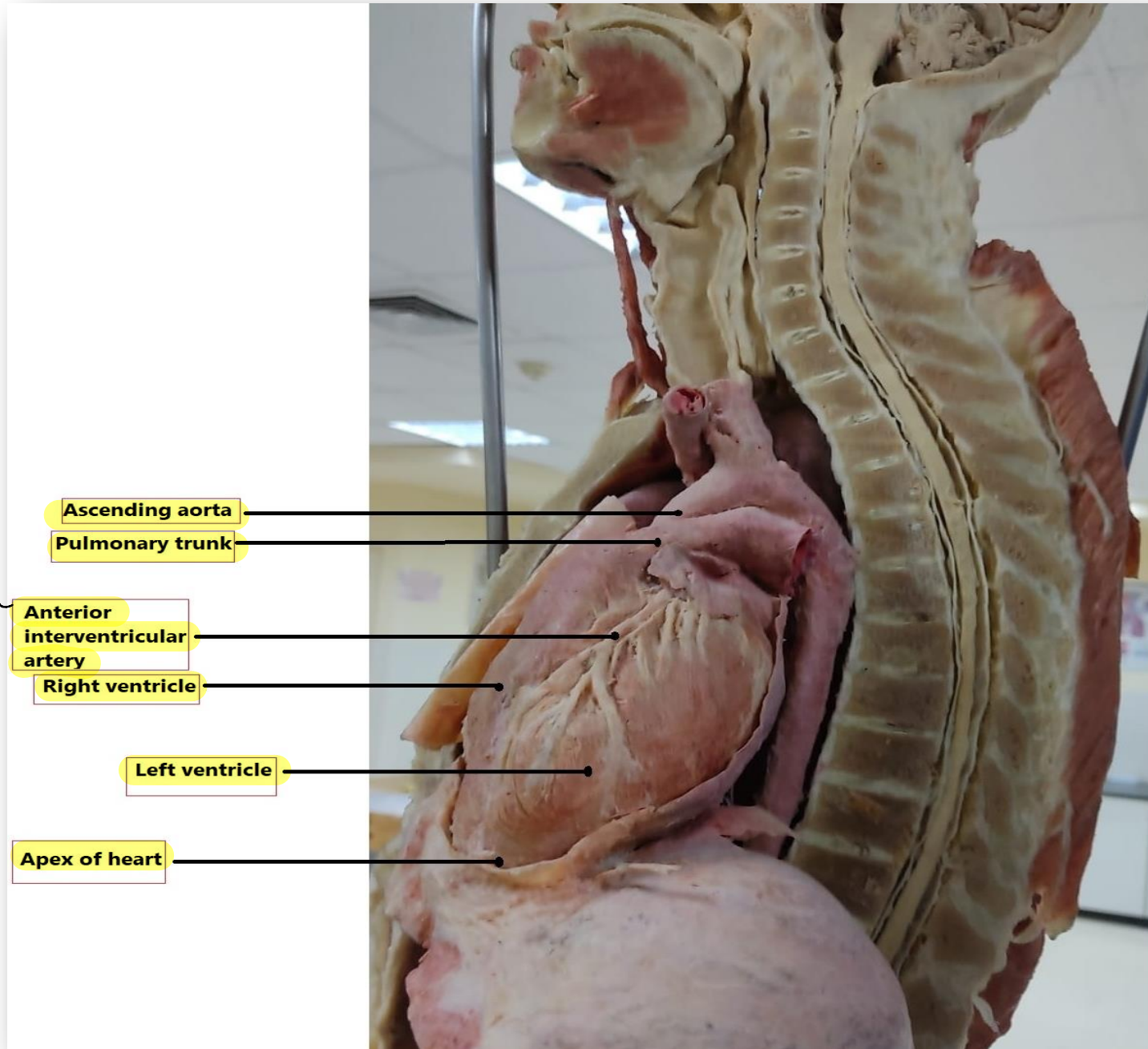
**Left
brachiocephalic
vein**

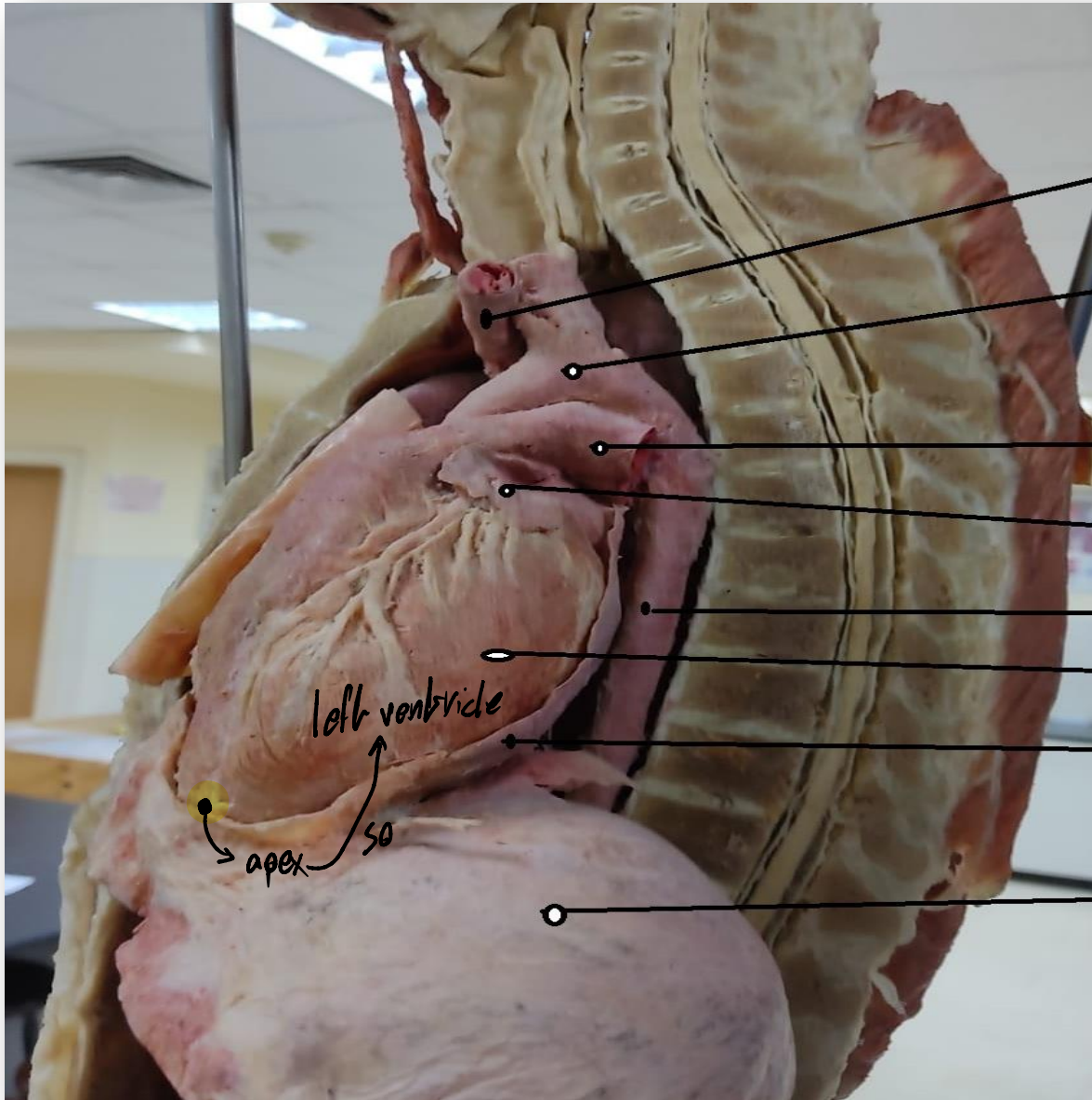
SVC

**Ascending
aorta**



بيكون ماشي في anterior
interventricular
septum من depression)groove
الي بين two ventricles (





Left brachiocephalic vein

Arch of aorta

Left pulmonary artery

Left auricle

Descending thoracic aorta

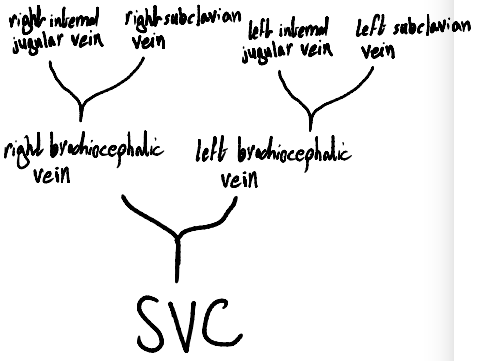
Left ventricle

Fibrous pericardium

Diaphragm

ال pulmonary tract يطلع من ال right ventricle ويينقسم الى right and left pulmonary arteries

موجود في posterior mediastinum



جايب من

right side of neck, head and brain

right internal jugular vein

right من venue drainage جايب

upper limb

right subclavian vein

right brachiocephalic vein

SVC

right auricle

right ventricle

left brachiocephalic vein

right brachiocephalic artery

جايب من

left side of neck, head and brain

left internal jugular vein

left subclavian vein

left subclavian artery

left common carotid artery

left pulmonary artery

left auricle

left ventricle

apex

arch of aorta

ascending aorta

pulmonary trunk

IVC

Anterior interventricular artery

Anterior interventricular groove

diaphragm

جايب من venue drainage left من upper limb

Arch of aorta* supply upper part of the body

Left subclavian* supply left upper limb

Left common carotid * supply left side of neck, head and brain ***

Right brachiocephalic (Innominate artery) branches to:

Right subclavian* supply right upper limb

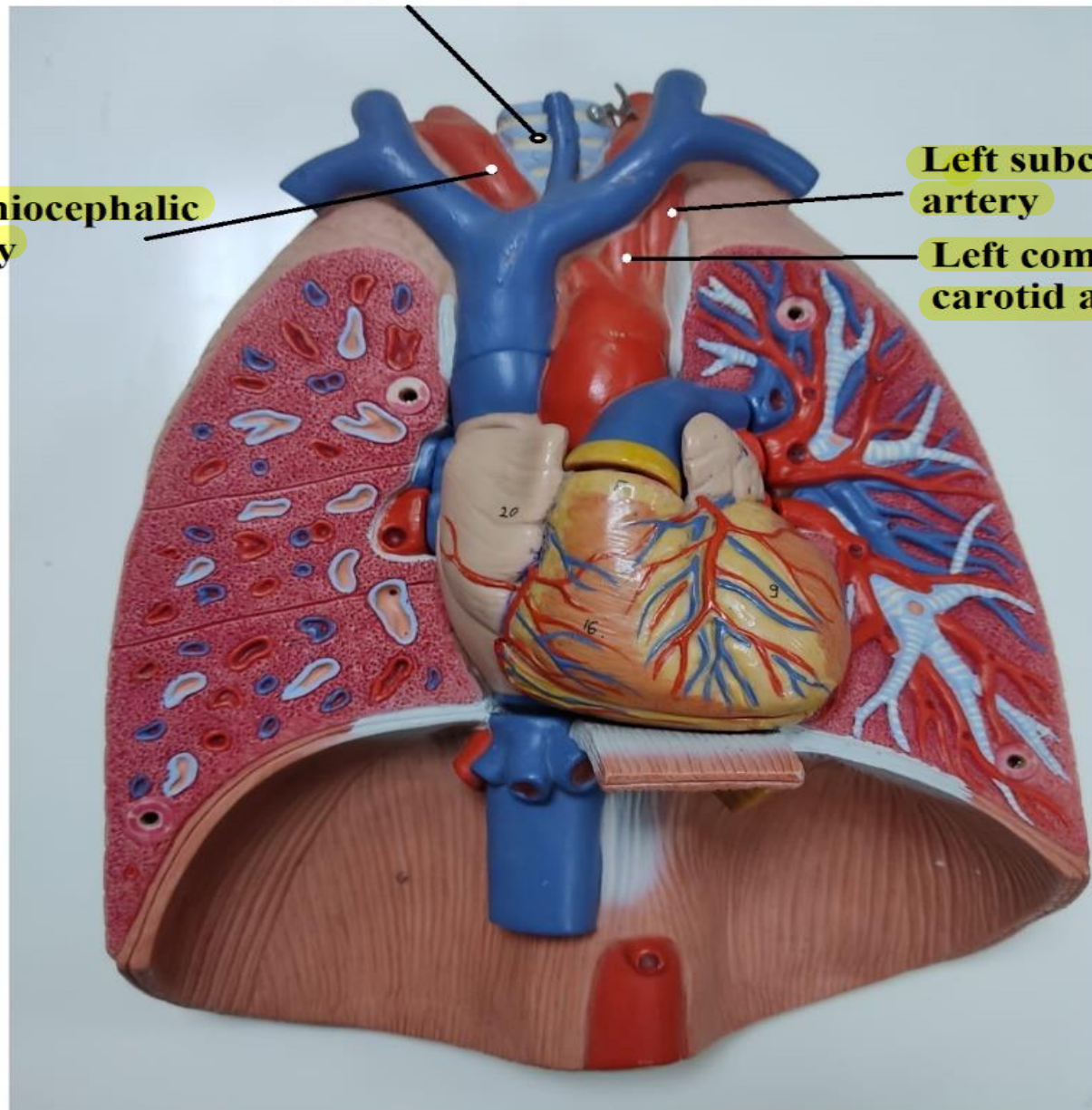
Right common carotid * supply right side of neck, head and brain

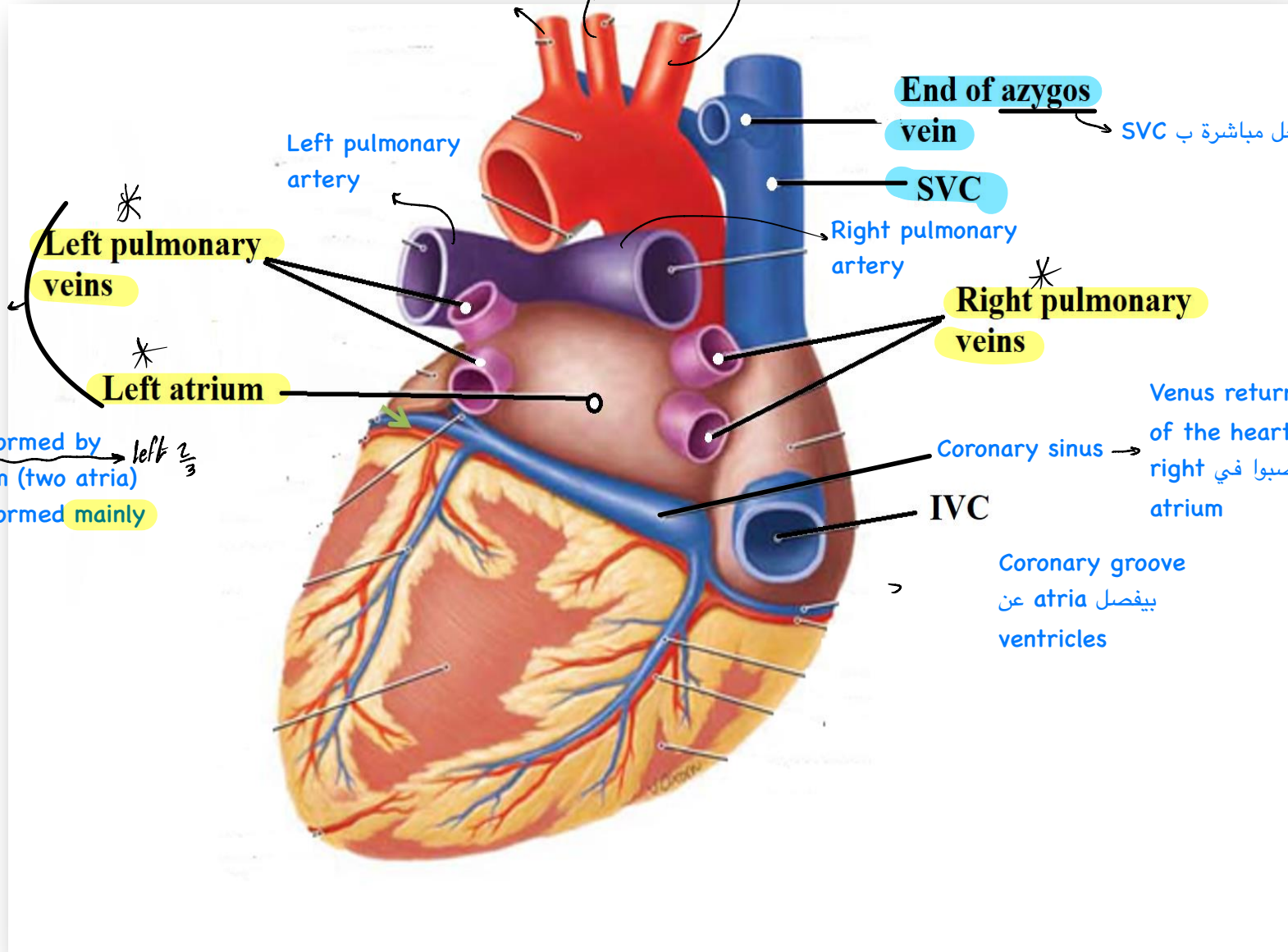
Trachea

**brachiocephalic
artery**

**Left subclavian
artery**

**Left common
carotid artery**





So, it's posterior view

Left pulmonary veins

Left atrium

End of azygos vein

SVC

Right pulmonary veins

Coronary sinus

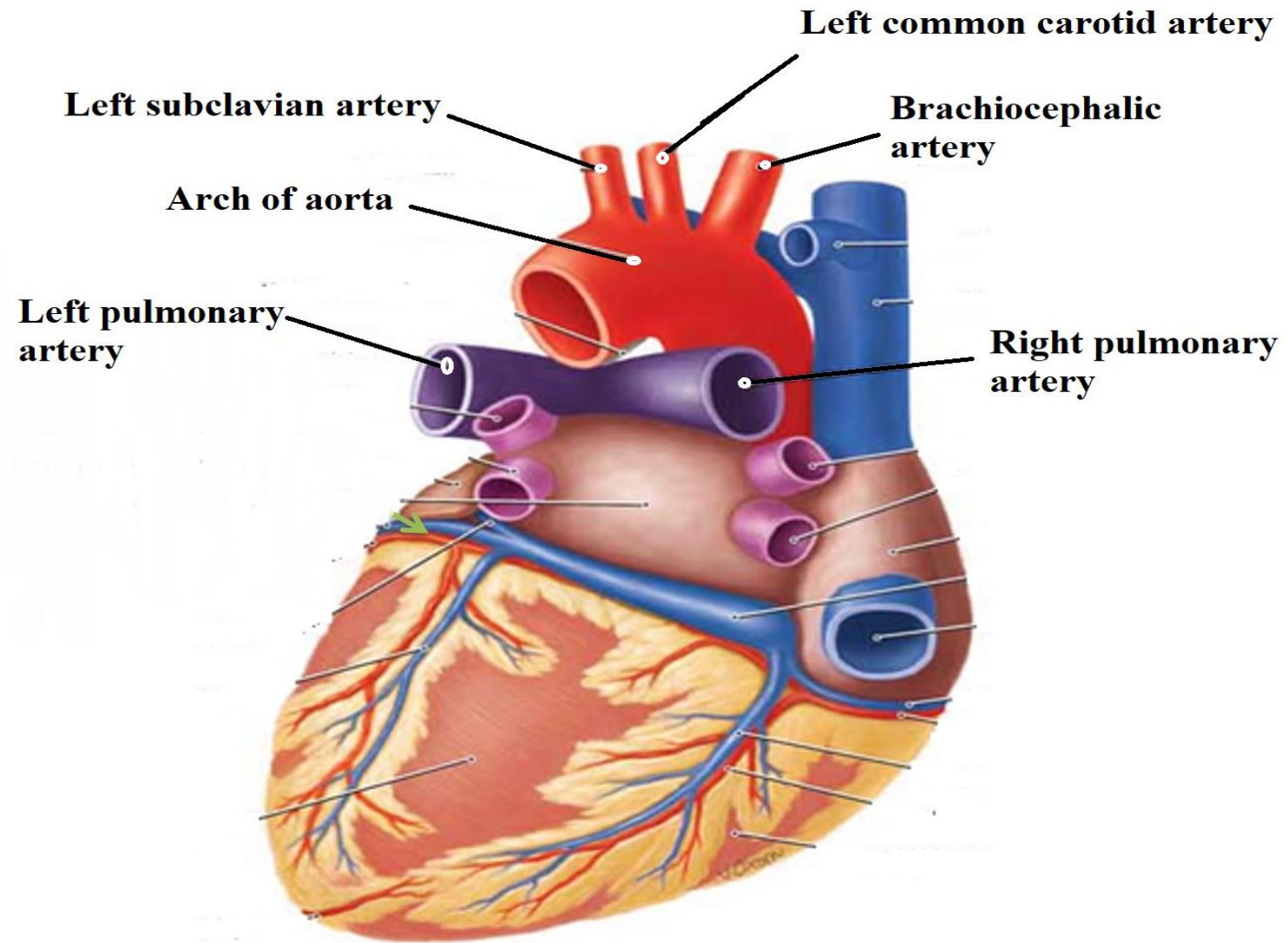
IVC

Coronary groove
بيفصل atria عن ventricles

داخل مباشرة ب SVC

شاييل ال Venus returns of the heart
عشان يصبوا في right atrium

right $\frac{1}{3}$ ← Base of the heart formed by right and left atrium (two atria)
left $\frac{2}{3}$ → Base of the heart formed mainly by left atrium



Ascending aorta

Pulmonaru trunk

Tricuspid valve

Rough part

Crista terminalis

العlevation الفاصل بين
smooth part and
rough part

Smooth part

Opening of SVC
يحتوي على valve لأن ال
Venus return of SVC
ماشني antigravity

هذا ال right atrium لأنه ال SVC فاتح فوق
و IVC فاتح تحت

Coronary sinus

Opening of IVC
لا يحتوي على valve لأن ال
Venus return
ماشني مع gravity

Crista terminalis

Rough part

Smooth part

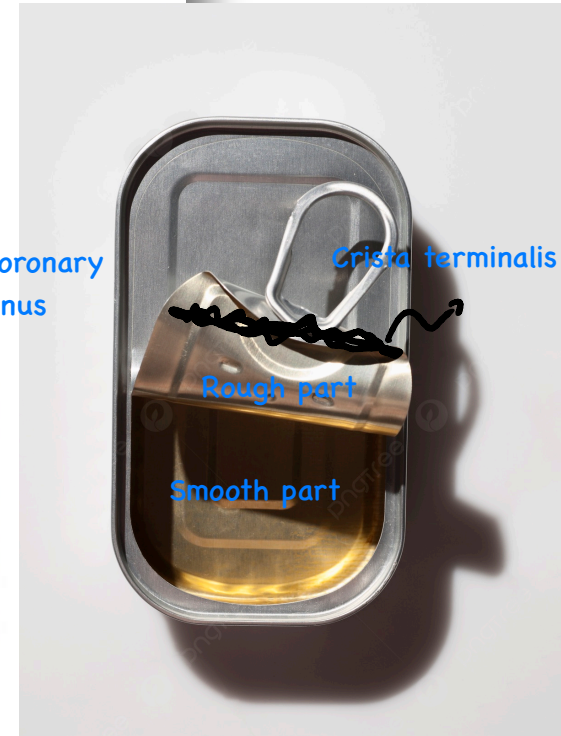Fossa ovalis is a
depressed structure
(remnant of an interatrial
opening, the foramen ovale,)

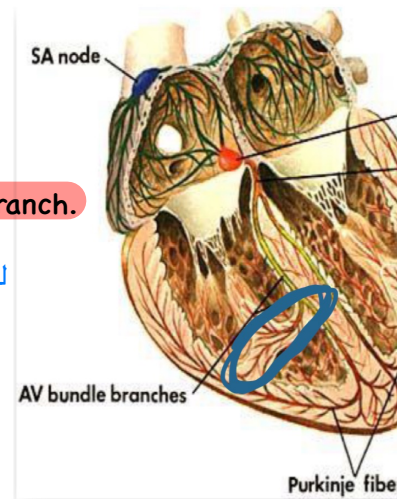
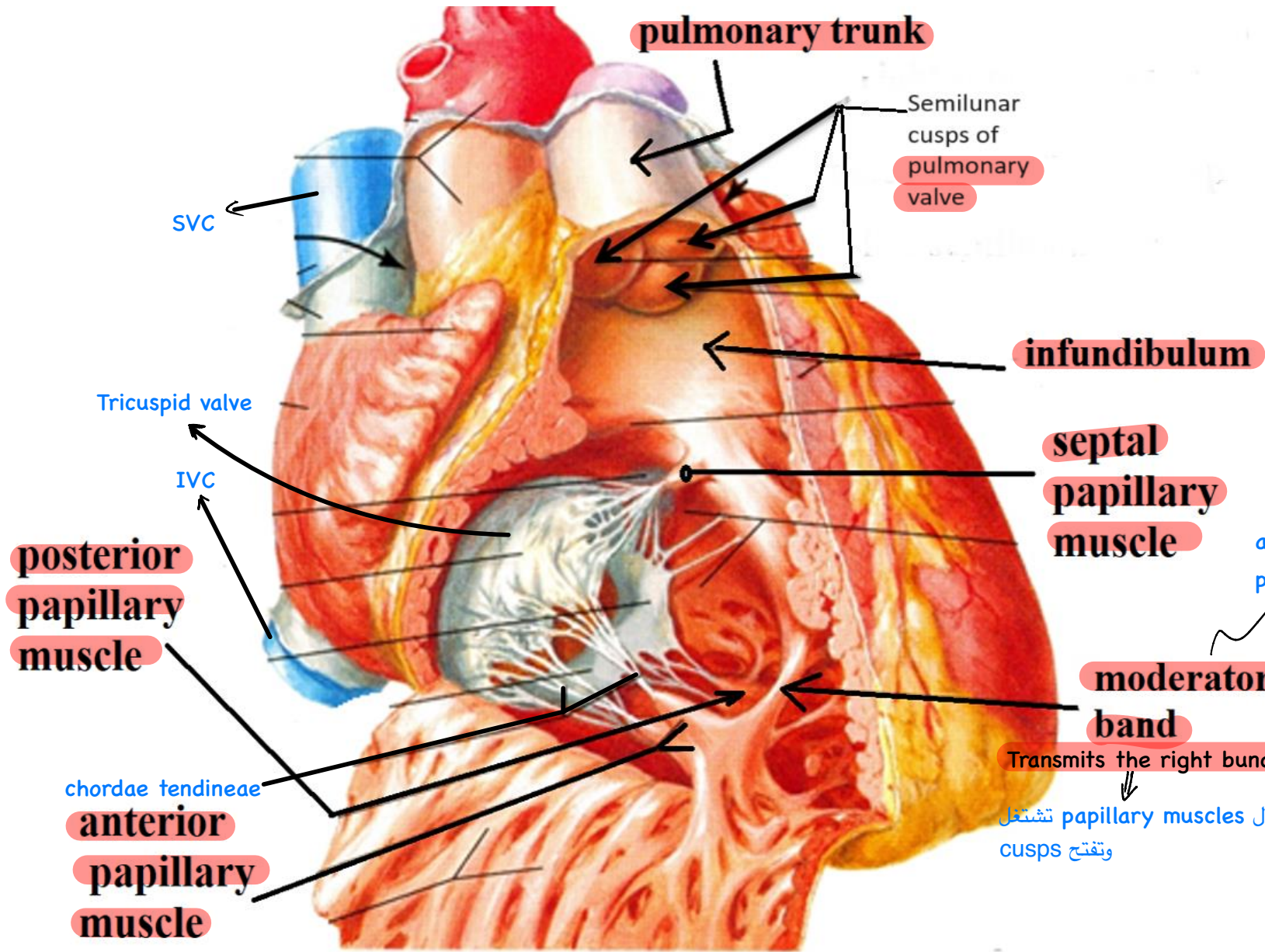
وصله بين ال
right and left atria
ففي fetus

ال muscles الموجوده في atria اسمها
musculi pectinati (pectinate muscle)

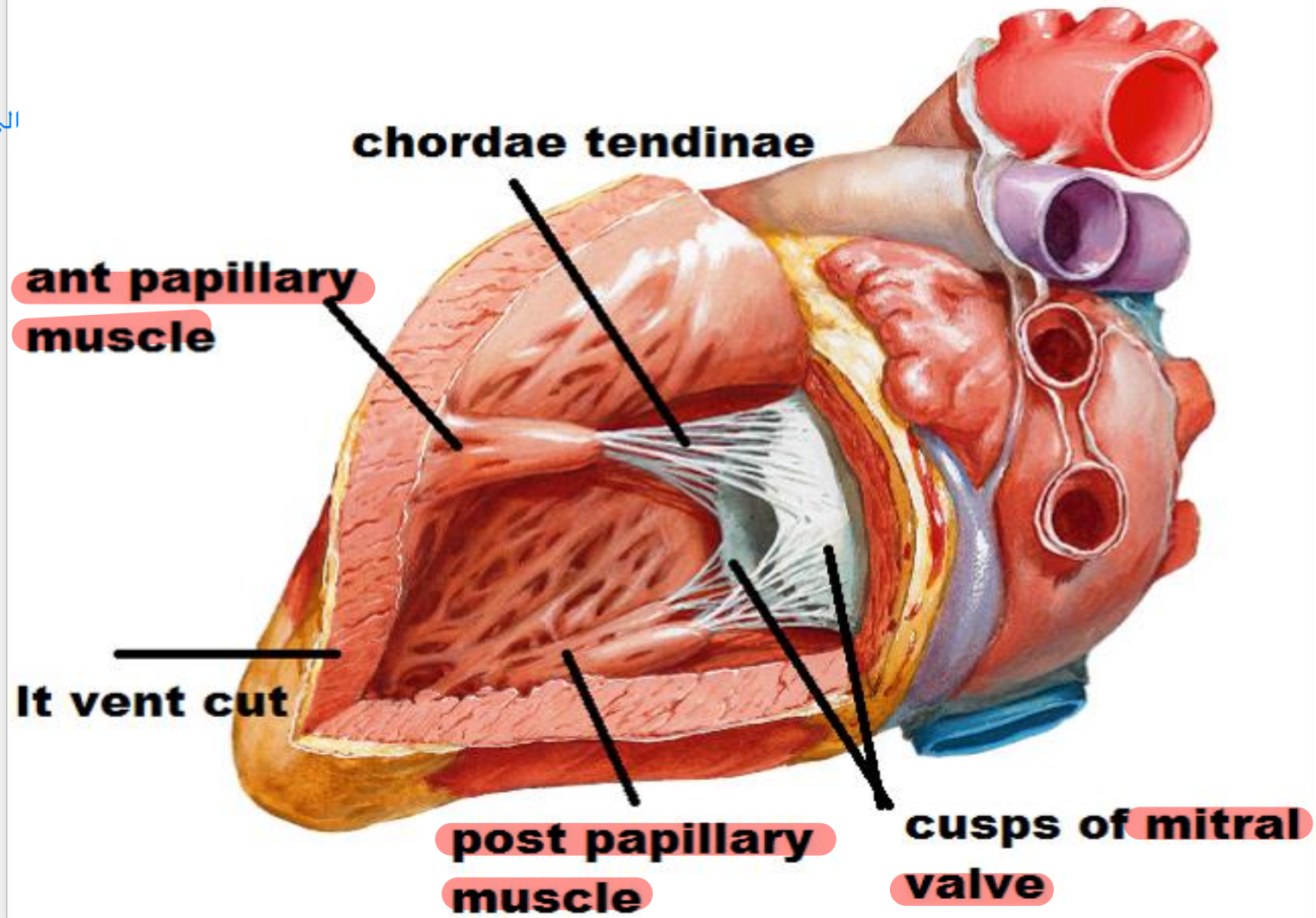
ال muscles الموجوده في ventricles اسمها
trabeculae carneae

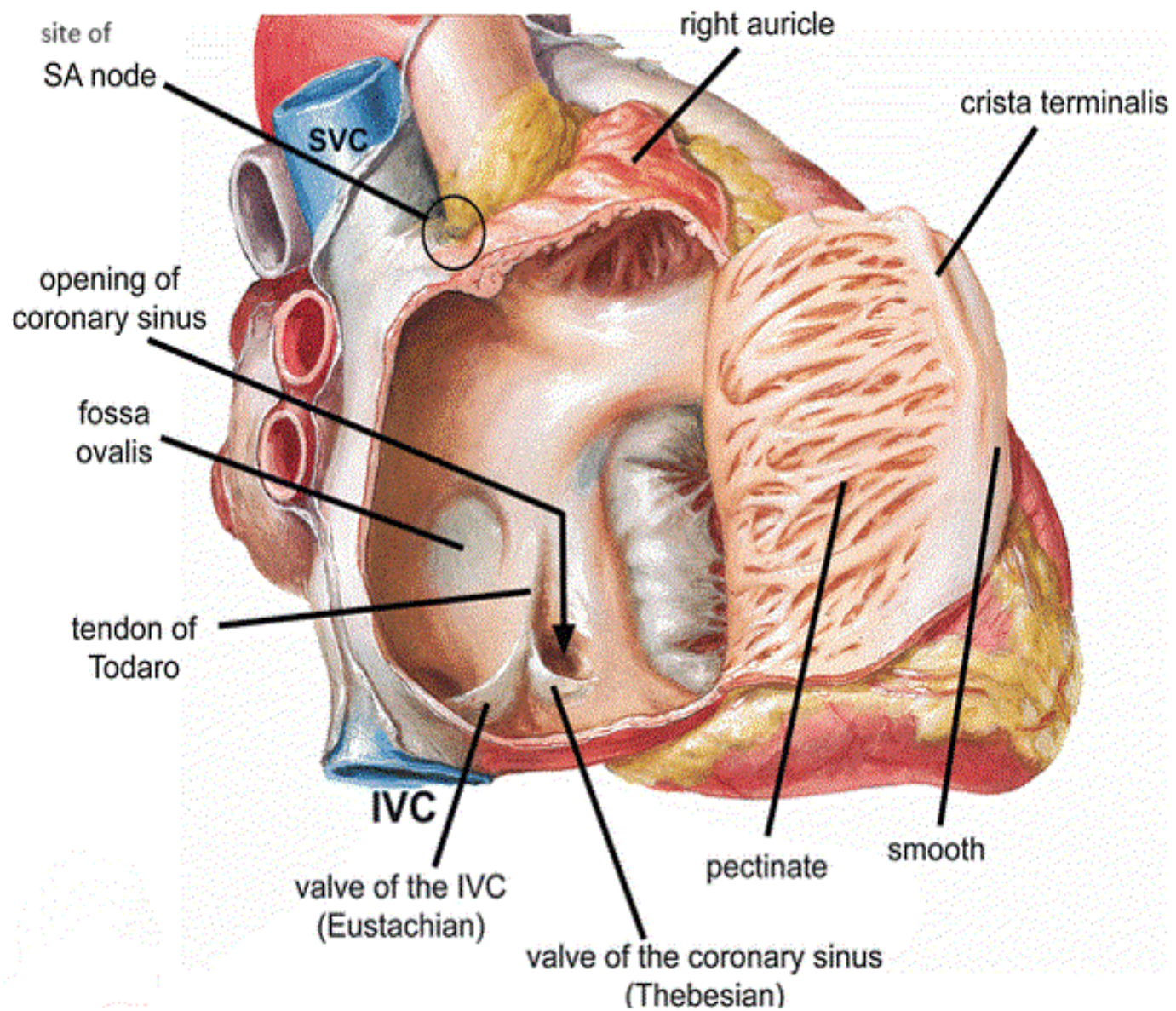
ال impression من جهة ال right atrium
وال projection من جهة ال left atrium

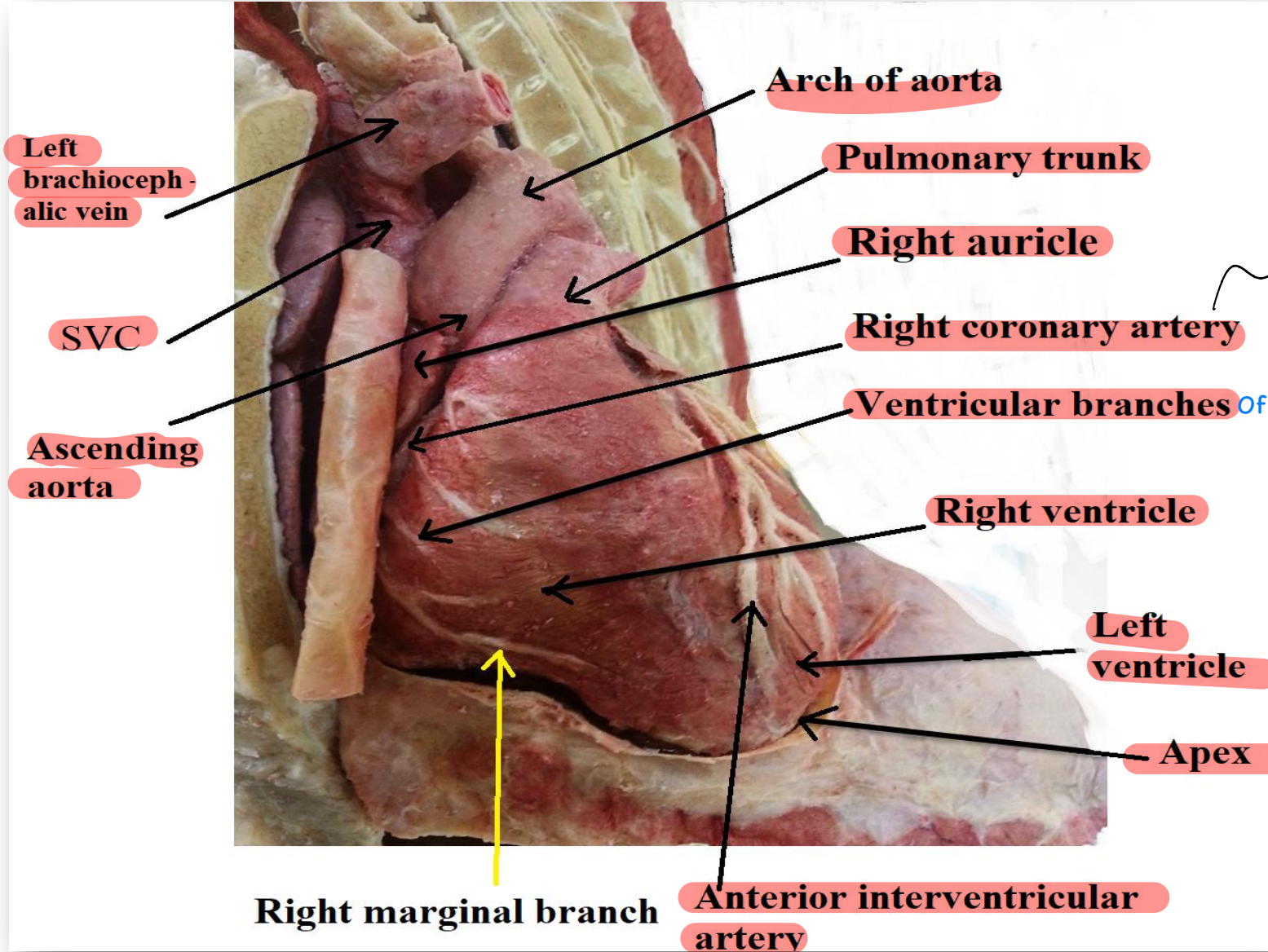




Smooth part
vestibule الي عند opening of aorta اسمه



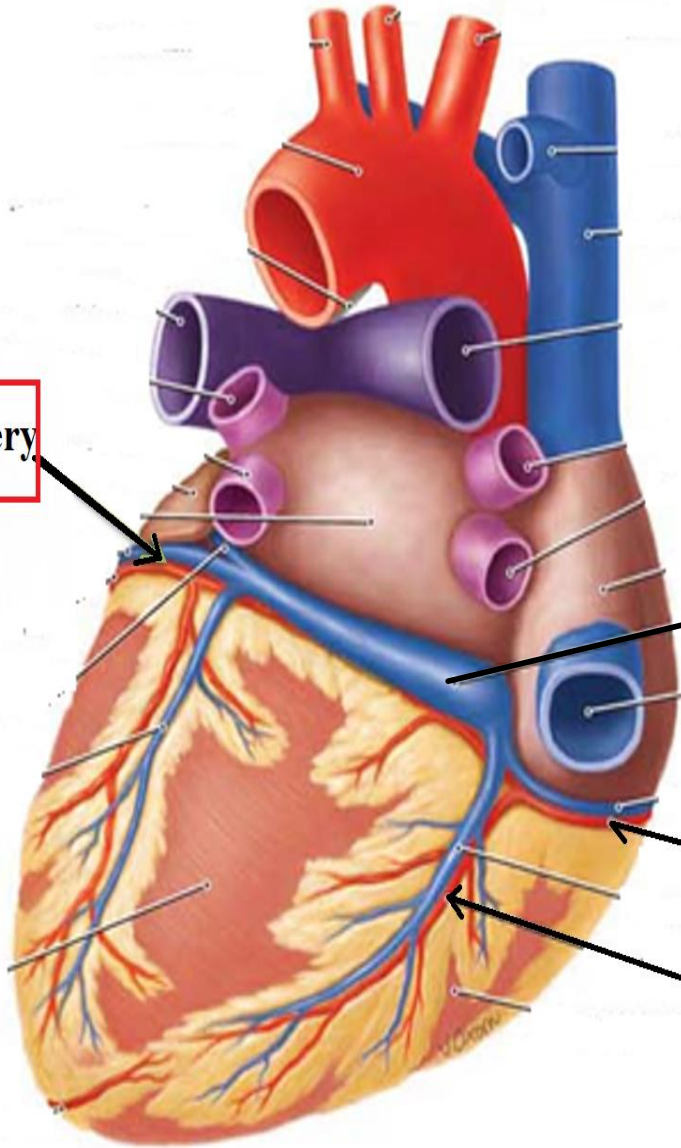




right ventricle and ما بين
right auricle
ascending aorta بيكون طالع من

Of right coronary artery

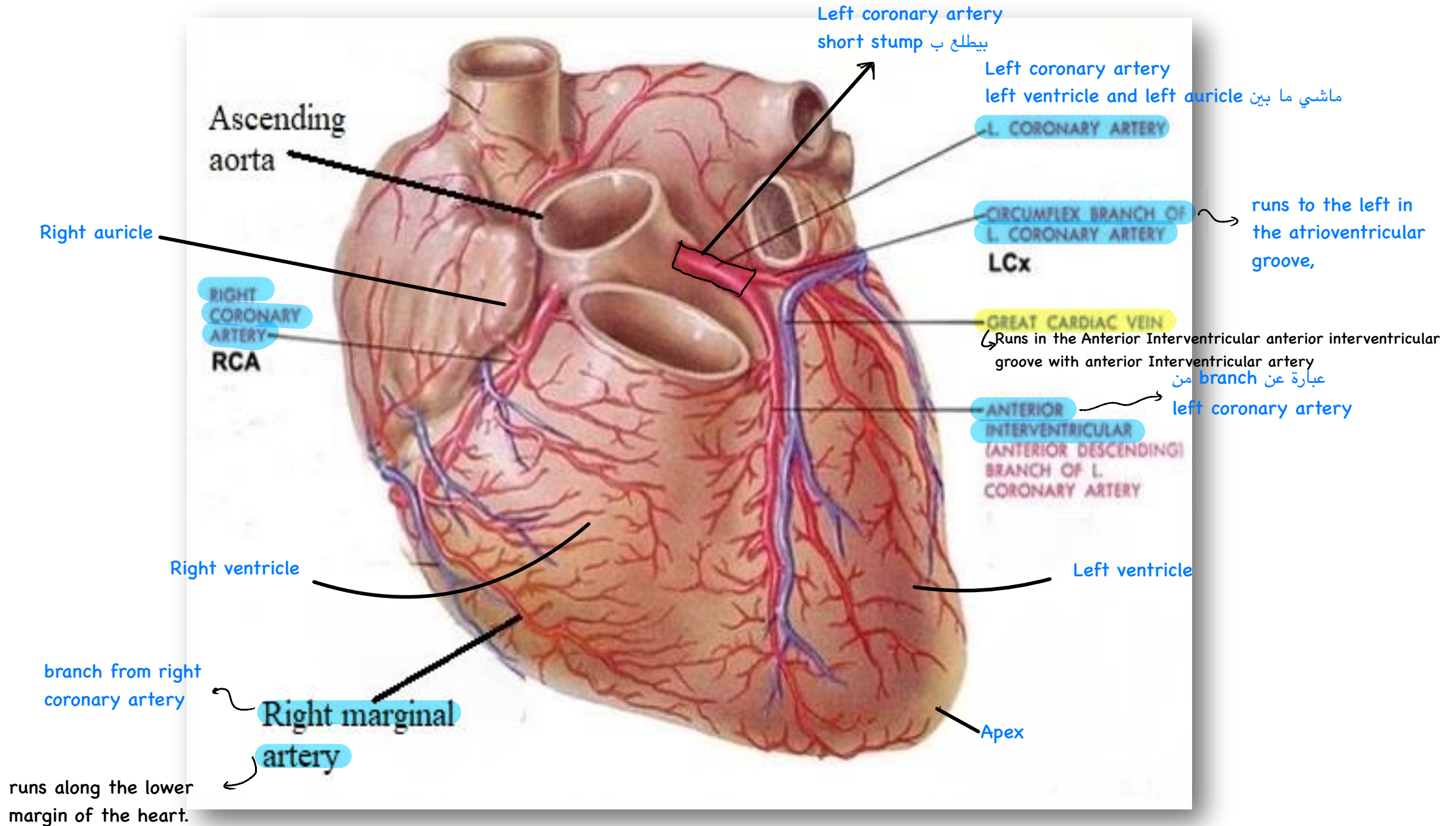
Circumflex artery



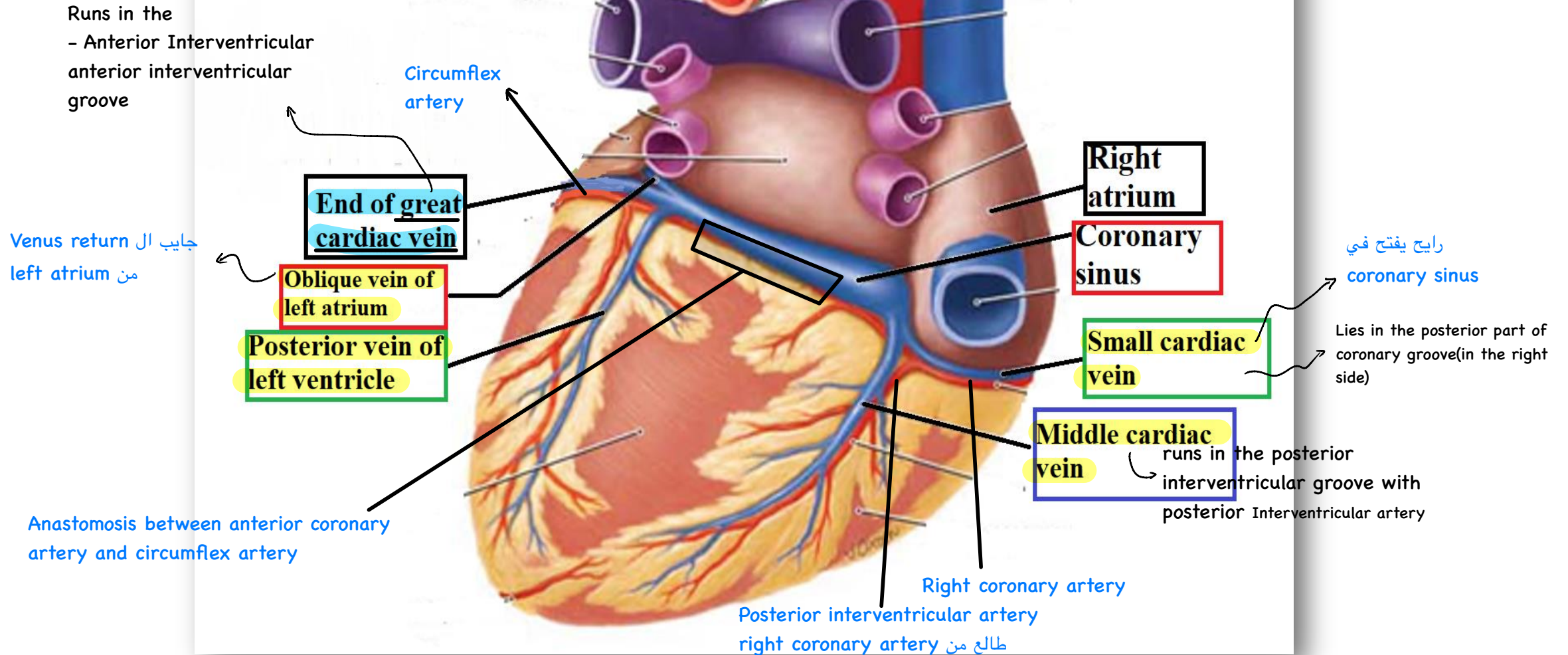
Coronary sinus

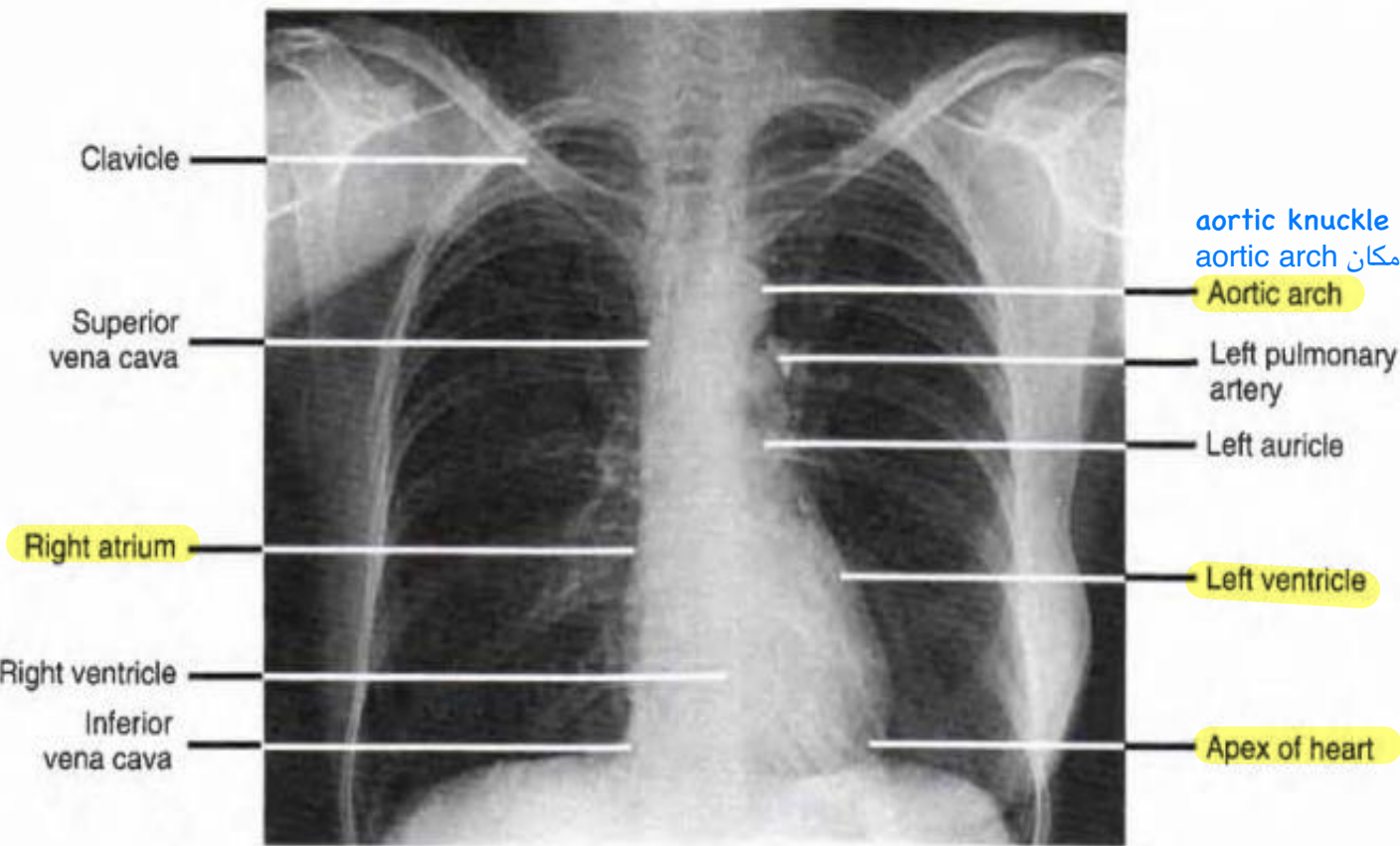
Right coronary artery

Posterior interventricular artery

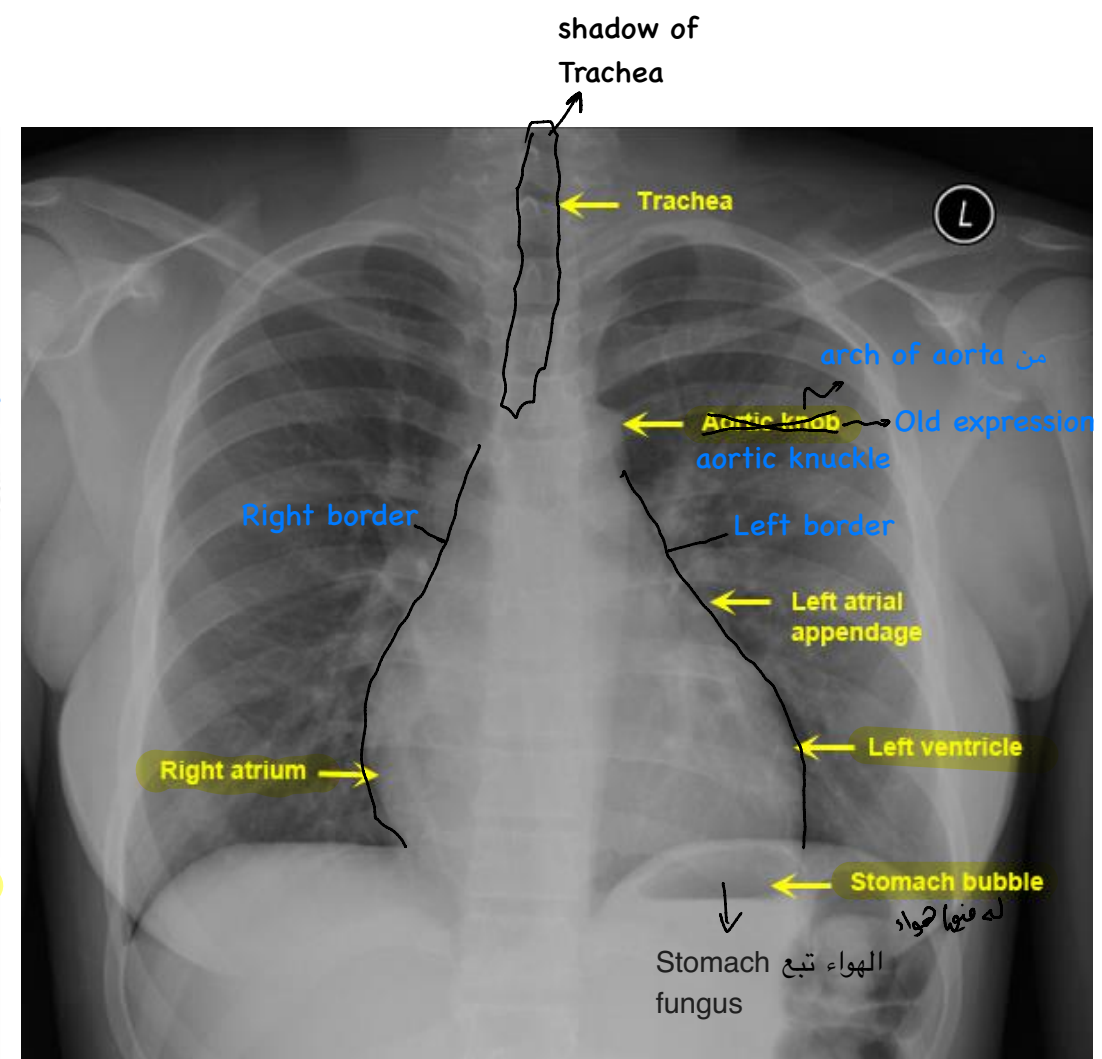


Coronary groove = coronary sulcus



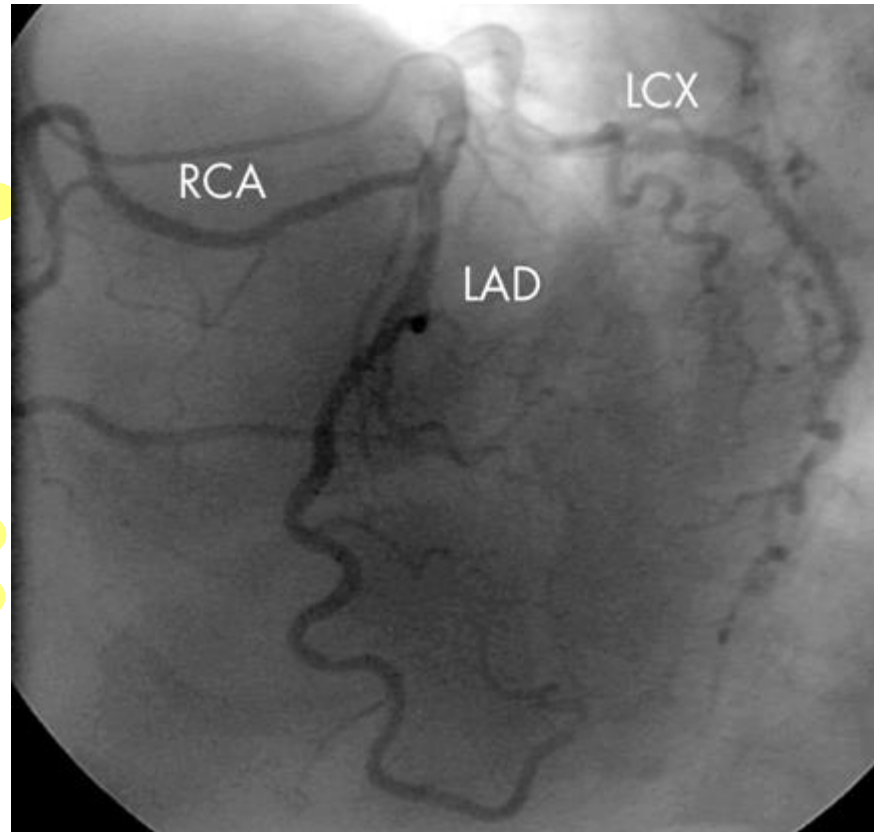


Posterior-anterior radiograph of the thorax showing the heart and great vessels.

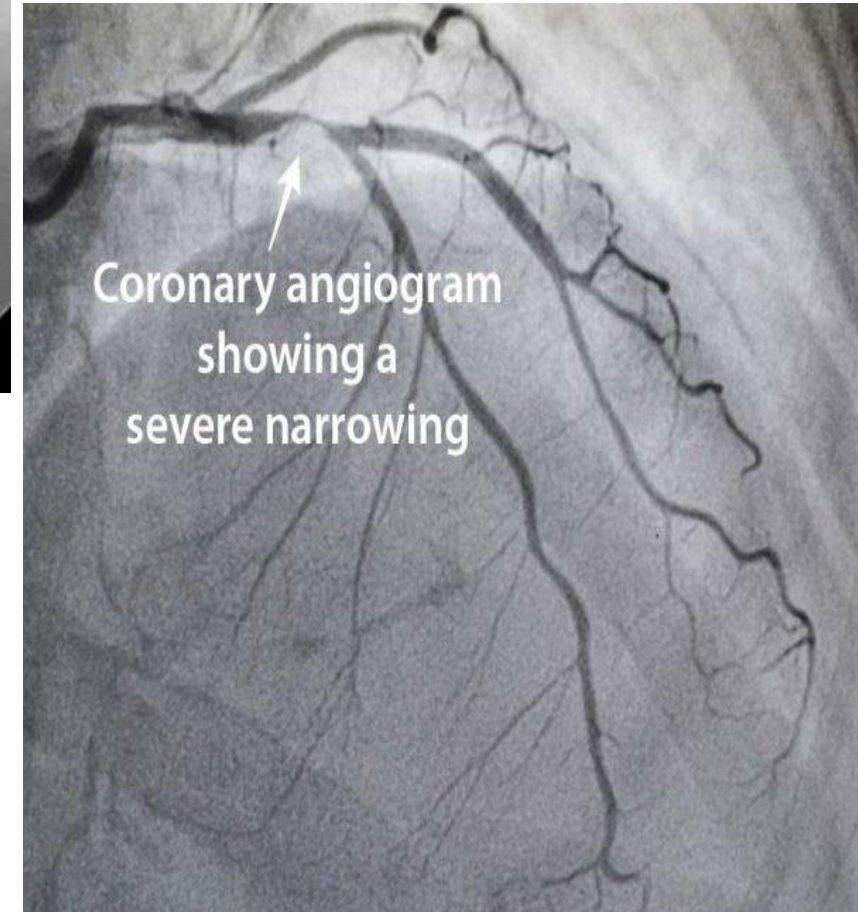


Coronary angiography is a procedure that uses a special dye (contrast material) and x-rays to see how blood flows through the arteries in your heart. Coronary angiography is performed to detect obstruction in the coronary arteries of the heart.

اذا فيه اي انسداد
بنحط دعامة



RCA; Right Coronary Artery
LCA; Left Circumflex Artery
LAD; Left anterior descending (anterior interventricular artery)



A photograph of a 'Thank you' card, a pen, and wrapped gifts on a marble surface. The card is white with the words 'Thank you' written in a purple cursive font. A black pen with a white grip is positioned vertically to the right of the card. In the background, there are two wrapped gifts: one with a red and white striped ribbon and another with a white and red patterned ribbon. To the left, there is a bouquet of small purple flowers with green foliage. The entire scene is set on a light-colored, veined marble surface.

Thank
you