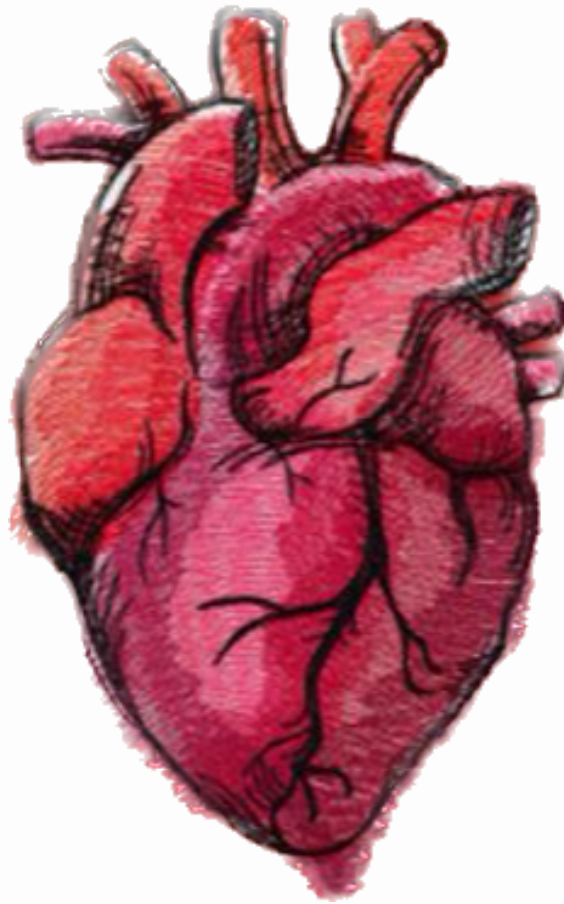




# CARDIOVASCULAR SYSTEM



SUBJECT : Physiology quiz

LEC NO. : 6

DONE BY : Mofeed Obeidat

وَقُلْ رَبِّ زِدْنِي عِلْمًا



**SCAN ME!**

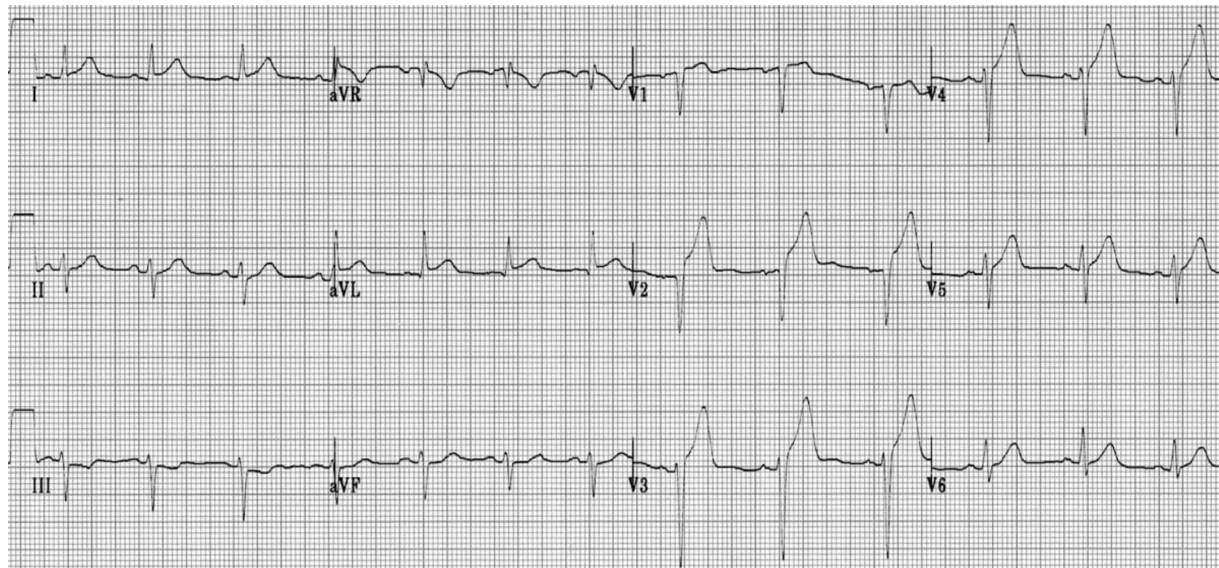
وَقُلْ رَبِّ زِدْنِي عِلْمًا



# GENITOURINARY SYSTEM



SCAN ME!



A 49-year-old non-smoking male with prior coronary stent implantation in LAD presented with acute chest pain. This is his initial ECG. Identify the findings and give a diagnosis:

- A. This is inferior MI with poor prognosis
- B. This is anteroseptal MI with poor prognosis
- C. This is a lateral MI with moderate prognosis
- D. This is an inferior MI with moderate prognosis

Ans: B

A patient is complaining of chest pain. You obtain a 12-lead ECG and see ST elevation in leads II, III, AVF. What area of the heart does this represent?

- A. Lateral
- B. Septal
- C. Anterior
- D. Inferior

Ans: D

وَقُلْ رَبِّ زِدْنِي عِلْمًا



## GENITOURINARY SYSTEM



SCAN ME!

Which of the following ECG changes are abnormal findings that may indicate ischemia or injury to the cardiac muscle found on a 12-lead ECG? SELECT-ALL-THAT-APPLY:

- A. Lengthening p-waves
- B. ST-segment elevation
- C. T-wave inversion
- D. Tall t-waves
- E. QT interval narrowing
- F. ST-segment depression

Ans : B,C,D,F

On an ECG, the lateral view of the heart is represented with leads A.

- V1, V2, V3
- B. II, III, AVF
- C. I, AVL, V5, V6
- D. V1, V2, V6

Ans:C

Which of the following blood tests is most indicative of cardiac damage?

- A.Lactate dehydrogenase
- B.Complete blood count (CBC)
- C.Troponin I
- D.Creatine kinase (CK)

Ans : C

وَقُلْ رَبِّ زِدْنِي عِلْمًا