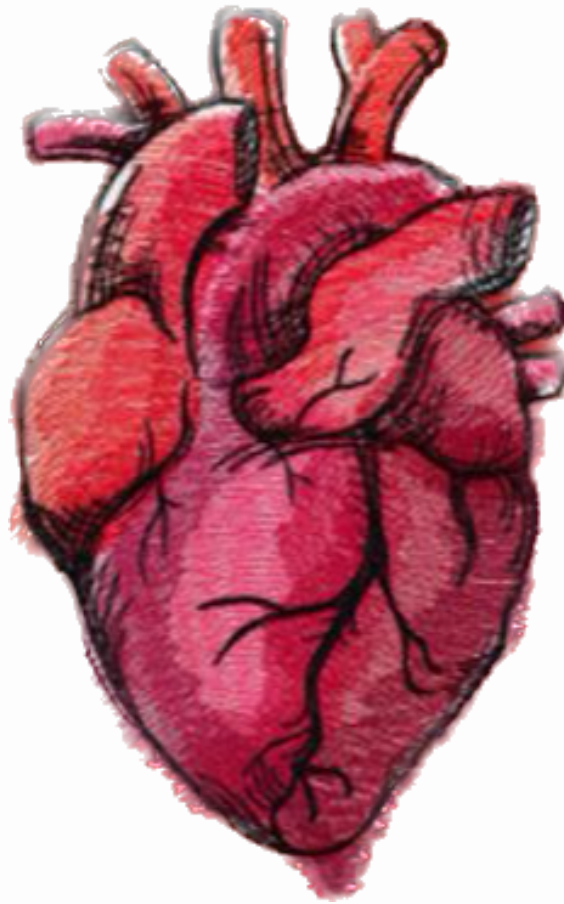




CARDIOVASCULAR SYSTEM



SUBJECT : Physiology quiz

LEC NO. : 5

DONE BY : Mofeed Obeidat

وَقُلْ رَبِّ زِدْنِي عِلْمًا



SCAN ME!

وَقُلْ رَبِّ زِدْنِي عِلْمًا

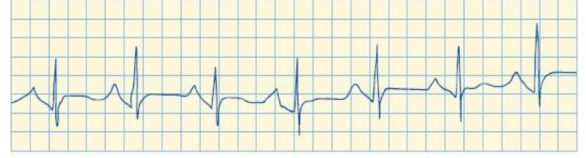


GENITOURINARY SYSTEM



SCAN ME!

1. The doctor has obtained this rhythm strip from her patient's monitor. Which description of this ECG is correct?



- A. Sinus tachycardia
- B. Sinus bradycardia
- C. Ventricular fibrillation
- D. Ventricular tachycardia

Ans:A

2. The patient has hypokalemia, and the doctor obtains the following measurements on the rhythm strip: Heart rate of 86 with a regular rhythm; the P wave is 0.06 seconds (sec) and normal shape; the PR interval is 0.24 sec; the QRS is 0.09 sec. How should the doctor document this rhythm?

- A. First-degree AV block
- B. Second-degree AV block
- C. Premature atrial contraction (PAC)
- D. Premature ventricular contraction (PVC)

Ans: A

3. Which ECG characteristic is consistent with a diagnosis of ventricular tachycardia (VT)?

- A. Unmeasurable rate and rhythm
- B. Rate 150 beats/min; inverted P wave
- C. Rate 200 beats/min; P wave not visible
- D. Rate 125 beats/min; normal QRS complex

Ans:C

وَقُلْ رَبِّ زِدْنِي عِلْمًا



GENITOURINARY SYSTEM



SCAN ME!

4. The doctor is watching the cardiac monitor, and a patient's rhythm suddenly changes. There are no P waves. Instead there are fine, wavy lines between the QRS complexes. The QRS complexes measure 0.08 sec (narrow), but they occur irregularly with a rate of 120 beats/ min. The doctor correctly interprets this rhythm as what?
- A. Sinus tachycardia
 - B. Atrial fibrillation
 - C. Ventricular fibrillation
 - D. Ventricular tachycardia

Ans: B

5. For which dysrhythmia is defibrillation primarily indicated?
- A. Ventricular fibrillation
 - B. Third-degree AV block
 - C. Uncontrolled atrial fibrillation
 - D. Ventricular tachycardia with a pulse

Ans: A

6. P wave of ECG is absent in?
- A. Atrial hypertrophy.
 - B. Ventricular extrasystole.
 - C. Heart failure.
 - D. Supraventricular tachycardia.
 - E. First degree heart block.

Ans: D

وَقُلْ رَبِّ زِدْنِي عِلْمًا